Natural Resources for Human Health
eISSN: 2583-1194

Original Research

Received 02 May 2025
Revised 10 May 2025
Accepted 29 June 2025

Natural Resources for Human Health 2025, Vol.5(4): 822–833

KEYWORDS:
Calretinin, cytokeratin-19, odontogenic cysts, odontogenic keratocyst, ameloblastoma, immunohistochemistry.

Expression of Calretinin and Cytokeratin-19 in Odontogenic Cysts and Ameloblastoma: An Immunohistochemical Study

Naresh Gehlot[1*], Minha Majeed Kak[2], Suheel H. Latoo[3], Mohd. Shafi Dar[4]

[1] Postgraduate Scholar, Postgraduate Department of Oral & Maxillofacial Pathology and Microbiology, Government Dental College & Hospital, Srinagar, Kashmir, India
[2] Senior Resident, Postgraduate Department of Oral & Maxillofacial Pathology and Microbiology, Government Dental College & Hospital, Srinagar, Kashmir, India
[3] Professor and Head, Postgraduate Department of Oral & Maxillofacial Pathology and Microbiology, Government Dental College & Hospital, Srinagar, Kashmir, India
[4] Associate Professor, Postgraduate Department of Oral & Maxillofacial Pathology and Microbiology, Government Dental College & Hospital, Srinagar, Kashmir, India.
Corresponding author: Dr Naresh Gehlot, Postgraduate Scholar, Postgraduate Department of Oral & Maxillofacial Pathology and Microbiology, Government Dental College & Hospital, Srinagar, Kashmir, India.
Email ID: Nghelot@gmail.com

ABSTRACT:

Background: Odontogenic cysts and ameloblastoma may share overlapping clinical, radiographic, and histopathological features. Calretinin has been proposed as a marker of ameloblastic differentiation, whereas cytokeratin-19 (CK-19) is expressed in odontogenic epithelium.

Aim: To evaluate and compare the immunohistochemical expression of calretinin and CK-19 in dentigerous cyst, radicular cyst, odontogenic keratocyst (OKC), and ameloblastoma.

Materials and methods: This retrospective immunohistochemical study included 44 archival formalin-fixed, paraffin-embedded specimens: 11 each of dentigerous cyst, radicular cyst, OKC, and ameloblastoma. Sections were stained for calretinin and CK-19. Staining localization, tissue distribution, percentage of positive cells, and intensity were assessed. Percentage and intensity scores were added to obtain a final immunoreactive score (IRS; range 0–6).

Results: Calretinin demonstrated prominent, widespread positivity in ameloblastoma, particularly in stellate reticulum-like cells. In contrast, odontogenic cysts showed absent or limited/focal staining, often restricted to the basal cell layer. Moderate-to-strong calretinin IRS was observed in 8 of 11 ameloblastomas, compared with 4 of 11 dentigerous cysts, 1 of 11 radicular cysts, and 5 of 11 odontogenic keratocysts. The distribution of final calretinin scores differed significantly among the four lesion groups (χ^2=15.63; p=0.04). CK-19 expression was detected in all lesion types and was generally moderate to strong in the odontogenic cysts, with the highest mean IRS in ameloblastoma. However, the distribution of final CK-19 scores did not differ significantly among the four groups (χ^2=9.74; p=0.37), supporting its broad expression across odontogenic epithelium rather than a lesion-specific pattern. Mean CK-19 IRS exceeded mean calretinin IRS in all groups.

Natural Resources for Human Health
eISSN: 2583-1194

Conclusion: Calretinin showed a stronger association with ameloblastoma than with the cystic lesions, while CK-19 was broadly expressed across odontogenic lesions. The markers may provide complementary information when interpreted with routine histopathology; neither should be used in isolation.

INTRODUCTION

Odontogenic cysts are epithelial-lined lesions of the jaws that arise from odontogenic epithelial remnants. Radicular cyst, dentigerous cyst, and odontogenic keratocyst (OKC) are among the principal types encountered in oral pathology. Their clinical and radiographic appearances may overlap, and histopathological interpretation can be challenging in small or altered specimens [1,2]. Several mechanisms have been proposed for cyst initiation and enlargement, reflecting the diverse biological behaviour of these lesions [3,4].

Ameloblastoma is an odontogenic epithelial neoplasm with locally invasive growth and a recognised tendency to recur. Unicystic ameloblastoma may closely resemble an odontogenic cyst clinically and radiographically; therefore, careful examination of the epithelial lining and mural components is essential. The current World Health Organization classification provides the contemporary framework for categorising odontogenic and maxillofacial bone tumours [5].

Calretinin is a calcium-binding protein belonging to the EF-hand family. Its immunohistochemical expression has been reported in ameloblastic epithelium, particularly in cells resembling the stellate reticulum, and has been investigated as an adjunct in distinguishing ameloblastoma from odontogenic cysts [6,7]. Subsequent studies have also explored its diagnostic utility, although staining in non-neoplastic odontogenic cysts and OKC has varied between reports [8,9].

Cytokeratin-19 (CK-19) is a low-molecular-weight type I intermediate-filament protein expressed in several simple and non-keratinising epithelial tissues, including odontogenic epithelium. Its expression has been demonstrated in epithelial odontogenic tumours and cystic lesions, but its broad distribution may limit its ability to distinguish individual lesion types when used alone [10,11].

Because calretinin and CK-19 may reflect different aspects of odontogenic epithelial phenotype, their comparative assessment may provide complementary information in selected diagnostically challenging cases. The present study therefore evaluated and compared the immunohistochemical expression of calretinin and CK-19 in dentigerous cyst, radicular cyst, OKC, and ameloblastoma.

Aim and objectives

The aim was to evaluate the immunohistochemical expression of calretinin and cytokeratin-19 in odontogenic cysts and ameloblastoma.

- To compare calretinin expression in dentigerous cyst, radicular cyst, OKC, and ameloblastoma.
- To compare CK-19 expression in the same lesion groups.
- To compare the expression scores of calretinin and CK-19 within each lesion group.

MATERIALS AND METHODS

Study design and setting. A retrospective immunohistochemical analysis was performed on archival tissue specimens retrieved from the Postgraduate Department of Oral and Maxillofacial Pathology and Microbiology, Government Dental College and Hospital, Srinagar, India. The study included 44 formalin-fixed, paraffin-embedded specimens, comprising 11 cases each of dentigerous cyst, radicular cyst, OKC, and ameloblastoma. All diagnoses were reviewed and confirmed on haematoxylin and eosin (H&E)-stained sections.

Selection criteria. Included cases were histopathologically confirmed dentigerous cyst, radicular cyst, OKC, and ameloblastoma, including variants. Sections without sufficient epithelial lining, inadequate tissue samples, syndromic cases, and hybrid lesions were excluded.

Immunohistochemistry. Two sections, each 4 μm thick, were prepared from each paraffin block, with one section allocated to calretinin and the other to CK-19. Sections were mounted on charged slides, deparaffinized in two to three changes of

xylene, rehydrated through descending alcohol grades, and rinsed in distilled water. Antigen retrieval was performed in citrate buffer using an autoclave at 15 lb pressure for 15 minutes. After cooling, slides were washed in PBS (pH 7.2). Endogenous peroxidase was blocked with 3% hydrogen peroxide for 10 minutes, followed by protein blocking reagent for 10 minutes. Rabbit polyclonal anti-calretinin antibody was incubated overnight at room temperature; mouse monoclonal anti-human CK-19 antibody was incubated for 2 hours at room temperature. A secondary antibody enhancer and streptavidin solution were applied for 20 minutes using a polymer detection system. DAB was used for visualization, followed by Mayer's haematoxylin counterstaining, dehydration, xylene clearing, and DPX mounting.

Controls. Normal brain tissue was used as the positive control for calretinin and breast carcinoma tissue for CK-19. Negative controls were prepared by omitting the primary antibody.

Evaluation and scoring. Stained sections were evaluated under a light microscope at ×200 magnification. Five randomly selected microscopic fields were examined per specimen. Percentage positivity was scored as 0 (<25%), 1 (25–50%), 2 (50–75%), or 3 (>75%). Intensity was scored as 0 (none), 1 (mild), 2 (moderate), or 3 (intense). The percentage and intensity scores were added (P+I; range 0–6). IRS was categorized as absent (0), weak (1–2), moderate (3–4), or strong (5–6). Tissue distribution was recorded as negative, focal (<50%), or diffuse (≥50%). Staining localization was categorized by epithelial layer involvement. Two independent observers evaluated the stained sections.

Statistical analysis. Data were compiled using Microsoft Excel and analysed with SPSS version 20.0. Categorical variables were summarized as frequencies and percentages, and continuous variables as mean ± standard deviation. Chi-square or Fisher's exact testing was specified for categorical comparisons, and independent t-test or Mann–Whitney U-test for continuous comparisons, as appropriate. A two-sided p-value <0.05 was considered statistically significant.

RESULTS

A total of 44 cases were evaluated, with 11 specimens in each of the four diagnostic groups. The reported distributions for tissue localization, staining pattern, percentage positivity, intensity, and final IRS are summarized in Tables 1–10.

Table 1. Calretinin tissue distribution, $\chi^2=9.44$; p=0.15

Expression category	Dentigerous	Radicular	OKC	Ameloblastoma
Negative	3 (27.3%)	2 (18.2%)	2 (18.2%)	2 (18.2%)
Diffuse	3 (27.3%)	2 (18.2%)	4 (36.4%)	8 (72.7%)
Focal	5 (45.5%)	7 (63.6%)	5 (45.5%)	1 (9.1%)

Table 2. Calretinin staining pattern,$\chi^2=22.41$; p=0.21

Expression category	Dentigerous	Radicular	OKC	Ameloblastoma
Negative	3 (27.3%)	2 (18.2%)	2 (18.2%)	2 (18.2%)
Basal layer (B)	0 (0.0%)	2 (18.2%)	1 (9.1%)	0 (0.0%)
Surface layer (Su)	3 (27.3%)	3 (27.3%)	3 (27.3%)	1 (9.1%)
Su + B	3 (27.3%)	4 (36.4%)	0 (0.0%)	6 (54.5%)
Su + spinous (Sp)	0 (0.0%)	0 (0.0%)	3 (27.3%)	1 (9.1%)
Su + Sp + B	2 (18.2%)	0 (0.0%)	2 (18.2%)	1 (9.1%)

Table 3. Percentage score for calretinin,χ^2=17.42; p=0.04

Expression category	Dentigerous	Radicular	OKC	Ameloblastoma
Score 0	3 (27.3%)	4 (36.4%)	2 (18.2%)	2 (18.2%)
Score 1	5 (45.5%)	7 (63.6%)	5 (45.5%)	1 (9.1%)
Score 2	3 (27.3%)	0 (0.0%)	3 (27.3%)	4 (36.4%)
Score 3	0 (0.0%)	0 (0.0%)	1 (9.1%)	4 (36.4%)

Table 4. Calretinin staining intensity, χ^2=15.10; p=0.08

Expression category	Dentigerous	Radicular	OKC	Ameloblastoma
No staining	3 (27.3%)	4 (36.4%)	2 (18.2%)	2 (18.2%)
Mild	5 (45.5%)	6 (54.5%)	4 (36.4%)	1 (9.1%)
Moderate	3 (27.3%)	1 (9.1%)	4 (36.4%)	4 (36.4%)
Intense	0 (0.0%)	0 (0.0%)	1 (9.1%)	4 (36.4%)

Table 5. Final calretinin immunoreactive score,χ^2=15.63; p=0.04

Expression category	Dentigerous	Radicular	OKC	Ameloblastoma
Absent	3 (27.3%)	4 (36.4%)	2 (18.2%)	2 (18.2%)
Weak	4 (36.4%)	6 (54.5%)	4 (36.4%)	1 (9.1%)
Moderate	4 (36.4%)	1 (9.1%)	4 (36.4%)	4 (36.4%)
Strong	0 (0.0%)	0 (0.0%)	1 (9.1%)	4 (36.4%)

Table 6. CK-19 tissue distribution, χ^2=8.21; p=0.21

Expression category	Dentigerous	Radicular	OKC	Ameloblastoma
Negative	1 (9.1%)	0 (0.0%)	0 (0.0%)	1 (9.1%)
Diffuse	8 (72.7%)	5 (45.5%)	6 (54.5%)	9 (81.8%)
Focal	2 (18.2%)	6 (54.5%)	5 (45.5%)	1 (9.1%)

Natural Resources for Human Health
eISSN: 2583-1194

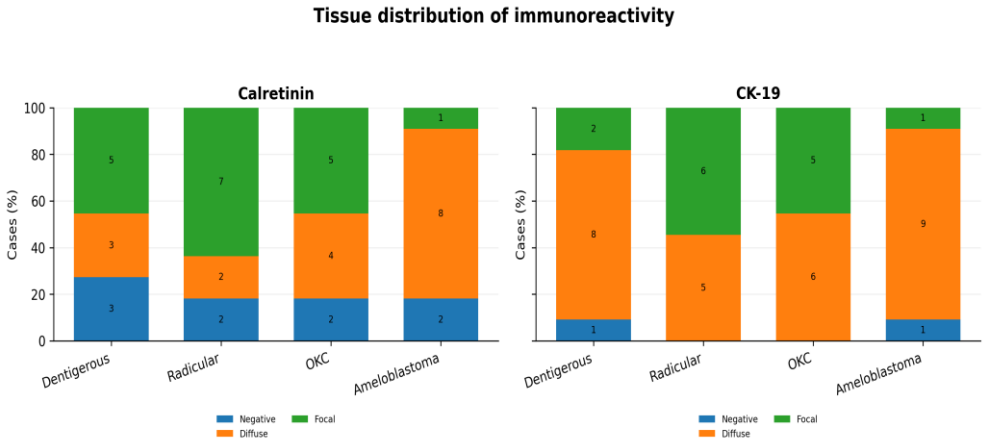

Graph 1. Tissue distribution of calretinin and CK-19 across the four lesion groups.

Table 7. CK-19 staining pattern, χ^2=38.88; p=0.01

Expression category	Dentigerous	Radicular	OKC	Ameloblastoma
Negative	1 (9.1%)	0 (0.0%)	0 (0.0%)	1 (9.1%)
Basal layer (B)	0 (0.0%)	3 (27.3%)	1 (9.1%)	0 (0.0%)
Surface layer (Su)	1 (9.1%)	0 (0.0%)	1 (9.1%)	0 (0.0%)
Su + B	2 (18.2%)	0 (0.0%)	4 (36.4%)	2 (18.2%)
Su + spinous (Sp)	1 (9.1%)	6 (54.5%)	0 (0.0%)	1 (9.1%)
Sp + B	0 (0.0%)	0 (0.0%)	3 (27.3%)	0 (0.0%)
Su + Sp + B	6 (54.5%)	2 (18.2%)	2 (18.2%)	7 (63.6%)

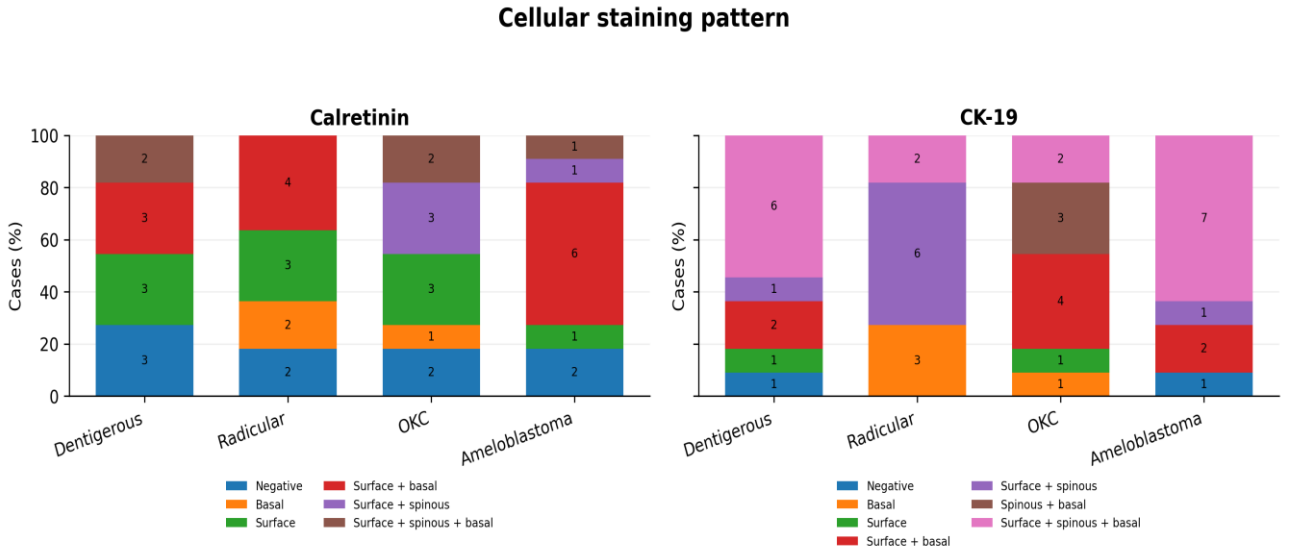

Graph 2. Cellular staining patterns of calretinin and CK-19 across the four lesion groups.

Table 8. Percentage score for CK-19, χ^2=19.27; p=0.02

Expression category	Dentigerous	Radicular	OKC	Ameloblastoma
Score 0	1 (9.1%)	0 (0.0%)	0 (0.0%)	1 (9.1%)
Score 1	0 (0.0%)	3 (27.3%)	5 (45.5%)	0 (0.0%)
Score 2	9 (81.8%)	6 (54.5%)	4 (36.4%)	4 (36.4%)
Score 3	1 (9.1%)	2 (18.2%)	2 (18.2%)	6 (54.5%)

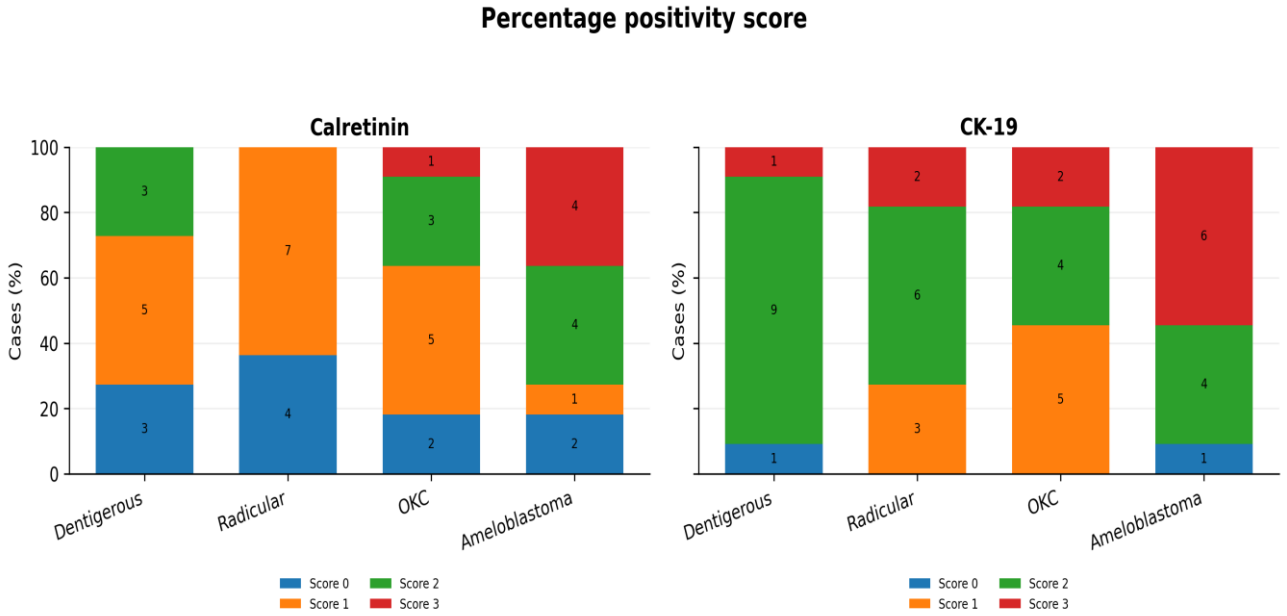

Graph 3. Distribution of percentage positivity scores for calretinin and CK-19.

Table 9. CK-19 staining intensity,χ^2=14.93; p=0.08

Expression category	Dentigerous	Radicular	OKC	Ameloblastoma
No staining	1 (9.1%)	0 (0.0%)	0 (0.0%)	1 (9.1%)
Mild	0 (0.0%)	4 (36.4%)	3 (27.3%)	0 (0.0%)
Moderate	8 (72.7%)	6 (54.5%)	7 (63.6%)	5 (45.5%)
Intense	2 (18.2%)	1 (9.1%)	1 (9.1%)	5 (45.5%)

Natural Resources for Human Health
eISSN: 2583-1194

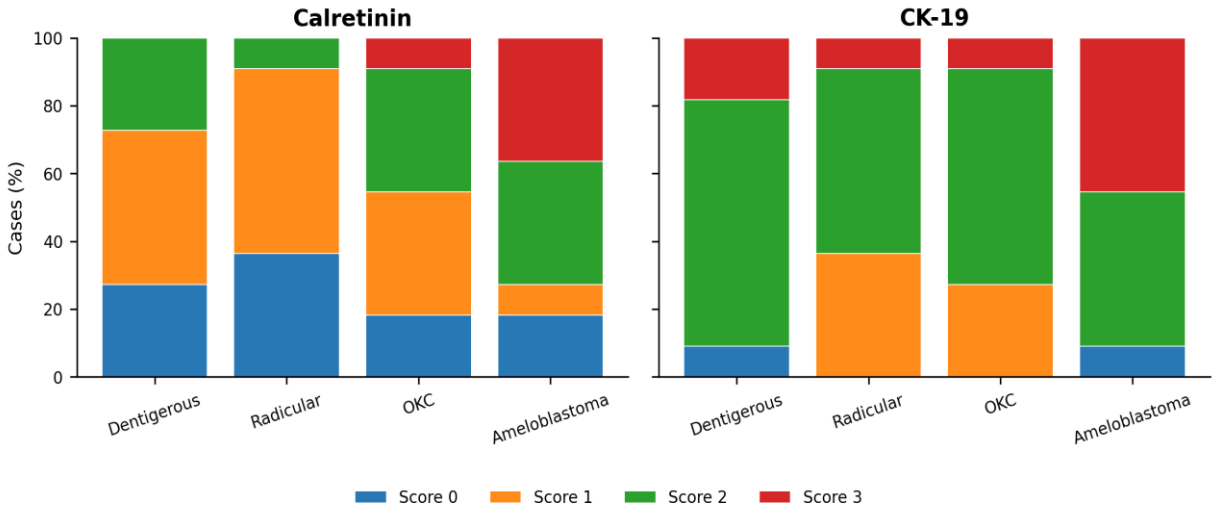

Graph 4. Comparative distribution of calretinin and CK-19 staining intensity scores across the four lesion groups.

Table 10. Final CK-19 immunoreactive score, χ^2=9.74; p=0.37

Expression category	Dentigerous	Radicular	OKC	Ameloblastoma
Absent	1 (9.1%)	0 (0.0%)	0 (0.0%)	1 (9.1%)
Weak	0 (0.0%)	3 (27.3%)	3 (27.3%)	0 (0.0%)
Moderate	7 (63.6%)	6 (54.5%)	6 (54.5%)	4 (36.4%)
Strong	3 (27.3%)	2 (18.2%)	2 (18.2%)	6 (54.5%)

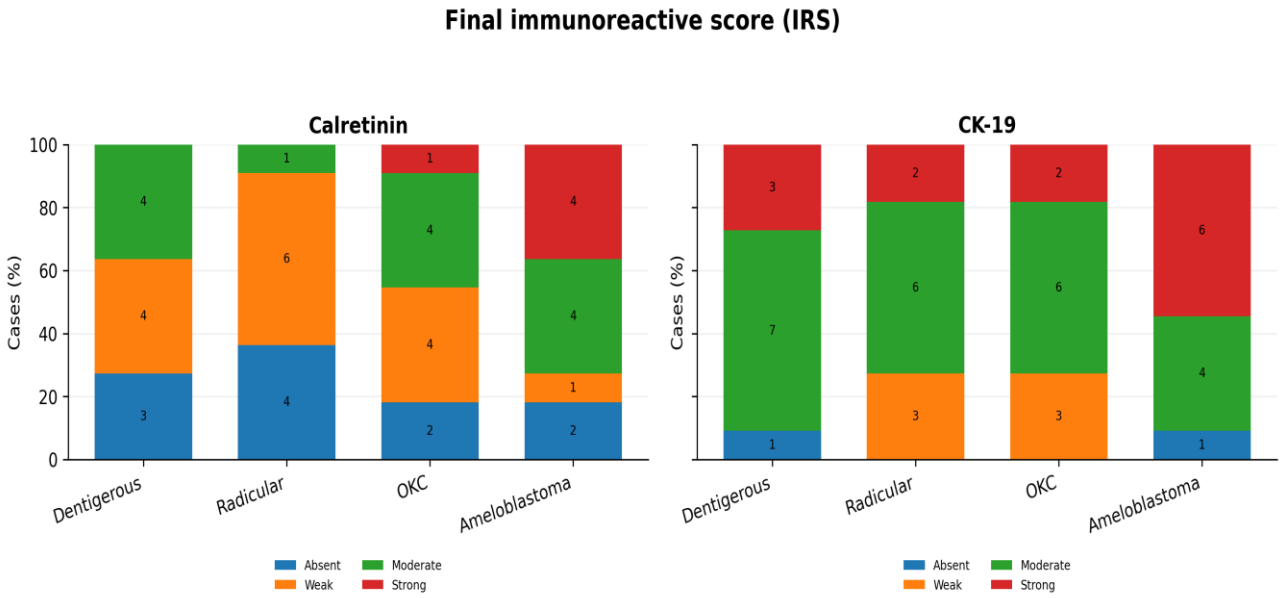

Graph 5. Distribution of final immunoreactive scores for calretinin and CK-19.

Comparison of mean IRS between calretinin and CK-19

Table 11. Comparison of mean final immunoreactive scores between calretinin and CK-19.

Lesion	Calretinin mean ± SD	CK-19 mean ± SD	p-value
Dentigerous cyst	2.18 ± 1.32	3.82 ± 1.11	0.003
Radicular cyst	1.91 ± 1.27	3.55 ± 1.09	0.005
Odontogenic keratocyst	2.64 ± 1.41	3.73 ± 1.25	0.041
Ameloblastoma	3.91 ± 1.52	4.55 ± 1.36	0.118

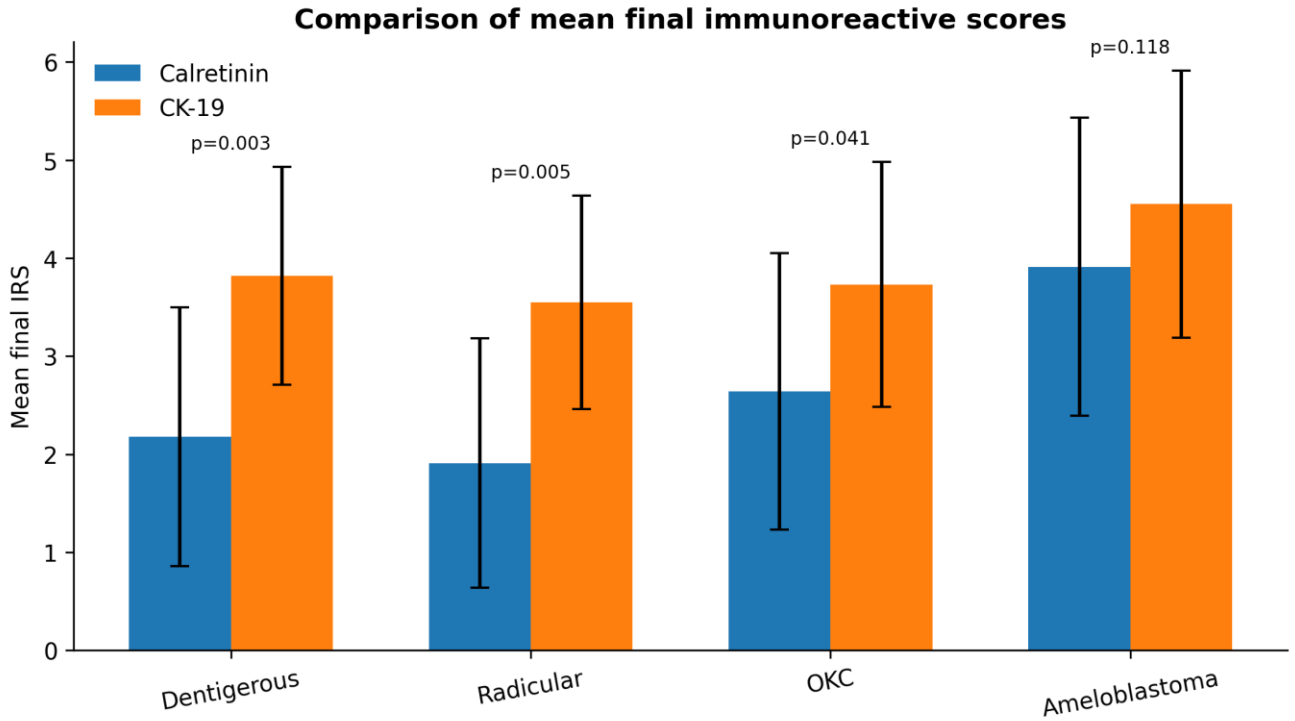

Graph 6. Comparison of mean final IRS for calretinin and CK-19 across the four lesion groups.

Representative photomicrographs

Representative H&E and immunohistochemical photomicrographs of the four lesion groups are presented below at ×20 magnification, with individual descriptions beneath each image.

Dentigerous cyst: H&E, calretinin, and CK-19.

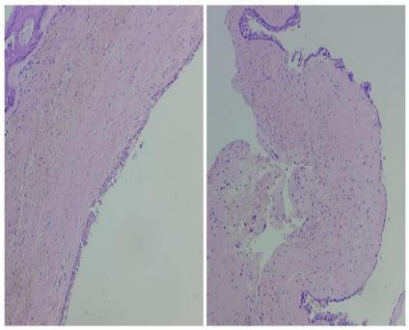

H&E-stained section showing the epithelial lining of a dentigerous cyst (×20).

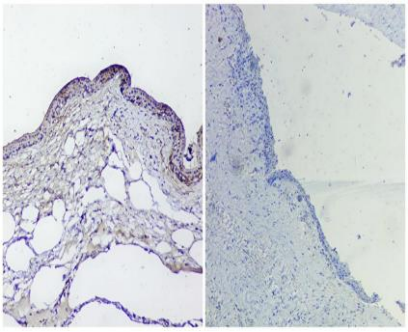

Calretinin immunostaining showing focal weak-to-negative expression in the epithelial lining (×20).

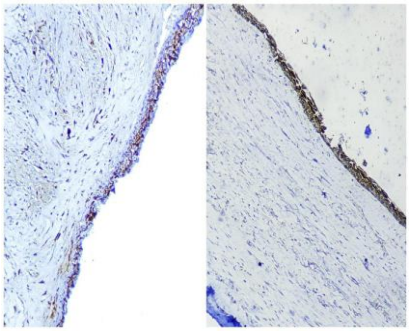

CK-19 immunostaining showing diffuse moderate-to-strong expression in the epithelial lining (×20).

Radicular cyst: H&E, calretinin, and CK-19.

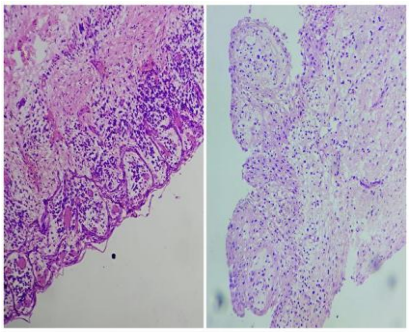

H&E-stained section showing the epithelial lining of a radicular cyst (×20).

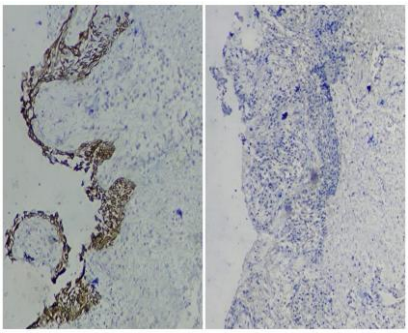

Calretinin immunostaining showing focal expression with areas of moderate and negative staining (×20).

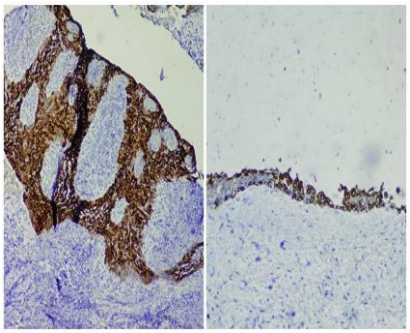

CK-19 immunostaining showing diffuse expression with variable strong and weak staining (×20).

Odontogenic keratocyst: H&E, calretinin, and CK-19.

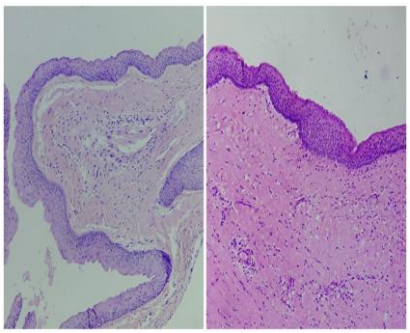

H&E-stained section showing the characteristic epithelial lining of an odontogenic keratocyst (×20).

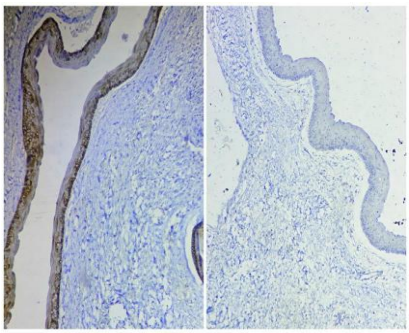

Calretinin immunostaining showing focal expression with moderate and negative staining areas (×20).

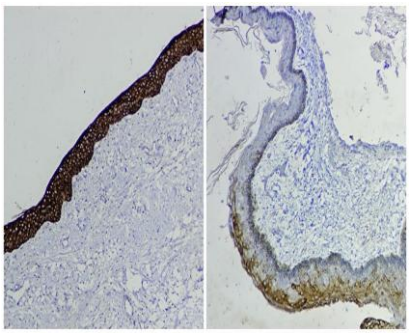

CK-19 immunostaining showing diffuse expression with strong and moderate staining (×20).

Ameloblastoma: H&E, calretinin, and CK-19.

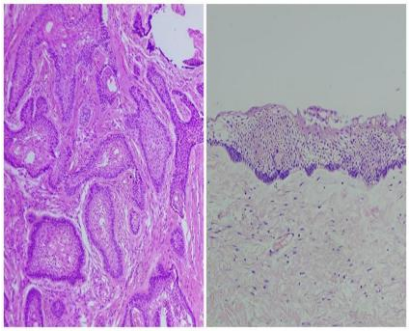

H&E-stained section showing the characteristic histopathological features of ameloblastoma (×20).

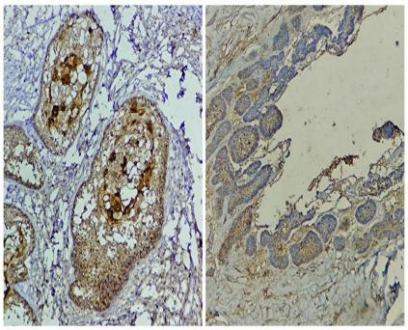

Calretinin immunostaining showing diffuse moderate-to-strong expression predominantly in the central stellate reticulum-like cells (×20).

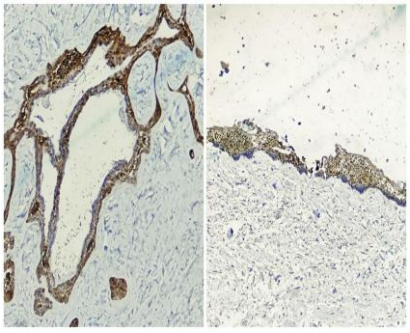

CK-19 immunostaining showing diffuse moderate-to-strong expression predominantly in the peripheral tumour cells (×20).

DISCUSSION

The present study compared calretinin and CK-19 immunoreactivity in 44 archival specimens representing three odontogenic cysts and ameloblastoma. The principal finding was the different expression profiles of the two markers: calretinin showed a greater proportion of moderate-to-strong immunoreactivity in ameloblastoma, whereas CK-19 was expressed across all four lesion groups and did not show a statistically significant association between final IRS category and lesion type.

Calretinin tissue distribution was predominantly diffuse in ameloblastoma (8/11; 72.7%), while focal staining predominated in dentigerous and radicular cysts. Nevertheless, the overall association between tissue distribution and lesion type was not statistically significant ($p=0.15$), and the staining-pattern association was also not significant ($p=0.21$). The percentage score and final IRS did show statistically significant associations with lesion type ($p=0.04$ for each), whereas staining intensity alone did not ($p=0.08$). This suggests that the combined percentage and intensity assessment may capture group differences that are not apparent from distribution or intensity considered separately.

The stronger calretinin immunoreactivity observed in ameloblastoma is consistent with reports describing its expression in ameloblastic epithelium. Altini et al. identified calretinin expression in ameloblastomas, particularly in stellate-reticulum-like cells [6]. Subsequent studies have explored its usefulness as an adjunct in distinguishing ameloblastoma from odontogenic cysts [7,8]. However, calretinin positivity was not confined to ameloblastoma in the present series; some dentigerous cyst, radicular cyst, and OKC specimens also showed immunoreactivity. Similar variability has been reported in studies examining odontogenic cysts and tumours [9,17]. These findings indicate that calretinin may support, but cannot independently establish, a diagnosis of ameloblastoma.

In the present study, CK-19 was broadly expressed. Diffuse staining was frequent in dentigerous cyst (8/11), OKC (6/11), and ameloblastoma (9/11), while radicular cyst showed a greater proportion of focal staining (6/11). CK-19 staining localization differed across groups (reported $p=0.01$), and percentage score also differed ($p=0.02$), but the final IRS distribution did not ($p=0.37$). Thus, although the topographic distribution and proportion of positive cells varied, the overall intensity-plus-percentage IRS categories overlapped among lesion types. This pattern is consistent with the established expression of CK-19 in odontogenic epithelium. Previous investigations have documented CK-19 immunoreactivity in epithelial odontogenic tumours [10,11]. Other studies have described its expression in odontogenic cysts, including dentigerous cyst and OKC [9,22].

Comparison of mean IRS showed higher CK-19 values than calretinin in all four groups. The reported between-marker differences were statistically significant in dentigerous cyst, radicular cyst, and OKC, but not in ameloblastoma. These results suggest that CK-19 may be more consistently expressed in cystic odontogenic epithelium, whereas calretinin may contribute more to recognizing ameloblastic differentiation when the lesion has compatible histomorphology. Comparative studies have

also reported CK-19 expression in odontogenic lesions [9,10]. Calretinin has been investigated as an adjunctive marker in the differential diagnosis of ameloblastoma [7,8].

LIMITATIONS

This was a retrospective study with a modest sample size of 11 cases per diagnostic group. The findings are based on archival material and semi-quantitative immunohistochemical scoring.

CONCLUSION

Calretinin showed comparatively stronger immunoreactivity in ameloblastoma than in the odontogenic cyst groups, particularly when percentage positivity and the final IRS were considered. CK-19 was expressed across all studied lesions and showed overlapping final IRS distributions, supporting its role as a marker of odontogenic epithelial differentiation rather than a lesion-specific discriminator. Used together with routine histopathology, calretinin and CK-19 may provide complementary diagnostic information; however, neither marker should be used independently to establish a diagnosis.

DECLARATIONS

Ethics approval: The study protocol entitled "Expression of Calretinin & Cytokeratin-19 in Odontogenic Cysts & Ameloblastoma – An Immunohistochemical Study" was reviewed by the Institutional Ethical Committee, Government Dental College & Hospital, Srinagar. The approval letter records the committee meeting date as 28 June 2024 and the letter date as 31 July 2024 (Reference No. UDC/Perio/eth Committee/1773, dated 31 July 2024).

Acknowledgment: The authors acknowledge Government Dental College and Hospital, Srinagar, Jammu & Kashmir – 190010.

Financial support and sponsorship: Nil.

Conflicts of interest: There are no conflicts of interest.

Data availability: The data supporting this study are available from the corresponding author subject to institutional permissions.

REFERENCES

[1] Kramer IRH. Changing views on oral disease. Proc R Soc Med. 1974;67(4):271-6. doi:10.1177/003591577406700414.
[2] Shear M, Speight PM. Cysts of the oral and maxillofacial regions. 4th ed. Oxford: Blackwell Munksgaard; 2007.
[3] Regezi JA, Sciubba JJ, Jordan RCK. Oral pathology: clinical pathologic correlations. 7th ed. St Louis: Elsevier; 2017.
[4] Browne RM. The pathogenesis of odontogenic cysts: a review. J Oral Pathol. 1975;4(1):31-46. doi:10.1111/j.1600-0714.1975.tb01738.x.
[5] Vered M, Wright JM. Update from the 5th Edition of the World Health Organization Classification of Head and Neck Tumours: odontogenic and maxillofacial bone tumours. Head Neck Pathol. 2022;16(1):63-75. doi:10.1007/s12105-021-01404-7.
[6] Altini M, Coleman H, Doglioni C, Favia G, Maiorano E. Calretinin expression in ameloblastomas. Histopathology. 2000;37(1):27-32. doi:10.1046/j.1365-2559.2000.00940.x.
[7] D'Silva S, Sumathi MK, Balaji N, Shetty NKN, Pramod KM, Cheeramelil J. Evaluation of calretinin expression in ameloblastoma and non-neoplastic odontogenic cysts: an immunohistochemical study. J Int Oral Health. 2013;5(6):42-8.
[8] Anandani C, Metgud R, Singh K. Calretinin as a diagnostic adjunct for ameloblastoma. Patholog Res Int. 2014;2014:308240. doi:10.1155/2014/308240.
[9] Pawar VM, Patel S, Pathak J, Swain N, Hosalkar R, Iyer J. Immunohistochemical evaluation of calretinin and cytokeratin-19 in odontogenic keratocyst and ameloblastoma: a retrospective study. J Contemp Dent. 2015;5(2):98-103. doi:10.5005/jp-journals-10031-1116.
[10] Kumamoto H, Yoshida M, Ooya K. Immunohistochemical detection of amelogenin and cytokeratin 19 in epithelial odontogenic tumors. Oral Dis. 2001;7(3):171-6. doi:10.1034/j.1601-0825.2001.70306.x.
[11] Akhila CNV, Sreenath G, Prakash AR, Rajini Kanth M, Reddy AVS, Kumar SN. Expression of stem cell marker cytokeratin 19 in reduced enamel epithelium, dentigerous cyst and unicystic ameloblastoma: a comparative analysis. J Oral Maxillofac Pathol. 2021;25(1):136-40. doi:10.4103/jomfp.JOMFP_316_19.

[12] Coleman H, Altini M, Ali H, Doglioni C, Favia G, Maiorano E. Use of calretinin in the differential diagnosis of unicystic ameloblastomas. Histopathology. 2001;38(4):312-317. doi:10.1046/j.1365-2559.2001.01100.x.
[13] Imran A, Tanveer S, Ranganathan K, Rao UK, Joshua E, Thavarajah R. Expression of calretinin and cytokeratin 19 in radicular cyst, dentigerous cyst, odontogenic keratocyst, and ameloblastoma. J NTR Univ Health Sci. 2016;5:118-122.
[14] Rudraraju A, Venigalla A, Babburi S, Soujanya P, Subramanyam RV, Lakshmi KR. Calretinin expression in odontogenic cysts and odontogenic tumors and the possible role of calretinin in pathogenesis of ameloblastoma. J Oral Maxillofac Pathol. 2019;23:349-355.
[15] Orikpete EV, Omoregie OF, Ojo MA. Calretinin expression in unicystic ameloblastoma and odontogenic cysts. J Biosci Med. 2020;8:111-120.
[16] Sunjaya HA, Fatah WR, Rahadiani N, Vitria EE. Comparative study of calretinin expression in dentigerous cyst, odontogenic keratocyst, and unicystic ameloblastoma. J Int Dent Med Res. 2021;14(3):965-969.
[17] Piattelli A, Fioroni M, Iezzi G, Rubini C. Calretinin expression in odontogenic cysts. J Endod. 2003;29(6):394-396. doi:10.1097/00004770-200306000-00003.
[18] DeVilliers P, Liu H, Suggs C, Simmons D, Daly B, Zhang S, et al. Calretinin expression in the differential diagnosis of human ameloblastoma and keratocystic odontogenic tumor. Am J Surg Pathol. 2008;32(2):256-260. doi:10.1097/PAS.0b013e3181452176.
[19] Vaidya M, Dmello C, Mogre S. Utility of keratins as biomarkers for human oral precancer and cancer. Life (Basel). 2022;12(3):343.
[20] Hormia M, Oksala E, Vähäkangas K. Expression of cytokeratins in odontogenic cysts and tumors. J Oral Pathol Med. 1991;20(7):313-318.
[21] Fukumashi K, Enokiya Y, Inoue T. Cytokeratin expression of constituting cells in ameloblastoma. Bull Tokyo Dent Coll. 2002;43(1):13-21.
[22] Kamath KP, Vidya M. Cytokeratin 19 expression patterns of dentigerous cysts and odontogenic keratocysts. Ann Med Health Sci Res. 2015;5(2):119-123.
[23] Bhakhar VP, Shah VS, Ghanchi MJ, Gosavi SS, Srivastava HM, Pachore NJ. A comparative analysis of cytokeratin 18 and 19 expressions in odontogenic keratocyst, dentigerous cyst and radicular cyst with a review of literature. J Clin Diagn Res. 2016;10(7):ZC85-ZC89.