Natural Resources for Human Health
eISSN: 2583-1194

Original Research

Received 14 July 2026
Revised 11 Aug 2026
Accepted 24 Aug 2026

Natural Resources for Human Health 2026, Vol. 6 (18s): 1364–1372

KEYWORDS:
SPA, DPA, hand, branching patterns, circulation

A Comprehensive Examination of Palmar Arches: Formation and Branching in Soft Embalmed Cadavers

Dr. Anita R Gune[1], Dr. Ashalata D Patil[2], Dr. Arun S Karmalkar[3]

[1]Professor & H.O.D, Department of Anatomy, D.Y. Patil Medical College, Kolhapur.
[2]Professor, Department of Anatomy, D.Y. Patil Medical College, Kolhapur.
[3]Professor, Department of Anatomy, D.Y. Patil Medical College, Kolhapur.
*Corresponding author: Dr. Anita R Gune.,
Professor & H.O.D, Department of Anatomy, D. Y. Patil Medical College, Kolhapur, Maharashtra, India.
Email: anitargune@gmail.com

ABSTRACT: **Background**: Variations in superficial palmar arch formation influence the anatomical pathways supplying the palm and digits. This study examined arch completeness, contributing arteries, and branching configurations in soft-embalmed cadaveric hands.

Methods: Thirty adult hands, comprising paired right and left specimens from 15 donors, underwent dissection under microscopic magnification. The superficial palmar arch and its contributing vessels were exposed, and observed configurations were documented

Results: Radial–ulnar, ulnar-only, and radial–ulnar–median complete configurations were reported in 14, six, and two hands, respectively. Eight hands had incomplete superficial arches. These frequencies remain provisional until the conflicting abstract count and incomplete Type A entry are reconciled

Conclusion: The specimens demonstrated variation in superficial palmar arch formation and branching. These observations provide descriptive anatomical information but do not establish functional collateral adequacy or predict postoperative ischemia.

INTRODUCTION

Hand's intricate vascular structure has been essential for maintaining its health and functionality. The SPA as well as DPA form a complex collateral flow network that provides artery feed to the hand. These artery arches provide appropriate blood flow to hand's complicated network of muscles, bones, and soft tissues. The superficial and deep palmar arches form major components of the hand's arterial network. Their configurations vary, and pooled evidence indicates that complete superficial arches occur less consistently than complete deep arches (Zarzecki et al., 2018).

Standring et al. contend that UA has been primary cause of SPA. One-third of SPA has been supplied by UA, superficial palmar branch of radial artery (RA), along with arteria radialis indicis (Standring et al., 2009). UA, RA, as well as persisting median arteries (MA) all contribute in different ways to the very varied SPA (Loukas et al., 2005; Takkallapalli et al., 2011). In 1897, Jachtschinski divided the SPA variations into 2 groups: partial and complete (Jaschtschinski, 1897).

The primary component that forms DPA is RA. DPA has been developed through anastomosis of terminal segment of RA with DPBUA (deep palmar branch of the ulnar artery) (Standring et al., 2009). RA travels through hand, passing through deep palm as well as around thumb. This vessel is known as DPA because of its arch-like shape. The thumb and index finger receive

blood supply from this small yet crucial channel, which branches off into tiny segments. For most people, it also correlates with SPA.

In accordance with current common use categorization and definition, an incomplete arch is one that lacks anastomosis between the vessels that contribute to it, whereas a complete arch has anastomosis (Takkallapalli et al., 2011). Arch is also considered complete when UA creates the SPA alone if UA reaches area across thumb and first digit (Baetz et al., 2011).

When executing skin flaps, hand surgeons must be aware of the palmar arches to prevent unintentional devascularization. The ulnar artery or SPA injury can impair the fingers' vascular supply, particularly if there has been inadequate anastomosis among superficial and DPA (Ruengsakulrach et al., 2001).

Since SPA provides majority of blood flow during thumb surgeries, closure of the RA might not be enough to prevent excessive bleeding. Therefore, prior to beginning any invasive operations, including vascular surgeries, examinations such as angiography, colour Doppler tests, along with Allen tests of hand must be performed. The hand's vessels can be seen with Doppler and angiographic examinations, but the tiny connecting vessels are not sufficiently evaluated (Bilge et al., 2006; Brzezinski et al., 2009).

The UA directly extends into SPA. A superficial branch of RA or another branch completes it on lateral side. The arch crosses palm at extended thumb's level of distal border as well as curves laterally deep to palmar aponeurosis along with superficial to long flexor tendons.

Direct continuation of RA, DPA has been accomplished by a deep branch of UA on medial side of arch. Curves medially positioned deep to elongated flexor tendons; it contacts bases of metacarpals.

From SPA, common palmar digital arteries (CPDA) go distally on lumbricals to finger webbing.

Originating from CPDA, the proper palmar digital arteries travel along sides of second and fifth fingers.

When RA turns into a palm, Princeps pollicis is formed. Descends on palmar aspect of first metacarpal, splitting into 2 branches which travel down thumb's sides at base of proximal phalanx.

Although it may arise from princeps pollicis artery, the radialis indicis originates in RA. Travels to distal end of index finger from its lateral side.

RA as well as UA are the origins of dorsal carpal arch. Fascial arches on hand's dorsum.

In terms of clinical significance, RA along with UA perform a major function in SPA and DPA. It is particularly crucial to consider RA's function in the thenar muscles as well as fingers when harvesting it (Loukas et al., 2005). The study described above was conducted to better understand the architecture and branching patterns of SPA as well as DPA. These anatomical dissections will serve as a baseline for future ultrasound investigation on neurovascular network's structure in relation to superficial palmar creases.

METHODOLOGY

The present prospective study has been executed at Medical College, Department of Anatomy. Sample size was calculated for qualitative (attribute) data using formula Z2 1-α/2 X P X (1- P) / d2. 30 adult hands of 15 soft embalmed cadavers were randomly selected for the study.

Inclusion criteria: All adult cadavers soft embalmed in department of Anatomy in following two years.

Exclusion criteria: Cadavers with deformity of hand or amputated hands.

After ethical clearance, Superficial and DPA of every specimen were dissected carefully under magnification with help of dissecting microscope. Through the use of a surgical microscope with a magnification of 2–5.5×, hand's palmar surfaces had been dissected. The dissection processes were carried out according to the directions in Cunningham's Manual of Practical Anatomy (Vol.1). Following the palm skin incision, the skin and superficial fascia were reflected. The exposed Palmar aponeurosis was then cut at the proximal end (apex) and reflected towards the fingers, with the intervening medial and lateral septate meticulously sliced. The Superficial Palmar Arch and its branches were exposed and thoroughly dissected by removing

fat and fascia. The arteries involved in the creation of the Superficial Palmar Arch were examined and documented. The results were analyzed using statistical methods (Arrchana et al., 2018).

RESULT

Above-mentioned study identified patterns of whole types of SPA. SPA is developed by union of artery's radial along with ulnar superficial branches (Group I Type A). In 14 specimens, this pattern had been seen (46.66%).

Only UA, which supplied branches to every finger, that includes thumb (Group I Type B), constituted the SPA. Six specimens (20%) exhibited this pattern.

The superficial branches of the UA, RA, as well as MA join to establish SPA (Group 1 Type C). This pattern appeared in two specimens (6.66%).

Eight specimens (26.66%) out of the thirty total had an incomplete SPA. The patterns of SPA incomplete that were noted in investigation mentioned above are listed below.

SPA created by RA without anastomosis and superficial branch of UA (Group II Type A). Sixty-six percent of the specimens had such a condition.

Up to ulnar side of index finger, that is created by superficial branch of UA, SPA supplied the fingers. (Group II Type B). Four specimens (13.33%) had this pattern.
SPA was created from MA without anastomosis and UA's superficial branch (Group II Type C). Two specimens (6.66%) had this pattern.
Different branching patterns were noted:

The common trunk begins at SPA and divides into the first dorsal metacarpal, Princeps pollicis, and Radialis indices. Two common trunks were visible in SPA.

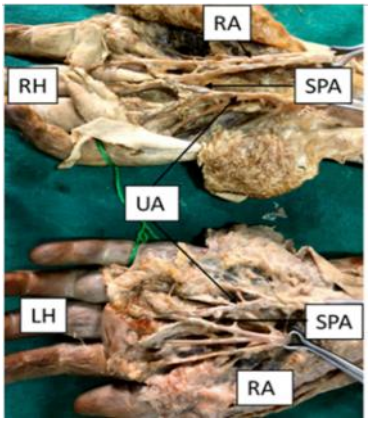

Fig. "1: Complete Superficial Palmar Arch RH- Right Hand, LH- Left Hand, UA- Ulnar artery, RA- Radial Artery SPA- Superficial Palmar" Arch

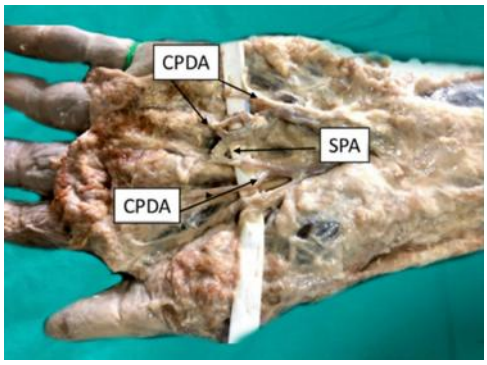

Fig. 2: Branches of Superficial Palmar Arch SPA-Superficial Palmar Arch, CPDA- Common Palmar Digital Artery

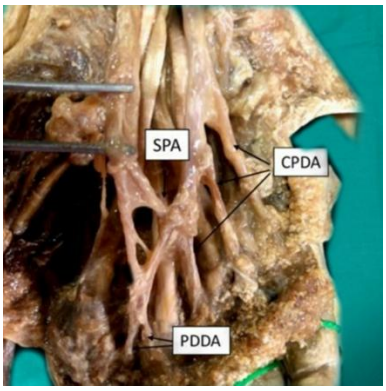

Fig. 3: "Branches of Superficial Palmar Arch SPA-Superficial Palmar Arch, CPDA- Common Palmar Digital Artery PPDA-Proper Palmar Digital" Artery



Fig. 4: Group I Type a Complete "Arch: UA-Ulnar artery& SPRA- Superficial palmar branch of radial" artery

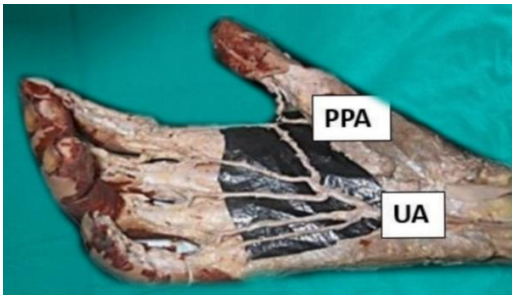

Fig.5: Group I Type B Complete arch: UA- Ulnar artery & Princeps pollicis artery

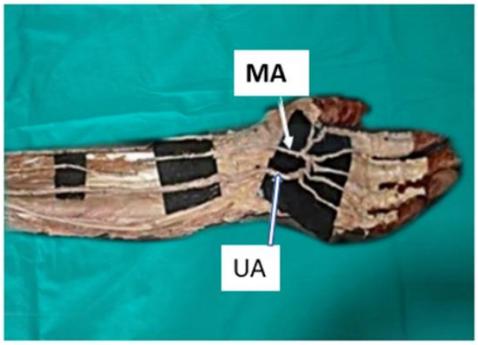

Fig. 6: Group I Type C Complete arch: "UA- Ulnar artery & MA-Median" artery

Natural Resources for Human Health
eISSN: 2583-1194

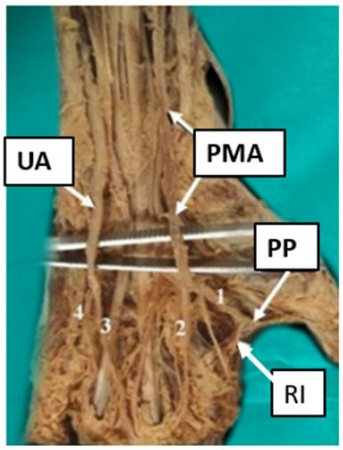

Fig. 7: Group I Type C Complete arch, PMA- Persistent Median artery, UA- Ulnar artery, RI: Radialis indices; 1, 2, 3, 4: Common palmar digital arteries. PP: Princeps pollicis.

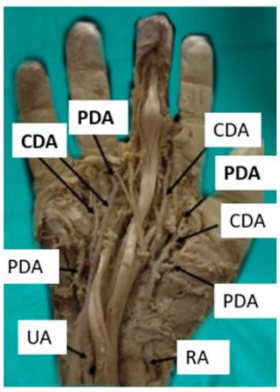

Fig. 8: Group II Type a "Superficial palmar arch with both the superficial branches of the ulnar artery (UA) and the radial artery (RA) entering the hand. Both the UA and the RA gave off one proper palmar digital artery (PDA) and 2 common palmar digital arteries" (CDA).

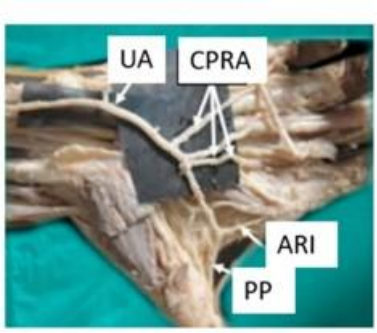

Fig.9: Group II Type B Incomplete superficial arch. Photograph showing the formation of SPA by superficial branch of ulnar artery alone. (UA: Ulnar artery; CPDA: common palmar digital arteries; PP: Princeps pollicis; ARI: Arteria Radialis indices)

DISCUSSION

In their analysis, Coleman & Anson discovered that 78.5% of specimens had the complete type of SPA and 21.5% had the incomplete type (Coleman et al., 1961). In their study on the Negro population, Godwin O. Mbaka et al. found that 73.9% of

the participants had complete SPA and 26.1% had incomplete SPA (Mbaka et al., 2014). According to Chandni Gupta et al.'s research, 77.3% of participants had complete SPA and 22.6% had incomplete SPA (Gupta et al., 2015). In their study, Zareena Shaik et al. found 67% of individuals had complete SPA and 33% had incomplete SPA (Shaik et al., 2016). In their investigation, Singh et al. found 92% of specimens had complete SPA while the other 8% had incomplete SPA (Singh et al., 2017). In their investigation, Mamatha Tonse et al. discovered 88% of specimens had complete SPA as well as 12% had incomplete arch (Tonse et al., 2014).

The classical palmar arch, or Group I (Type A) of Superficial Palmar Arch, is more common as seen in our present study, according to research comparing it to that of researchers such as Ikeda et al. (1988), Patnaik et al. (2002), M. Chimmalgi et al. (2004), Bilge O (2006), Tagil (2007), Madhyastha S. (2011), and Umapathy Sembian et al. (2012). These studies were based on Coleman and Anson's (1961) classification of palmar arterial arches. The explanations for the arterial variations are primarily based on classical outlines of arterial development. Developmental evidence shows that on attaining the hand the ulnar artery links with the superficial palmar plexus from which superficial palmar arch originates, at the same time as the median artery loses its distal connection and is reduced to a small vessel.

Ontogenic foundation: In keeping with traditional studies of Caplan and Koutroupas, myogenic areas grow to be vascular and chondrogenic regions turn out to be clean and avascular. by way of sixth week, ulnar artery is apparent and branches from brachial artery progressing down the hand plate to shape the deep palmar arch. The radial artery develops later and is more variable progressing down the preaxial side of the limb. sooner or later, median and interosseous arteries decrease in length, and median artery degenerates, offering only some blood supply to median nerve the small vestige of interosseous artery terminates in many small branches (rete machine) in the carpus (Borud et al., 2006).

Arey is of the view that the anomalies of blood vessels can be due to the choice of unusual paths inside the primitive vascular plexuses, the persistence of vessels normally retained, incomplete development or fusion and absorption of elements typically obliterate, the disappearance of vessels usually retained, incomplete improvement, or fusion and absorption of parts generally distinct (Arey, 1957). The radial artery is a frequent website online for introducing catheter for arterial pressure monitoring or to create arteriovenous fistulae. in addition, greater, Acar et al (2008) said the artery has additionally been used as an opportunity for myocardial revascularization. Such techniques are not without risk as they could reason necrosis in special components of the hand or ability damage to the blood deliver of the forearm and hand. The anastomosis between the ulnar and the radial arteries is essential for preserving ok blood supply to the palm and its digits. Considering SPA is the center of enchantment for most of the procedures and worrying occasions inside the hand, the hand doctor wishes to refer to the life and wholesome feature of the arch before surgical strategies including, arterial upkeep, vascular graft packages, and unfastened and/or pedicled flaps depending on radial or ulnar artery, to be able to preserve or now not to harm the perfusion of the hand and digits (Tagil et al., 2007). Even whilst making incisions to evacuate pus from the hand, special attention must be paid to the superficial position of termination of ulnar artery and SPA (Lockhardt et al., 1959).

If confirmed, the complete-arch frequency of 22/30 hands would be 73.3%. This is descriptively close to the 75.05% pooled estimate in an updated meta-analysis, although an earlier synthesis reported 81.3%; these comparisons should not be interpreted as evidence of population differences (Plutecki et al., 2026).

CONCLUSION

For a number of procedures, RA has been often manipulated. RA forearm flap can be elevated, an arteriovenous fistula can be created, and a catheter can be inserted there frequently for arterial pressure monitoring. Therefore, during surgery, any variation in the collateral blood flow among RA as well as UA becomes crucial. Before RA harvesting for goal of cardiac revascularization, knowledge of the various SPA patterns is essential. Before invasive or interventional surgery, it is highly advised to analyse the vascular pattern. This will enable the identification of any anomalies that may require a change in surgical technique. Consequently, it is imperative to evaluate the SPA using research methods such as Doppler ultrasonography, angiography, photo plethysmography and oximetric technique.

Acknowledgements

The authors sincerely thank the Department of Anatomy, D.Y. Patil Medical College, Kolhapur, for providing the necessary infrastructure, cadaveric specimens, and support for this study. We are grateful to the body donors and their families whose

selfless contribution made this anatomical research possible. We also acknowledge the laboratory staff for their technical assistance in the preparation and preservation of soft embalmed cadavers. We further acknowledge the Institutional Ethical and Research Committee for their timely approval and guidance.

Funding

The authors declare that we received internal funding from D.Y. Patil Education Society (Deemed to be university), Kolhapur was received for this study. The research was conducted using institutional resources and self-funded by the authors.

Author Contributions

- **Dr. Anita R Gune:** Conceptualization, study design, cadaveric dissection, data collection, data analysis, manuscript drafting, and final approval.
- **Dr. Ashalata D Patil:** Literature review, data interpretation, manuscript revision, and final approval.
- **Dr. Arun S Karmalkar:** Cadaveric dissection, anatomical assessment, data interpretation, and final approval.

All authors have read and approved the final version of the manuscript.

Data Availability Statement

The data supporting the findings of this study are available from the corresponding author upon reasonable request. Due to institutional ethical restrictions and the sensitive nature of cadaveric data, the raw data are not publicly available. Researchers with a legitimate interest may contact the corresponding author for access, subject to institutional approval.

Conflicts of Interest

The authors declare that there are no conflicts of interest regarding the publication of this study. No financial or personal relationships with other people or organizations have inappropriately influenced this work.

List of Abbreviations

Abbreviation	Definition
SPA	Superficial Palmar Arch
DPA	Deep Palmar Arch
Rt.	Right
Lt.	left
RA	Radial artery
UA	Ulnar artery
DPBUA	deep palmar branch of the ulnar artery
CPDA	common palmar digital arteries

REFERENCES

[1] Zarzecki, M.P., Popieluszko, P., Zayachkowski, A., Pękala, P.A., Henry, B.M., Tomaszewski, K.A., 2018. The surgical anatomy of the superficial and deep palmar arches: A Meta-analysis. Journal of Plastic, Reconstructive & Aesthetic Surgery 71(11), 1577–1592.

[2] Standring, S., Borley, N.R., Collins, P., et al., 2009. Gray's Anatomy, The Anatomical Basis of Clinical Practice, Fortieth edition. Churchill Livingstone (Elsevier), pp. 2321–2330.

[3] Loukas, M., Holdman, D., Holdman, S., 2005. Anatomical variations of the superficial and deep palmar arches. Folia Morphologica (Warsz) 64(2), 78–83.

[4] Takkallapalli, A., Kalbande, S., Dombe, D., et al., 2011. Variations in the formation of superficial palmar arch and its clinical significance in hand surgeries. International Journal of Biological and Medical Research 2(2), 543–546.
[5] Jaschtschinski, S.N., 1897. Morphologie und Topographie des Arcus volaris sublimes und prefundus des Menchen. Anatomische Hefte 7, 161–188.
[6] Baetz, L., Satiani, B., 2011. Palmar arch identification during evaluation for radial artery harvest. Vascular and Endovascular Surgery 45(3), 255–257.
[7] Ruengsakulrach, P., Eizenberg, N., Fahrer, C., et al., 2001. Surgical implications of variations in hand collateral circulation: anatomy revisited. Journal of Thoracic and Cardiovascular Surgery 122(4), 682–686.
[8] Bilge, O., Pinar, Y., Ozer, M.A., et al., 2006. A morphometric study on the superficial palmar arch of the hand. Surgical and Radiologic Anatomy 28(4), 343–350.
[9] Brzezinski, M., Luisetti, T., London, M.J., 2009. Radial artery cannulation: a comprehensive review of recent anatomic and physiologic investigations. Anesthesia & Analgesia 109(6), 1763–1781.
[10] Arrchana, S., Arumugam, et al., 2018. Anatomical study of superficial palmar arch and its variations with clinical significance. International Journal of Anatomy and Research 6(2.1), 5127–5133.
[11] Coleman, S.S., Anson, B.J., 1961. Arterial patterns in the hand based upon the study of 650 specimens. Surgery, Gynecology & Obstetrics 113, 409–424.
[12] Mbaka, G.O., Ejiwunmi, A.B., Olabiyi, O.O., 2014. Pattern of variations in superficial palmar arch in 134 Negro cadaveric hands. Italian Journal of Anatomy and Embryology 119(3), 153–162.
[13] Gupta, C., Kalthur, S.G., Nair, N., Pai, S.R., 2015. A Morphological study of variations in superficial palmar arches of the hand. CHRISMED Journal of Health and Research 2(2), 140–144.
[14] Shaik, Z., Ramulu, M.V., Eluru, R., 2016. A study on superficial palmar arch and its variations. International Journal of Innovative Research and Advance Studies 3(9), 52–55.
[15] Singh, S., Lazarus, L., De Gama, B.Z., Satyapal, K.S., 2017. An anatomical investigation of the superficial and deep palmar arches. Folia Morphologica 76(2), 219–225.
[16] Tonse, M., Rai, R., Saralay, V., Vadgonkar, R., Rai, A.R., Sadashiv, R., 2014. Formation of Superficial palmar arch; A cadaveric study with its clinical significances. IOSR Journal of Dental and Medical Sciences 13(3-ii), 100–103.
[17] Ikeda, Ugava, Kazihara, Hamada, 1988. Arterial patterns in the hand based on a three-dimensional analysis of 220 cadaver hands. American Journal of Hand Surgery 13(4), 501–509.
[18] Patnaik, V.V.G., Kalsey, G., Singla Rajan, K., 2002. Palmar arterial arches - A morphological study. Journal of the Anatomical Society of India 51(2), 7–12.
[19] Chimmalgi, M., Sant, S.M., Chhibber, S.R., Humbarwadi, R.S., 2004. A study of superficial and deep palmar arches in human hands. Anatomica Karnataka 1(5), 90–97.
[20] Tagýl, S.M., Çiçekcibaþý, A.E., Ögün, T.C., Büyükmumcu, M., Salbacak, A., 2007. Variations and Clinical Importance of the Superficial Palmar Arch. SDÜ Týp Fakültesi Dergisi 14(2), 11–16.
[21] Madhyastha, S., Murlimanju, B.V., Jiji, P.J., Saralaya, V.V., Rai, A., Vadgaonkar, R., 2011. Morphological variants of the human superficial palmar arch and their clinical implications. Journal of Morphological Sciences 28(4), 261–264.
[22] Sembian, U., Kamala, E., Muhil, M., Nalina Kumari, 2012. A Study of variations in the formation of superficial palmar arch in the rural population of southern Tamilnadu. International Journal of Anatomy Radiology and Surgery 1(1), 7–11.
[23] Borud, L.J., Mathes, S.J., et al., 2006. Plastic Surgery The Hand and Upper Limb, Part 2, Vol. VIII: Embryology of the upper limb, 2nd Edition. Saunders Elsevier, Philadelphia, PA, pp. 3–23.
[24] Arey, 1957. Developmental Anatomy: Development of the arteries, 6th Edition. W. B. Saunders Co., Philadelphia, pp. 375–377.
[25] Acarturk, T.O., Tuncer, U., Aydogan, L.B., Dalay, A.C., 2008. Median artery arising from the radial artery; its significance during harvest of a radial forearm free flap. Journal of Plastic, Reconstructive & Aesthetic Surgery 6, 5–8.
[26] Tagil, S.M., Cicekcibasi, A.E., Ogun, T.C., Buyukmumcu, M., Salbacaka, A., 2007. Variations and clinical importance of the superficial palmar arch. S.D.U. Tip Fakultesi Dergisi 14, 11–16.
[27] Lockhardt, R.D., Hamilton, G.F., Fyfe, F.W., 1959. Vascular system Systemic arteries. In: Anatomy of the Human Body. Feber & Feber Ltd., London, pp. 612–619.

[28] Plutecki, D., Bonczar, M., Walocha, J., Chaba-Karnaś, W., Jaśkiewicz, A., Kozioł, T., Bieńkowski, M., Kowalewska, K., Trystuła, M., Koziej, M., 2026. Anatomical variations of the superficial and deep palmar arches: an updated systematic review and meta-analysis. Folia Morphologica 85.