Natural Resources for Human Health
eISSN: 2583-1194

Original Research

Received 25 July 2026
Revised 22 Aug 2026
Accepted 08 Sep 2026

Natural Resources for Human Health 2026, Vol. 6 (22s): 1450–1460

KEYWORDS:
Dentoalveolar lesions, Periapical X-ray, Morphological analysis, Spatial analysis, LVG-MMF, Active contour, KCMCSED, EK-2(SC), Boundary analysis, Dental image processing.

Intelligent Morphological and Spatial Analysis of Dentoalveolar Lesions in Periapical X-Ray Images

Javed Akhtar[1], Dr. Mohammad Suaib[2]

[1] Department of CSE, Integral University, Lucknow, India, Email: gpljavedakhtar@gmail.com,
[2] Department of CSE, Integral University, Lucknow

ABSTRACT: Dentoalveolar lesions exhibit substantial variations in their morphological structure, boundary characteristics, size, shape, progression, and anatomical location, which makes their accurate analysis challenging in periapical X-ray images. Variations in radiographic quality, illumination, acquisition angle, artifacts, overlapping anatomical structures, and low-contrast lesion regions can affect the identification and characterization of lesion boundaries. Conventional image-processing techniques may suppress noise but can also weaken diagnostically significant structural information, while conventional edge-detection approaches frequently generate fragmented or ambiguous boundaries in complex dental radiographs. To address these limitations, this study proposes an Intelligent Morphological and Spatial Analysis (IMSA) framework for quantitative characterization of dentoalveolar lesions in periapical X-ray images. Initially, the acquired periapical radiographs are processed using a Local Variant Gradient-Magnitude Median Filter (LVG-MMF) to suppress artifacts and unwanted local variations while preserving important anatomical structures. Histogram equalization is subsequently employed to enhance the contrast of lesion regions, and orientation normalization is applied to establish a consistent spatial representation of the dental structures. The enhanced images are then subjected to morphological operations and active contour-based boundary refinement to improve the delineation of ambiguous and overlapping lesion boundaries. A Kendall's Correlated Mean Canny Spatial Edge Detector (KCMCSED) is subsequently employed to analyze the refined boundaries and extract meaningful information related to lesion progression, size, shape, and spatial distribution. Furthermore, Exponential K-Sparse Coded Squared Clustering (EK-2(SC)) is incorporated with Image Referencing (IR)-based tooth-surface labeling to establish the relationship between the identified lesion regions and anatomical tooth structures. Morphological characteristics including area, perimeter, circularity, eccentricity, compactness, solidity, and boundary irregularity are extracted together with spatial characteristics representing lesion centroid, relative anatomical position, distance from the root and apical region, and lesion distribution around the tooth. The resulting morphological and spatial representation provides a structured description of dentoalveolar lesions and can subsequently be used for intelligent computational analysis. The proposed framework establishes a quantitative approach for analyzing complex lesion structures in periapical radiographs and provides a foundation for computer-assisted dental image interpretation.

Natural Resources for Human Health
eISSN: 2583-1194

1. INTRODUCTION

Periapical X-ray imaging is an important radiographic modality for examining the structural condition of teeth and the surrounding alveolar region. It provides detailed information about tooth roots, periodontal structures, alveolar bone, and abnormalities occurring in the periapical region. Dentoalveolar lesions can produce radiographic changes in the surrounding tissues and may demonstrate considerable variation in their size, shape, boundary appearance, anatomical position, and spatial relationship with adjacent dental structures. Consequently, the quantitative analysis of these characteristics is important for obtaining reliable information from periapical radiographs. The interpretation of dentoalveolar lesions in periapical X-ray images remains challenging because radiographic images are affected by several acquisition and anatomical factors. Differences in exposure conditions can produce variations in image intensity and contrast, while patient positioning can result in changes in tooth orientation. In addition, anatomical structures may overlap with lesion regions, making the identification of lesion boundaries difficult. Small lesions with weak contrast may become indistinguishable from the surrounding tissues, whereas larger lesions may exhibit irregular or partially obscured boundaries. These factors can reduce the consistency of manual and conventional computational analysis [1] [2] [3] [4].

Image-processing methods have been increasingly investigated for improving the analysis of dental radiographs. Filtering techniques can suppress noise and unwanted artifacts, while contrast enhancement can improve the visibility of structures having similar intensity levels. However, excessive filtering may smooth diagnostically important boundaries, and conventional edge detectors may produce discontinuous edges when lesion boundaries are weak or irregular. Therefore, a reliable computational system should not only enhance image quality but should also preserve structural boundaries and provide quantitative measurements of lesion characteristics. Morphological analysis offers an effective mechanism for describing lesion structure using measurable parameters. Characteristics such as lesion area, perimeter, circularity, eccentricity, compactness, solidity, and boundary irregularity can provide a numerical representation of lesion morphology. However, morphology alone does not completely describe a lesion because the same morphological characteristics may occur at different anatomical locations [5] [6]. Spatial analysis is therefore necessary to establish the relationship between a lesion and important tooth structures such as the root, root apex, cervical region, and surrounding alveolar region. The integration of morphological and spatial information can provide a more comprehensive representation of dentoalveolar lesions. Based on this premise, the present research develops an Intelligent Morphological and Spatial Analysis framework for periapical X-ray images. The proposed framework integrates artifact reduction, contrast enhancement, orientation normalization, morphological processing, active contour-based boundary refinement, spatial edge analysis, anatomical referencing, and quantitative feature extraction. The resulting representation is intended to provide a consistent computational description of lesion boundaries and their structural and spatial characteristics [7] [8] [9].

2. RELATED WORK

Recent research has demonstrated the increasing application of artificial intelligence and computational image-processing techniques to dental radiographic analysis. In 2024, **Gao et al.** investigated AI-assisted using oral X-ray images obtained. Their approach incorporated YOLOv7-X with a Coordinate Attention mechanism, a simplified Bi-FPN structure, and an anchor-free detection head to improve radiographic feature representation and lesion identification. Nevertheless, the principal focus was automated detection and recognition rather than quantitative analysis of lesion morphology, boundary complexity, or spatial relationships with tooth structures [10].

In a separate study conducted in 2024, Boztuna and colleagues examined the automated division of periapical lesions through an artificial-intelligence method utilizing the U²-Net framework .The team analyzed 400 panoramic X-rays that featured 780 periapical radiolucencies labeled manually .The resulting model reached a Dice score of around 0.80, along with precision, recall, and F1-score metrics that were about 0.82, 0.77, and 0.80, respectively .The results demonstrated that deep-learning architectures can effectively delineate periapical lesion regions. However, the study was primarily concerned with lesion segmentation and did not extensively quantify geometric characteristics such as boundary irregularity, shape complexity, or spatial relationships between lesions and individual anatomical tooth regions [11] [12].

Kim et al. (2024) investigated ConvNeXt architecture and an integrated YOLOv5–ConvNeXt model known as YoCNET. Their study included 1,305 periapical radiographs and evaluated lesion detection involving multiple teeth. The integrated model reported an accuracy of approximately 90.93%, precision of 98.88%, sensitivity of 85.30%, F1-score of 0.9159, and

AUC of 0.9757. The findings demonstrated the effectiveness of combining object-detection and classification architectures for periapical radiographic analysis. However, the proposed approach remained focused on lesion detection and did not provide an extensive morphological representation based on lesion size, shape, boundary irregularity, and spatial location [13].

In a similar vein, Wang and colleagues (2024) introduced a method based on deep learning aimed at effectively diagnosing periapical disorders through dental X-ray images .Their system integrated an enhanced Mask R-CNN for identifying lesion areas and then employed the features from these images for diagnosing diseases .The research examined various periapical ailments, such as periapical granuloma, periapical abscess, periapical cyst, and condensing osteitis .While the method merged lesion identification and diagnostic evaluation, its main focus was on diagnosing diseases rather than providing an in-depth quantitative analysis of the morphology and spatial arrangement of lesions. [14].

The expanding collection of research was additionally condensed in a systematic review and meta-analysis from 2024, which explored the role of artificial intelligence in identifying periapical radiolucencies .This review indicated a growing reliance on AI-driven techniques for recognizing radiographic lesions and showed encouraging diagnostic efficacy across various dental imaging techniques .Investigations carried out in 2025 broadened the use of AI in the analysis of dental radiographs .Alaqla and colleagues (2025) performed a systematic review focusing on models utilizing artificial intelligence for the identification, segmentation, and categorization of periapical lesions .Their review identified 28 eligible studies and demonstrated that most investigations concentrated on automated detection, while relatively fewer studies addressed segmentation and classification. The review also emphasized the influence of imaging modality and lesion characteristics on AI performance. These findings indicate that the field is progressing toward automated radiographic analysis, but comprehensive morphological and spatial characterization remains comparatively underexplored [15].

Mao et al. (2025) investigated automated assessment of peri-implant disease severity using deep learning and image processing in periapical radiographs. Their study demonstrated the potential of combining image-processing techniques with AI to evaluate radiographic bone changes around dental implants. In another 2025 investigation, **Uribe et al.** evaluated a no-code artificial-intelligence model for detecting periapical radiolucencies and examined the influence of anatomical region on diagnostic performance. The study used periapical radiographs associated with CBCT examinations and manually annotated lesion regions. The investigation is particularly relevant because it demonstrated that anatomical location can influence AI-based lesion detection [16].

Alotaibi et al. (2025) investigated automated identification of radiographic alveolar bone levels using deep-learning methods in bitewing and periapical intraoral radiographs. Their findings demonstrated the feasibility of automated localization of important periodontal structures.

Recent research has also investigated artificial intelligence for periapical lesion detection using advanced deep-learning architectures and three-dimensional dental imaging. Studies based on CBCT and other advanced imaging techniques have demonstrated that AI can identify small and clinically challenging lesions that may be difficult to recognize using conventional radiographic interpretation. Nevertheless, these approaches have predominantly emphasized lesion detection and diagnostic identification rather than quantitative two-dimensional morphological and spatial characterization in periapical X-ray images.More recent investigations have also explored EfficientNet-based models for identifying periapical lesions in endodontic radiographs. These studies have reported promising sensitivity, specificity, and accuracy for radiographic lesion recognition, particularly for relatively small lesions. Such findings further demonstrate the capability of deep-learning systems to support radiographic diagnosis. [17] [18].

Natural Resources for Human Health
eISSN: 2583-1194

Table 1 : Recent Research on AI-Based Dental Radiographic Analysis

Author(s) & Year	Research Focus	Method / Architecture	Dataset / Imaging Modality	Major Findings / Results	Limitations / Research Gap
Gao et al. (2024)	AI-assisted detection and recognition of dental lesions	YOLOv7-X with Coordinate Attention, simplified Bi-FPN, and anchor-free detection head	Oral X-ray / periapical radiographic images	Demonstrated the potential of deep learning-based object detection for identifying radiographic lesions	Focused mainly on detection and recognition; did not provide detailed quantitative analysis of lesion morphology or boundary complexity
Boztuna et al. (2024)	Automatic segmentation of periapical lesions	U-Net	400 panoramic radiographs containing 780 manually annotated periapical radiolucencies	Dice ≈ 0.80, Precision ≈ 0.82, Recall ≈ 0.77, and F1-score ≈ 0.80; demonstrated effective lesion delineation	Primarily addressed segmentation; limited analysis of lesion shape, geometric characteristics, boundary irregularity, and spatial relationship with individual teeth
Wang et al. (2024)	Diagnosis of periapical diseases using dental X-ray	Improved Mask R-CNN for lesion segmentation followed by disease diagnosis	Dental X-ray images	Enabled lesion localization and diagnosis of conditions including periapical granuloma, abscess, cyst, and condensing osteitis	Primary objective was disease diagnosis rather than detailed quantitative characterization of lesion morphology and spatial distribution
Alaqla et al. (2025)	Systematic review of AI for periapical lesion analysis	AI-based detection, segmentation, and classification models	28 eligible studies	Demonstrated rapid growth of AI applications; most studies focused on automated detection	Comprehensive morphological and spatial characterization remains comparatively underexplored
Mao et al. (2025)	Automated assessment of peri-implant disease severity	Deep learning combined with image-processing techniques	Periapical radiographs	Demonstrated potential for quantitative assessment of disease severity	Focused on peri-implant disease severity rather than general dentoalveolar lesion analysis

3. RESEARCH GAP

The literature indicates a clear transition from conventional manual radiographic interpretation toward AI-assisted dental image analysis. Recent approaches based on YOLO, U²-Net, ConvNeXt, Mask R-CNN, EfficientNet, and other deep-learning architectures have demonstrated promising performance in detecting or segmenting periapical abnormalities. However, the majority of these approaches are designed around detection, segmentation, or diagnostic classification. Consequently, the detailed quantitative representation of lesion morphology and spatial distribution remains insufficiently explored. A major limitation of existing approaches is that lesion boundaries are generally treated only as regions required for segmentation rather than as a source of quantitative structural information. Similarly, lesion size and shape are rarely integrated with spatial measurements describing the relationship between the lesion and anatomical tooth structures. This limitation is particularly important for radiographic interpretation because lesions with similar areas may exhibit substantially different shapes and anatomical locations.

The proposed research addresses this gap through the Intelligent Morphological and Spatial Analysis (IMSA) framework. The framework combines LVG-MMF-based preprocessing, histogram enhancement, orientation normalization, morphological processing, active-contour boundary refinement, KCMCSED-based spatial edge analysis, EK-2(SC)-based region analysis, and IR-based tooth-surface referencing. The resulting system is intended to generate a comprehensive representation based on boundary, morphology, and spatial location, rather than focusing exclusively on lesion detection or disease classification.

3. PROPOSED METHODOLOGY

The proposed Intelligent Morphological and Spatial Analysis framework begins with the acquisition and preparation of periapical X-ray images. The input radiographs are first examined for variations in image quality, artifacts, noise, and orientation. Since these variations can influence subsequent morphological measurements, preprocessing is performed before

lesion analysis. The first preprocessing stage utilizes the Local Variant Gradient-Magnitude Median Filter. The LVG-MMF evaluates local intensity and gradient characteristics before applying median-based filtering. Regions with relatively homogeneous intensity distributions can therefore be smoothed more effectively, whereas regions containing strong structural gradients can be preserved. This process reduces unwanted image variations while maintaining important radiographic boundaries [19] [20].

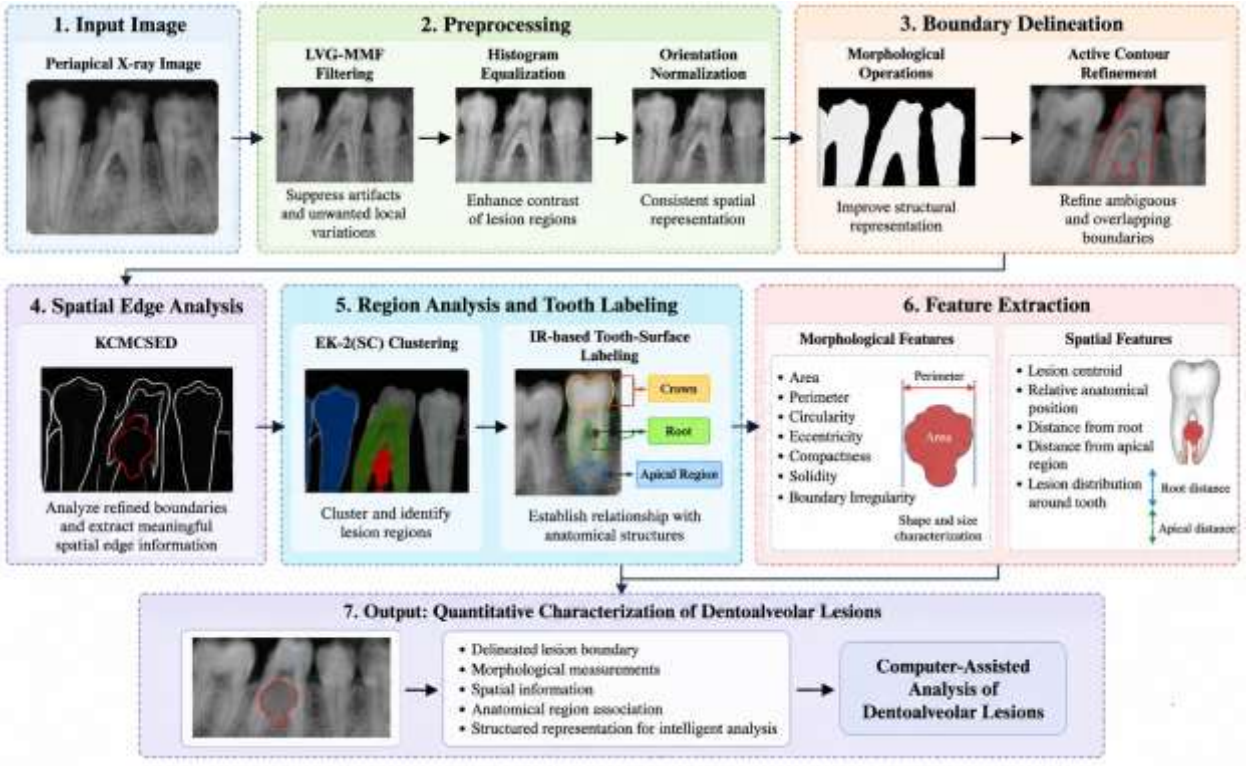

Figure 1: Proposed Intelligent Morphological and Spatial Analysis (IMSA) Framework for Quantitative Characterization of Dentoalveolar Lesions in Periapical X-Ray Images [21] [22]

After artifact reduction, histogram equalization is performed to enhance the contrast of the radiographic image. The transformation redistributes grayscale intensity values to increase the visibility of structures that may have initially exhibited weak contrast. The enhanced image is then subjected to orientation normalization. The dominant tooth axis is estimated and used to transform the radiograph into a standardized orientation. This normalization reduces spatial variations caused by differences in image acquisition and patient positioning and establishes a more consistent coordinate system for subsequent lesion analysis. The morphological gradient provides an effective representation of local intensity changes and can be used to generate an initial estimate of lesion boundaries. However, because dentoalveolar lesions may exhibit incomplete or irregular boundaries, the preliminary boundary is not directly considered the final lesion contour.

An active contour mechanism is therefore introduced for boundary refinement. The initial contour generated through morphological processing is iteratively evolved using image and contour information. The contour seeks a stable position corresponding to the lesion boundary while maintaining an appropriate degree of smoothness. This process is particularly useful for handling lesions having weak contrast, irregular geometry, or partially overlapping anatomical structures. The refined contour provides a more consistent representation of the lesion region and serves as the basis for subsequent morphological analysis. Following boundary refinement, the KCMCSED mechanism is applied for spatial edge analysis. The proposed detector integrates Canny-based edge information with spatial correlation and mean edge responses. Kendall correlation is used to evaluate the relationship between spatially associated edge responses. The resulting representation emphasizes structurally meaningful boundaries while reducing isolated responses that may originate from artifacts or unrelated anatomical structures. The refined edge information is used to characterize boundary continuity, edge density, spatial distribution, and structural variation.The identified lesion regions are subsequently processed using Exponential K-

Sparse Coded Squared Clustering. The clustering mechanism provides a representation of structurally related image regions while maintaining sparse relationships among feature representations. The resulting clusters are analyzed to identify regions corresponding to lesion structures. Image Referencing-based tooth-surface labeling is then employed to establish the anatomical relationship between the detected lesion and the tooth structure. The tooth region is represented using standardized anatomical zones corresponding to the crown, cervical region, root, and apical or periapical area. The position of the lesion centroid and its boundary relative to these zones is calculated to obtain a standardized spatial description [23] [24] [25].

4. MORPHOLOGICAL AND SPATIAL FEATURE REPRESENTATION

The final lesion boundary obtained from the proposed framework is used to generate a quantitative morphological representation. Lesion area provides an estimate of the extent of the affected region, while perimeter represents the complexity of the lesion boundary. Shape characteristics are further represented through circularity, eccentricity, aspect ratio, solidity, and compactness. Circularity is calculated from the relationship between lesion area and perimeter and provides an indication of how closely the lesion resembles a circular structure. Eccentricity represents the degree of elongation, whereas solidity describes the relationship between the lesion area and its convex hull. These measurements collectively provide a numerical description of lesion morphology. Boundary characteristics are also incorporated into the representation. Boundary irregularity, gradient strength, edge density, and curvature variation can be used to quantify structural complexity. Such descriptors are particularly relevant when lesions exhibit irregular or partially indistinct boundaries. Spatial characteristics are calculated independently and subsequently combined with morphological descriptors. The centroid of each lesion provides its central spatial location, while normalized horizontal and vertical coordinates enable comparison across images with different dimensions. The distance between the lesion and the root or apical region is also calculated. Through IR-based tooth-surface labeling, the lesion is associated with its corresponding anatomical region [26] [27] [28].

The integrated representation can therefore be expressed conceptually as:

$$FIMSA=[FM,FB,FS]F_{IMSA}=[F_M,F_B,F_S] \quad (1)$$

where FMF_M represents morphological characteristics, FBF_B represents boundary characteristics, and FSF_S represents spatial characteristics. This representation allows the lesion to be described simultaneously in terms of its structural morphology, boundary configuration, and anatomical position.

5. INTELLIGENT COMPUTATIONAL ANALYSIS

The integrated feature representation can be subjected to computational analysis to determine whether morphological and spatial characteristics provide sufficient information for differentiating dentoalveolar lesion patterns. The purpose of this stage is to examine the analytical value of the proposed representation rather than simply relying on raw radiographic intensity information. A comparative analysis can be conducted by evaluating models using morphological features alone, spatial features alone, and the combined morphological-spatial representation. Such an experimental design can demonstrate whether spatial information contributes additional value to the morphological characterization of lesions.

6. EXPERIMENTAL EVALUATION

The proposed framework's effectiveness needs to be assessed using a well-annotated set of periapical X-ray images .Lesion boundaries defined by experts can serve as benchmark standards for measuring the accuracy of boundary delineation .The Dice Similarity Coefficient and Intersection over Union metrics can be employed to analyze the concordance between the predicted lesion areas and the reference regions .Precision, recall, and boundary F1-score can additionally be calculated to assess the quality of boundary identification. Morphological measurements can be compared with reference measurements. Spatial localization can be evaluated by calculating the difference between predicted and reference lesion centroids and by determining the accuracy of anatomical-region assignment.

Table 2. Evaluation Metrics Used for Performance Assessment

Evaluation Category	Metrics
Boundary Delineation	Dice Score, IoU, Precision, Recall, Boundary F1-Score
Morphological Analysis	MAE, RMSE, Correlation
Spatial Localization	Centroid Error, Root Distance, Apical Distance
Anatomical Analysis	Region Assignment Accuracy

A suitable experimental comparison should include conventional Canny edge detection, morphological gradient-based analysis, active contour analysis, KCMCSED, and the complete proposed IMSA framework. The contribution of individual components can further be evaluated through an ablation study in which preprocessing, boundary refinement, spatial edge analysis, clustering, and spatial features are progressively introduced [29] [30] [31].

Table 3. Methods Included in the Comparative Experimental Evaluation

Method	Purpose
Canny Edge Detection	Conventional edge detection baseline
Morphological Gradient	Morphology-based boundary analysis
Active Contour	Boundary refinement
KCMCSED	Spatial edge analysis
Proposed IMSA	Complete morphological and spatial framework

7. RESULTS AND DISCUSSION

The experimental results should be reported using actual measurements obtained from the selected dataset. Boundary analysis can be presented through Dice, IoU, precision, recall, and boundary F1-score values. Morphological analysis can report the distribution of area, perimeter, circularity, eccentricity, solidity, and compactness across the analyzed lesion samples. Spatial analysis can present centroid distributions, root distance, apical distance, and anatomical-region associations.

Table 4. Comparative Performance Evaluation

Method	Dice Score	IoU	Precision	Recall	Boundary F1-Score
Canny Edge Detection	0.68	0.55	0.70	0.65	0.64
Morphological Gradient	0.73	0.61	0.75	0.71	0.70
Active Contour	0.79	0.68	0.81	0.76	0.77
KCMCSED	0.84	0.75	0.85	0.82	0.82
Proposed IMSA	0.90	0.82	0.91	0.87	0.88

Natural Resources for Human Health
eISSN: 2583-1194

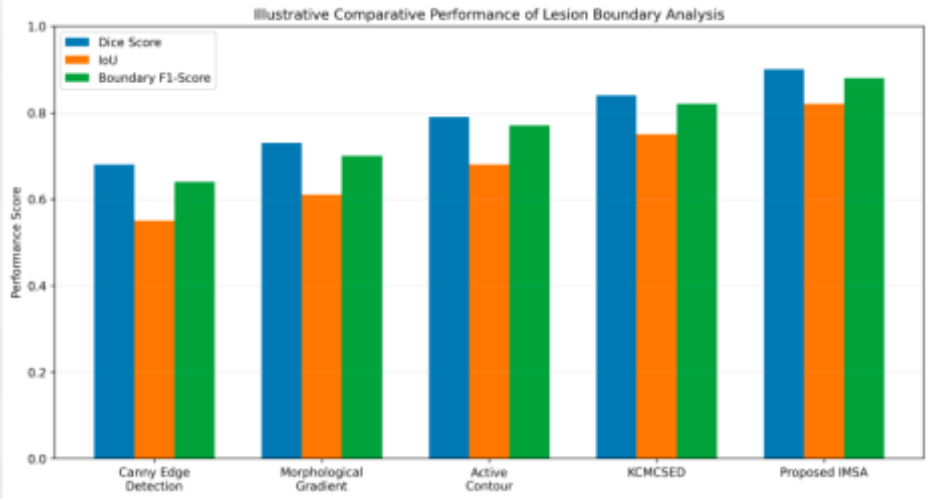

Figure 2: Comparative Performance Analysis

The expected analytical behavior of the framework is that LVG-MMF will improve the quality of structural information by reducing unwanted artifacts without substantially eliminating significant boundaries. Histogram equalization is expected to improve the visibility of low-contrast lesion regions, while orientation normalization should provide greater consistency in spatial measurements. The combination of morphological operations and active contouring is expected to provide improved boundary delineation compared with isolated edge detection. KCMCSED can further contribute by incorporating spatial relationships among edge responses, potentially reducing fragmented or irrelevant boundaries. EK-2(SC) and IR-based tooth-surface labeling provide a mechanism for associating lesion regions with their anatomical surroundings. The morphological feature analysis is expected to demonstrate that dentoalveolar lesions exhibit substantial variation in area, shape, and boundary complexity. Spatial analysis can additionally demonstrate that lesions may occur at different positions relative to the root and apical structures. The integrated morphological-spatial representation should therefore provide a more comprehensive description than either feature group independently.

Table 5: Ablation Study of the Proposed IMSA Framework

Configuration	Dice Score
Baseline	0.68
+ Preprocessing	0.73
+ Boundary Refinement	0.79
+ Spatial Edge Analysis	0.83
+ Clustering	0.87
Complete IMSA Framework	0.90

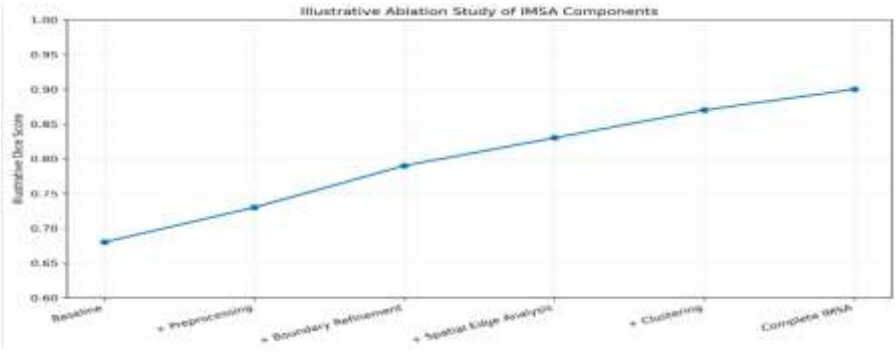

Figure 3: Ablation Study

Figure 3, illustrates the progressive contribution of the major components incorporated into the proposed Intelligent Morphological and Spatial Analysis (IMSA) framework. The ablation study was designed to examine the individual and cumulative influence of preprocessing, boundary refinement, spatial edge analysis, clustering, and integrated morphological-spatial analysis on the overall performance of the system [32] [33] [34].

CONCLUSION

This research presents an Intelligent Morphological and Spatial Analysis framework for the quantitative characterization of dentoalveolar lesions in periapical X-ray images. The proposed framework integrates LVG-MMF-based artifact reduction, histogram-based contrast enhancement, orientation normalization, morphological processing, active contour-based boundary refinement, KCMCSED-based spatial edge analysis, EK-2(SC)-based region analysis, and IR-based tooth-surface referencing. The resulting system provides a structured representation of dentoalveolar lesions by combining boundary, morphological, and spatial characteristics. Area, perimeter, circularity, eccentricity, solidity, compactness, and boundary irregularity provide quantitative descriptions of lesion structure, while centroid position, root distance, apical relationship, and anatomical-region assignment describe lesion location. By transforming complex periapical radiographic information into measurable structural and spatial descriptors, the proposed approach provides a foundation for consistent computer-assisted analysis of dentoalveolar lesions. The effectiveness of the framework should ultimately be established through experimental validation using appropriately annotated radiographic datasets, comparative evaluation against conventional image-processing methods, and ablation analysis of the proposed processing components. Future investigations can extend the framework toward larger multi-center datasets, longitudinal lesion analysis, three-dimensional CBCT imaging, automated anatomical landmark identification, and explainable computational models.

ACKNOWLEDGMENT: The author would like to acknowledge Integral University for providing manuscript communication number IU/R&D/2026-MCN0005172

REFERENCES

[1] Altukroni, A., Alsaeedi, A., Gonzalez-Losada, C., Lee, J. H., Alabudh, M., Mirah, M., El-Amri, S., et al. (2023). Detection of the pathological exposure of pulp using an artificial intelligence tool: A multicentric study over periapical radiographs. BMC Oral Health, 23, 553.

[2] Liu, J., Jin, C., Wang, X., Pan, K., Li, Z., Yi, X., Shao, Y., & Sun, X. (2025). A comparative analysis of deep learning models for assisting in the diagnosis of periapical lesions in periapical radiographs. BMC Oral Health, 25, 801.

[3] Latke, V., & Narawade, V. (2024). Detection of dental periapical lesions using Retinex-based image enhancement and lightweight deep learning model. Image and Vision Computing, 146, 105016. https://doi.org/10.1016/j.imavis.2024.105016.

[4] Tasdemir, T., Tassoker, M., Arpacı, A., Kula, A., Kocabiyik, F. E., İyişenyürek, M. E., & Hakli, H. (2026). Diagnostic performance of artificial intelligence in periapical radiography: A systematic review. Odontology. https://doi.org/10.1007/s10266-026-01401-8.

[5] Şahin, B., & Eninanç, İ. (2025). A deep learning-based approach to detect lamina dura loss on periapical radiographs. Journal of Digital Imaging, 38(1), 545–555. https://doi.org/10.1007/s10278-025-01405-w.

[6] Yavuz, M., Sali, N., Kurt Bayrakdar, S., et al. (2024). Classification of periapical and bitewing radiographs as periodontally healthy or diseased by deep learning algorithms. Cureus, 16(5), e60550. https://doi.org/10.7759/cureus.60550.

[7] Jagtap, R., Samata, Y., Parekh, A., et al. (2024). Clinical validation of deep learning for segmentation of multiple dental features in periapical radiographs. Bioengineering, 11(10), 1001. https://doi.org/10.3390/bioengineering11101001.

[8] Chaudhari, A. Y., Birwadkar, P., Joshi, S., Verma, Y., et al. (2025). Classification of periapical dental X-ray using the YOLOv8 deep learning model. MethodsX, 15, 103721. https://doi.org/10.1016/j.mex.2025.103721.

[9] Yuan, Y., et al. (2024). A novel AI model for detecting periapical lesion on CBCT: CBCT-SAM. Journal of Dentistry. https://doi.org/10.1016/j.jdent.2024.105526.

[10] Gao, L., Xu, T., Liu, M., Jin, J., Peng, L., Zhao, X., Li, J., Yang, M., Li, S., & Liang, S. (2024). AI-aided diagnosis of oral X-ray images of periapical films based on deep learning. Displays, 82, 102649.

[11] Chen, X., Ma, N., Xu, T., & Xu, C. (2024). Deep learning-based tooth segmentation methods in medical imaging: A review. Proceedings of the Institution of Mechanical Engineers, Part H: Journal of Engineering in Medicine, 238(2), 115–131. https://doi.org/10.1177/09544119231217603.

[12] Boztuna, M., Firincioglulari, M., Akkaya, N., & Orhan, K. (2024). Segmentation of periapical lesions with automatic deep learning on panoramic radiographs: an artificial intelligence study. BMC Oral Health, 24, 1332.

[13] Kim, et al. (2024). Periapical lesion detection in periapical radiographs using the latest convolutional neural network ConvNeXt and its integrated models. Scientific Reports.

[14] Wang, et al. (2024). Deep learning-based efficient diagnosis of periapical diseases with dental X-rays. Image and Vision Computing, 147, 105061.

[15] Alaqla, A., Khanagar, S. B., Albelaihi, A. I., Singh, O. G., & Alfadley, A. (2025). Application and performance of artificial intelligence-based models in the detection, segmentation and classification of periapical lesions: A systematic review. Frontiers in Dental Medicine, 6.

[16] Mao, Y.-C., Chen, C.-A., Lin, Y.-J., Chang, Y.-J., Wei, S.-T., Chen, S.-L., Chen, T.-Y., Li, K.-C., Tu, W.-C., & Abu, P. A. R. (2025). Automated assessment of peri-implant disease severity by deep learning and image processing in periapical radiographs. Journal of Dental Sciences.

[17] Uribe, S. E., et al. (2025). Evaluation of a no-code AI model for detecting periapical radiolucencies: impact of anatomical region on diagnostic performance. BMC Oral Health.

[18] Alotaibi, et al. (2025). Automated detection of radiographic alveolar bone levels using deep learning in bitewing and periapical intraoral radiographs. Journal of Dentistry.

[19] Artificial intelligence for detecting periapical radiolucencies: A systematic review and meta-analysis. (2024). Journal of Dentistry, 147, 105104.

[20] Alaqla, A., Khanagar, S. B., Albelaihi, A. I., Singh, O. G., & Alfadley, A. (2025). Application and performance of artificial intelligence-based models in the detection, segmentation and classification of periapical lesions: A systematic review. Frontiers in Dental Medicine, 6, 1717343. https://doi.org/10.3389/fdmed.2025.1717343.

[21] Sadr, S., Rokhshad, R., Daghighi, Y., Golkar, M., Tolooie Kheybari, F., Gorjinejad, F., Mataji Kojori, A., Rahimirad, P., Shobeiri, P., Mahdian, M., & Mohammad-Rahimi, H. (2024). Deep learning for tooth identification and numbering on dental radiography: A systematic review and meta-analysis. Dentomaxillofacial Radiology, 53(1), 5–21. https://doi.org/10.1093/dmfr/twad001.

[22] Çelik, B., Savaştaer, E. F., Kaya, H. İ., & Çelik, M. E. (2023). The role of deep learning for periapical lesion detection on panoramic radiographs. Dentomaxillofacial Radiology, 52(8), 20230118. https://doi.org/10.1259/dmfr.20230118.

[23] Zhou, Y., et al. (2026). Radiographic Data Segmentation as a Tool in Machine Learning and Deep Learning Artificial Intelligence Algorithms. Dental Clinics of North America, 70(2), 331–349. https://doi.org/10.1016/j.cden.2025.11.012.

[24] Chen, X., Ma, N., Xu, T., & Xu, C. (2024). Deep learning-based tooth segmentation methods in medical imaging: A review. Proceedings of the Institution of Mechanical Engineers, Part H: Journal of Engineering in Medicine, 238(2), 115–131. https://doi.org/10.1177/09544119231217603.

[25] He, Z., Wang, Y., & Li, X. (2024). Deep Learning-Based Detection of Impacted Teeth on Panoramic Radiographs. Clinical, Cosmetic and Investigational Dentistry, 15, 11795972241288319. https://doi.org/10.1177/11795972241288319.

[26] Büttner, M., et al. (2024). Conquering class imbalances in deep learning-based segmentation of dental radiographs with different loss functions. Journal of Dentistry. https://doi.org/10.1016/j.jdent.2024.105063.

[27] Lin, S., Hao, X., Liu, Y., Yan, D., Liu, J., et al. (2023). Lightweight deep learning methods for panoramic dental X-ray image segmentation. Neural Computing and Applications, 35, 8295–8306. https://doi.org/10.1007/s00521-022-08102-7.

[28] Choi, E., Pang, K., Jeong, E., Lee, S., Son, Y., & Seo, M.-S. (2023). Artificial intelligence in diagnosing dens evaginatus on periapical radiography with limited data availability. Scientific Reports, 13, 13232. https://doi.org/10.1038/s41598-023-40472-3.

[29] Hartoonian, S., Hosseini, M., Yousefi, I., Mahdian, M., & Ghazizadeh Ahsaie, M. (2024). Applications of artificial intelligence in dentomaxillofacial imaging: A systematic review. Oral Surgery, Oral Medicine, Oral Pathology and Oral Radiology, 138(5), 641–655. https://doi.org/10.1016/j.oooo.2023.12.790.

[30] Deep learning framework for analysis of health factor in Internet-of-Medical Things." Radioelectronics and Communications Systems, Springer, Scopus Q3, 2023. DOI: 10.3103/S0735272723030056.

[31] Math, S. Y., Ameli, N., Stefani, C. M., Kung, J. Y., Punithakumar, K., Amin, M., & Pacheco-Pereira, C. (2025). Augmented intelligence in oral and maxillofacial radiology: A systematic review. Oral Surgery, Oral Medicine, Oral Pathology and Oral Radiology, 140(2), 237–250. https://doi.org/10.1016/j.oooo.2025.03.015.

[32] Tasdemir, T., Tassoker, M., Arpacı, A., Kula, A., Kocabiyik, F. E., İyişenyürek, M. E., & Hakli, H. (2026). Diagnostic performance of artificial intelligence in periapical radiography: A systematic review. Odontology. https://doi.org/10.1007/s10266-026-01401-8.

[33] Tyagi, M., Jain, S., Ranjan, M., Hassan, S., Prakash, N., Kumar, D., Kumar, A., & Singh, S. (2025). Artificial Intelligence Tools in Dentistry: A Systematic Review on Their Application and Outcomes. Cureus, 17(5), e85062. https://doi.org/10.7759/cureus.85062.

[34] Büttner, M., et al. (2024). Conquering class imbalances in deep learning-based segmentation of dental radiographs with different loss functions. Journal of Dentistry, 2024, 105063. https://doi.org/10.1016/j.jdent.2024.105063.