Natural Resources for Human Health
eISSN: 2583-1194

Original Research

Received 25 July 2026
Revised 29 Aug 2026
Accepted 15 Sep 2026

Natural Resources for Human Health 2026, Vol. 6 (22s): 1443–1449

KEYWORDS:
Misdiagnosis, Tuberculosis, Behçet's Disease, Multisystem inflammation, Mucocutaneous

Behçet's Disease Masquerading as Cutaneous Tuberculosis in Al-Baha, Saudi Arabia: A Case Report of Years of Diagnostic Trajectory and Successful Long-Term Colchicine Monotherapy

Ali Mousa Mahzari[1], Mohammad Asrar Izhari[1], Saja Adil Alghamdi[1], Nora Mohammed Almshaikh[1], Jori Saeed Alghamdi[1], Shaden Abdullah Alzahrani[1], Raneem Saeed Alghamdi[1], Abdulmajeed A A Sindi[2], Mohammad Adil Shanawaz[3*] ,Lobna Saad Mohammed Abd Elmeged[4]

[1] Department of Laboratory Medicine, Faculty of Applied Medical Sciences, Al-Baha University, Al-Baha, Saudi Arabia.
[2]Department of Basic Medical Sciences, Faculty of Applied Medical Sciences, Al-Baha University, Al-Baha, Saudi Arabia.
[3*] Corresponding Author: Department of Public Health, Faculty of Applied Medical Sciences, Al-Baha University, Al-Baha, Saudi Arabia.
[4] Department of Nutrition, Applied College, Al-Baha University, Al-Makhwa, Saudi Arabia. Email: lobna@bu.edu.sa

ABSTRACT:

Background: Behçet's Disease (BD) is a chronic, relapsing multisystem inflammatory condition that was common along the historical Silk Road region, which included the Middle East. In addition to skin lesions and recurrent oral and vaginal ulcers, it can also affect the eyes, vascular, neurological, and gastrointestinal systems. Its pathophysiology, which involves immunological dysregulation, environmental factors, and genetic predisposition, is still unknown despite substantial investigation.

Problem Statement: Behçet's disease is frequently misdiagnosed, delaying adequate care, because of the heterogeneity in clinical presentation and the absence of a precise diagnostic test. Insufficient case recording in Saudi Arabia is a contributing factor to healthcare providers' lack of understanding.

Objectives: The purpose of this study is to present a clinical case of Behçet's Disease in a Saudi patient, highlight diagnostic challenges, and compare the findings to previously published data from Saudi tertiary centers in order to improve understanding of BD manifestations and management in the region.

Methodology: The method employed was a descriptive case study. We examined and assessed the patient's medical history, clinical presentation, diagnosis, and treatment results. The case was compared to results from a recent study at King Abdulaziz University to detect similarities and differences in disease progression and management.

Main Findings: The patient, a 53-year-old man, had testicular swelling, skin lesions, and recurring oral and genital ulcers. After receiving an incorrect diagnosis of cutaneous TB, he underwent several months of ineffective treatment. Behçet's disease was identified and successfully treated with colchicine after reevaluation, leading to notable clinical relief and

Natural Resources for Human Health
eISSN: 2583-1194

long-term stability. This case had similar mucocutaneous characteristics to national data, however there was no ocular involvement. Treatment decisions were impacted by the patient's liver and kidney problems, highlighting the significance of tailored care. **Conclusion:** Behçet's disease is difficult to diagnose, and this instance highlights the importance of clinical awareness for early detection. Colchicine was successful in preserving remission and managing mucocutaneous symptoms. In order to further understand BD patterns in the Middle East, the findings highlight the need for precise diagnosis, individualized therapy, and larger regional investigations.

INTRODUCTION:

Behçet's disease (BD) is a relapsing multisystem vasculitis causing recurrent oral and genital ulcers with variable ocular and systemic involvement [1]. The disorder was originally described in 1937 by the Turkish dermatologist Hulusi Behçet, who recognized the classical triad of recurrent oral ulcers, genital ulcerations, and uveitis[2]. It is categorized as a variable-vessel vasculitis, indicating that both arteries and veins of various calibers may be affected [3]. BD exhibits a distinct geographic clustering along the "Silk Road," from East Asia to the Mediterranean, with a global prevalence of 10.3 per 100,000 and marked variation between populations [4]. This pattern underscores the influence of genetic and ethnic factors on disease incidence [5]. BD typically presents in young adults with regional male predominance [3] and arises from complex interactions between genetic susceptibility and environmental triggers [6]. BD pathogenesis involves interplay between HLA-B51 positivity, environmental triggers, aberrant neutrophil activation, and Th17/Treg imbalance, driving vascular inflammation and tissue injury [7]. A strong association has been found between BD and the HLA-B51 allele, which has been linked to increased disease risk and severity in several ethnic groups [8]. Microbial triggers may provoke aberrant immune responses in genetically predisposed individuals, with heightened neutrophil and NK cell activation and elevated TNF-α and IL-17 driving vascular inflammation and tissue injury [6]. The disease's clinical heterogeneity and complicate its diagnosis and management [5]. Recurrent aphthous oral ulcers often represent the earliest sign of the disease [9]. Some individuals may also exhibit neurological, vascular, or gastrointestinal involvement, highlighting the multisystemic nature of BD which complicates the diagnostic challenges further [10]. BD has a relapsing-remitting course and no single diagnostic lab test, so diagnosis rests on clinical features and history, supported by ISG criteria [11]. Because BD ranges from mild mucocutaneous flares to life-threatening vascular or neurological complications, management must be personalized to each patient's phenotype and risk profile [12]. Colchicine, a microtubule-disrupting anti-inflammatory that inhibits neutrophil chemotaxis and activation, is first-line for mucocutaneous BD, reducing oral and genital ulcers and erythema nodosum-like lesions[13]. Colchicine is first-line systemic therapy for non-organ-threatening BD due to its favorable safety profile and long-standing use in neutrophil-mediated diseases [7]. Colchicine alone is often inadequate for severe ocular, vascular, or neurologic BD, where escalation to immunosuppressants or biologics is frequently needed [14]. Therefore, this case report describes a patient's presentation, diagnostic course, treatment, and follow-up to add real-world evidence on managing multisystem Behçet's disease.

Case presentation

A 53-year-old man has been experiencing recurrent symptoms since 2008. His condition began with painful skin lesions affecting the hands, feet, and axillary areas, along with oral and genital ulcers that recurred approximately every two weeks. At the onset of his illness, cutaneous tuberculosis was suspected, and he was placed on anti-tuberculosis treatment for six months without any improvement. During this period, he also developed painful testicular swelling that interfered with movement.

He later received high doses of corticosteroids, which resulted in severe hyperglycemia, leading to discontinuation of the medication. When his case was reassessed at another medical center, the initial diagnosis was found to be incorrect, and the pattern of recurring mucocutaneous lesions suggested Behçet's Disease. He was referred to Rheumatology, where the diagnosis was confirmed and treatment with colchicine was initiated. Over the following three years, he demonstrated significant improvement and stabilization of symptoms.

Currently, he continues to experience intermittent oral ulcers, mild skin rashes, and general fatigue, although his condition remains stable overall. Since he has been living with this disease for many years, regular follow-up and laboratory monitoring are essential for evaluating the prognosis and long-term course of the condition. To the best of my knowledge, presented herein

is a male patient from Al-Baha, Saudi Arabia, diagnosed with Behçet's disease, a condition with no previously documented cases in his geographical region.

DISCUSSION

This case of Behçet's Disease (BD) shows many similarities and some important differences when compared with the findings from the King Abdulaziz University (KAU) study [15]. The patient presented with recurrent oral and genital ulcers, skin lesions, and testicular swelling, which align with the typical mucocutaneous manifestations widely reported in the Saudi population, including those described in the KAU study. However, his presentation also demonstrated several unique and clinically significant aspects, such as a delay in diagnosis caused by the initial misclassification of his symptoms as cutaneous tuberculosis, leading to months of unnecessary anti-tuberculosis therapy. This contrasts with the earlier recognition seen in specialized centers like KAU, where clinical teams are more familiar with BD [15]. Additionally, the absence of ocular involvement, the presence of elevated liver enzymes, and the challenge of managing the disease in a patient with only one functional kidney further complicated his disease course, making his management more complex compared to the average BD case described in the KAU research.

Laboratory findings in this case also played a major role in shaping the treatment plan. Although there is no single diagnostic laboratory test for BD, certain lab abnormalities can provide supportive information and help clinicians determine safe and effective therapy [16]. The patient's elevated liver enzymes restricted the use of commonly prescribed immunosuppressive medications such as azathioprine or methotrexate, which may worsen liver function (Figure 1) [17]. This abnormality may have resulted from chronic inflammation, previous corticosteroid exposure, or unrelated liver conditions, but regardless of the cause, it required physicians to avoid medications with known hepatic risks [18].

Additionally, the presence of only one functioning kidney created further challenges, as some BD treatments can affect renal function. This limitation required careful selection of medications and close monitoring [19]. The patient also showed elevated platelet counts and a high lipid profile, which are common changes in chronic inflammatory disorders (Figure 2, Figure 3, Figure 4) [20]. High platelets show that inflammation is still active, and this increases the risk of thrombosis, a relevant concern since BD affects blood vessels. Similarly, lipid abnormalities may be influenced by inflammation or past steroid therapy, and monitoring these results is important because they may contribute to long- term complications [20].

Moreover, a notable difference between this case and the KAU study is the absence of ocular involvement. In the KAU cohort, a significant proportion of patients presented with eye complications such as uveitis, which can lead to serious, irreversible damage if not treated promptly. The lack of ocular manifestations in this patient may indicate a milder disease phenotype or may reflect early anti-inflammatory treatment that prevented progression [15]. This difference emphasizes the wide variability in BD expression, even among patients of similar age groups and geographic backgrounds. While some individuals develop severe systemic or ocular disease, others experience mainly mucocutaneous symptoms that remain stable with appropriate therapy.

In terms of treatment, this patient showed good long-term response to colchicine, which is commonly used for mucocutaneous BD and was also the most frequently prescribed medication in the KAU study [15]. However, most patients in the KAU cohort received combination therapy with corticosteroids or immunosuppressants when needed, whereas this patient had to rely almost entirely on colchicine because of his liver and kidney limitations. Despite the restricted treatment options, colchicine alone was effective in reducing flare-ups and maintaining relative stability for several years. His earlier use of high-dose corticosteroids temporarily improved symptoms but caused significant complications, including severe hyperglycemia, demonstrating the importance of cautious steroid use in BD management.

Overall, this case highlights several important points about Behçet's Disease in the Saudi context. First, mucocutaneous symptoms remain the strongest indicators of BD and should prompt early evaluation, especially when they are recurrent. Second, diagnosis may be delayed when clinicians are unfamiliar with the disease or when symptoms overlap with infectious conditions such as tuberculosis. Third, laboratory abnormalities including elevated platelets, high lipid levels, and impaired liver or kidney function can significantly influence treatment decisions and must be carefully assessed before selecting medications. Finally, this case demonstrates that consistent follow-up, proper interpretation of lab findings, and individualized therapy can lead to stable disease control even in patients with limited treatment options. Together, these findings reinforce the need for

improved clinical awareness and emphasize how personalized, patient-centered management can positively affect outcomes in Behçet's Disease.

CONCLUSION

Behçet's disease is a multifaceted inflammatory disorder that remains challenging to diagnose, especially in regions where awareness is limited. This case illustrates how overlapping symptoms can lead to significant delays in diagnosis and expose patients to unnecessary treatments, as seen with the initial misdiagnosis of cutaneous tuberculosis. Once the correct diagnosis was established, tailored management using colchicine successfully controlled the patient's mucocutaneous symptoms despite his liver and kidney restrictions, highlighting the importance of individualized therapy.

Comparison with published data from Saudi tertiary centers shows that recurrent oral and genital ulcers remain the most consistent features in local BD cases, while systemic involvement varies considerably. This emphasizes the heterogeneous nature of the disease and the need for clinicians to recognize its broad spectrum early. Overall, this case reinforces the importance of timely diagnosis, appropriate therapeutic planning, and continuous clinical follow-up to improve outcomes for patients with Behçet's disease in the Middle East.

Lessons learned from this clinical case

High index of suspicion for Behçet's disease in endemic regions with recurrent mucocutaneous ulcers. Individualized treatment selection is essential in Behçet's disease with comorbidities. Behçet's disease remains underdiagnosed in underrepresented regions like Al-Baha.

LIMITATIONS

This is a single case report from a resource-limited peripheral region with a prolonged diagnostic delay, limiting the generalizability of our findings and the characterization of systemic disease manifestations.

CONFLICT OF INTEREST

No conflict of interest

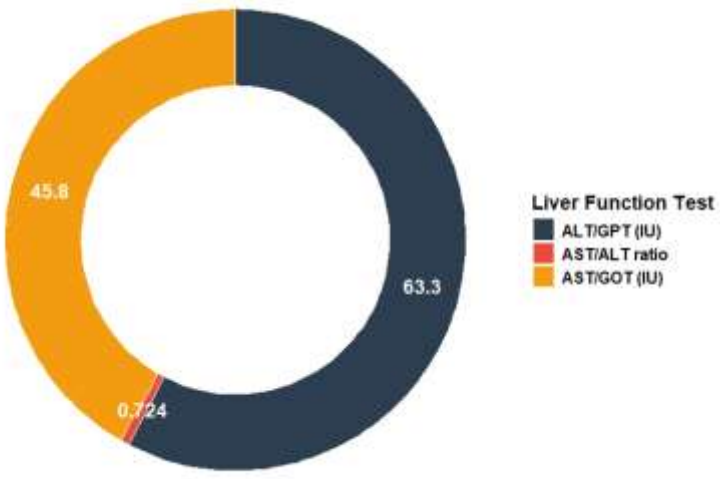

Figure 1: Liver Function Test Profile of a Behçet's Disease Patient. The chart presents the hepatic function parameters. Parameters include: ALT/GPT (Alanine Aminotransferase/Glutamic Pyruvic Transaminase), AST/ALT ratio, and AST/GOT (Aspartate Aminotransferase/Glutamic Oxaloacetic Transaminase).

Natural Resources for Human Health
eISSN: 2583-1194

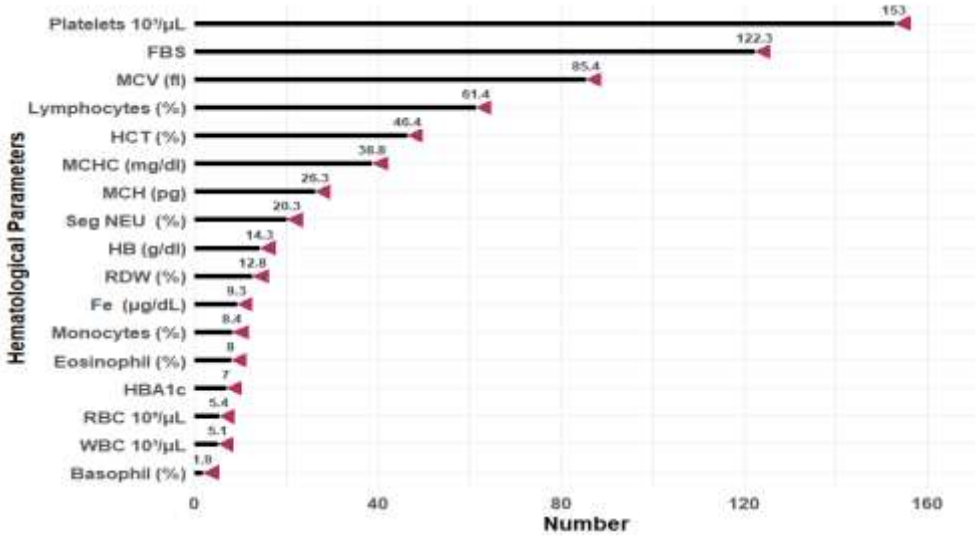

Figure 2: Clinical Profile of a Behçet's Disease Patient. The chart illustrates the hematological and biochemical profile, highlighting markers relevant to systemic involvement. Parameters include: Platelets ($10^3/\mu L$), FBS (Fasting Blood Sugar), MCV (Mean Corpuscular Volume), Lymphocytes, HCT (Hematocrit), MCHC (Mean Corpuscular Hemoglobin Concentration), MCH (Mean Corpuscular Hemoglobin), Seg NEU (Segmented Neutrophils), HB (Hemoglobin), RDW (Red Cell Distribution Width), Fe (Iron), Monocytes, Eosinophils, HBA1c (Glycated Hemoglobin), RBC (Red Blood Cells), WBC (White Blood Cells), and Basophils. These values provide a snapshot of the patient's systemic status, which is essential in managing the vasculitis and inflammatory symptoms characteristic of Behçet's Disease.

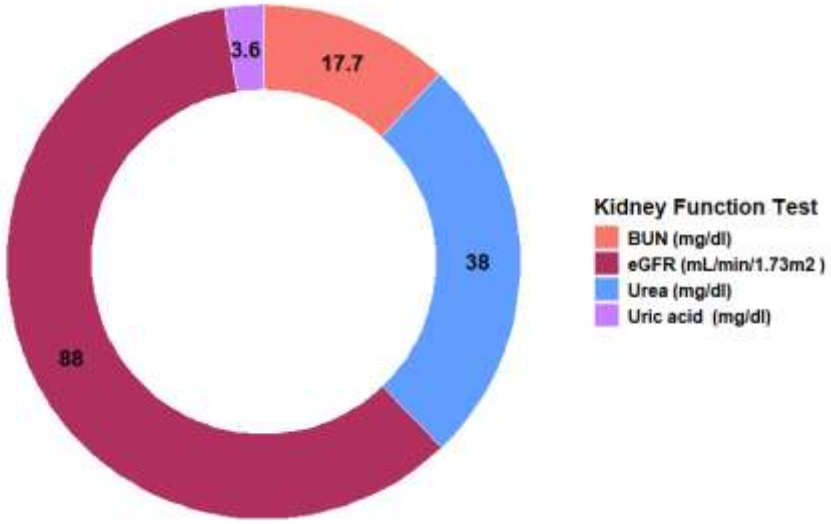

Figure 3: Kidney Function Test Profile of a Behçet's Disease Patient. The donut chart illustrates the renal function parameters. Parameters include: BUN (Blood Urea Nitrogen, mg/dL) = 17.7, eGFR (Estimated Glomerular Filtration Rate, $mL/min/1.73m^2$) = 88, Urea (mg/dL) = 38, and Uric acid (mg/dL) = 3.6.

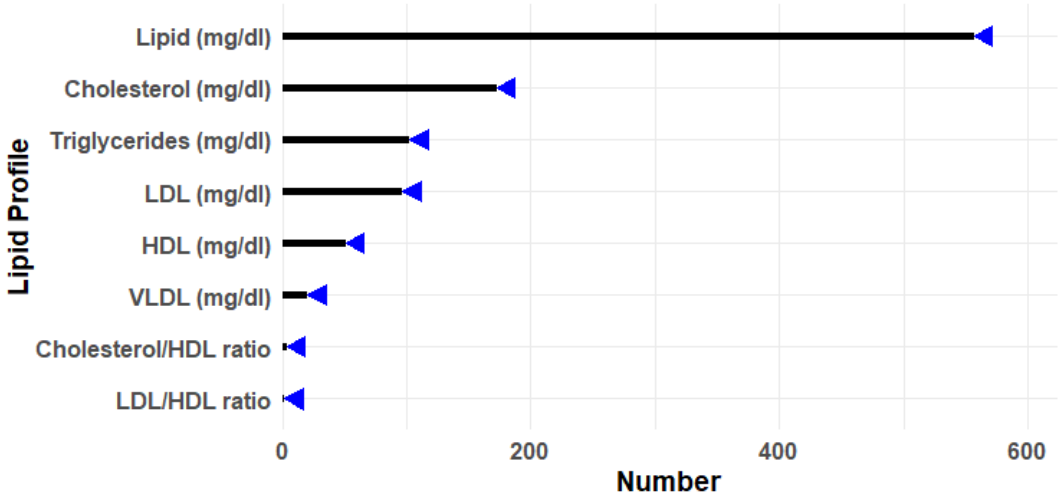

Figure 4: Lipid Profile of a Behçet's Disease Patient. The chart demonstrates the lipid metabolism parameters in a patient with Behçet's Disease. Parameters include: Lipid (mg/dL), Cholesterol (mg/dL), Triglycerides (mg/dL), LDL (Low-Density Lipoprotein, mg/dL), HDL (High-Density Lipoprotein, mg/dL), VLDL (Very Low-Density Lipoprotein, mg/dL), Cholesterol/HDL ratio, and LDL/HDL ratio.

REFERENCE:

[1] Lavalle S, Caruso S, Foti R, Gagliano C, Cocuzza S, La Via L, et al. Behçet's disease, pathogenesis, clinical features, and treatment approaches: a comprehensive review. Medicina. 2024;60(4):562.

[2] Batalli A, Liehr T, Temaj G. Behçet's disease: a comprehensive overview of symptoms, pathology, genetics, and treatment. Journal of Mother and Child. 2026;30(1):1-10.

[3] Yazici H, Seyahi E, Hatemi G, Yazici Y. Behçet syndrome: a contemporary view. Nature Reviews Rheumatology. 2018;14(2):107-19.

[4] Akkoç N. Update on the epidemiology, risk factors and disease outcomes of Behçet's disease. Best Pract Res Clin Rheumatol. 2018;32(2):261-70.

[5] Izzedine H, Jhaveri KD. Behçet's syndrome. New England Journal of Medicine. 2024;390(18):1731.

[6] Greco A, De Virgilio A, Ralli M, Ciofalo A, Mancini P, Attanasio G, et al. Behçet's disease: new insights into pathophysiology, clinical features and treatment options. Autoimmunity reviews. 2018;17(6):567-75.

[7] Alpsoy E. New Evidence-Based Treatment Approach in Behçet' s Disease. Pathology Research International. 2012;2012(1):871019.

[8] KORSANTIA N, KORSANTIA N, KATSITADZE T, BERIDZE L, KATSITADZE A, NIKURADZE N, et al. BEHCET'S DISEASE/SYNDROME–CASE REPORT AND LITERATURE REVIEW. Experimental and Clinical Medicine Georgia. 2024(5):83-9.

[9] Alibaz-Oner F, Direskeneli H. Update on the Diagnosis of Behçet's Disease. Diagnostics (Basel). 2022;13(1).

[10] Alpsoy E, Donmez L, Onder M, Gunasti S, Usta A, Karincaoglu Y, et al. Clinical features and natural course of Behçet's disease in 661 cases: a multicentre study. Br J Dermatol. 2007;157(5):901-6.

[11] Alpsoy E, Leccese P, Emmi G, Ohno S. Treatment of Behçet's disease: an algorithmic multidisciplinary approach. Frontiers in medicine. 2021;8:624795.

[12] Bozca BC, Alpsoy E. Experimental therapeutic solutions for Behcet's disease. Journal of Experimental Pharmacology. 2021:127-45.

[13] Li S, Wang L, Wang Y, Zhang C. Exploring the pharmacological and adverse reaction mechanism of a drug by network pharmacology strategy: Using colchicine to treat Behcet syndrome as an example. Medicine. 2022;102(14):e33486.

[14] Wang Z, Zu X, Xiong S, Mao R, Qiu Y, Chen B, et al. The Role of Colchicine in Different Clinical Phenotypes of Behcet Disease. Clinical Therapeutics. 2023;45(2):162-76.

[15] Bawazir Y, Mustafa M. Clinicodemographic Data of Patients with Behçet's Disease: Data from a Tertiary Center in Saudi Arabia. Current Rheumatology Reviews. 2026;22(1):94-103.

[16] Alibaz-Oner F, Direskeneli H. Update on the diagnosis of Behçet's disease. Diagnostics. 2022;13(1):41.

[17] Gisi K, Ispiroglu M, Kantarceken B, Sayar H. Severe cholestasis due to azathioprine in Behcet's disease. BMJ Case Reports. 2019;12(3):e226340.

[18] Conway R, Carey JJ. Risk of liver disease in methotrexate treated patients. World Journal of Hepatology. 2017;9(26):1092.

[19] Bouomrani S, Regaïeg N, Nefoussi M, Trabelsi S. Acute interstitial nephritis due to Ciclosporin a toxicity during Behçet's disease. Med Case Rep Rev. 2019;2:1-2.

[20] Yücel Ç, Omma A, Sertoğlu E, Sezer S, Turhan T, Özgürtaş T. Evaluation of atherogenic laboratory markers in Behçet's disease patients with vascular involvement. Archives of Medical Science. 2020;16(3):531-7.