Natural Resources for Human Health

eISSN: 2583-1194

Original Research

Received 22 July 2026
Revised 24 Aug 2026
Accepted 05 Sep 2026

Natural Resources for Human Health 2026, Vol. 6 (22s): 1350–1361

KEYWORDS:
Celiac disease; Anti-tissue transglutaminase antibodies; Intercellular adhesion molecule-1; Vascular cell adhesion molecule-1; Duodenal histopathology; Modified Marsh classification

Correlation Between IgA and IgG Tissue Transglutaminase Antibodies and Circulating ICAM-1, VCAM-1, and Histopathological Findings in Patients with Celiac Disease

Teba Khalid Akeeb[1], Hadi Rasool Hassan[2]

[1,2]Teba Khalid.College of Applied Medical Sciences, University of Karbala, Karbala, Iraq
*Corresponding Author Email: tiba.kh@s.uokerbala.edu.iq

ABSTRACT: This study examined serum intercellular adhesion molecule-1 (ICAM-1), vascular cell adhesion molecule-1 (VCAM-1), and anti-tissue transglutaminase (anti-tTG) IgA and IgG concentrations across duodenal histopathological categories in individuals investigated for suspected celiac disease. Ninety participants were recruited at Marjan Hospital, Babylon Governorate, Iraq, between August 1 and December 1, 2024. Serum biomarkers were measured using enzyme-linked immunosorbent assays, and duodenal biopsies were independently assessed by two pathologists blinded to serological findings using the modified Marsh classification. Mean anti-tTG IgA and IgG concentrations increased across Marsh categories, reaching their highest values in Marsh 3. ICAM-1 concentrations increased progressively, with significant elevations in Marsh 2 and Marsh 3 compared with Marsh 0. VCAM-1 concentrations were significantly elevated in Marsh 3 compared with Marsh 0, whereas comparisons of Marsh 1 and Marsh 2 with Marsh 0 were nonsignificant. Histopathological findings included preserved villous architecture, increased intraepithelial lymphocytes, crypt hyperplasia, and total villous atrophy in the reported Marsh 3 specimens. Females constituted 68.9% of participants and males 31.1%. These exploratory findings indicate differences in circulating biomarker concentrations across histopathological categories. However, the absence of total serum IgA measurements, participant-level correlation analyses, and diagnostic-performance assessment limits interpretation. Further studies are required to determine whether ICAM-1 and VCAM-1 provide clinically useful information beyond established serological and histopathological evaluation.

1. INTRODUCTION

Celiac disease (CD) is a chronic, immune-mediated disorder triggered by gluten ingestion in genetically susceptible individuals. It is characterized by disease-specific autoantibodies and variable small-intestinal mucosal injury, with manifestations ranging from gastrointestinal symptoms and malabsorption to anemia, nutritional deficiencies, and extraintestinal complications. Its heterogeneous presentation requires an integrated diagnostic approach incorporating clinical assessment, serological testing, and, where indicated, duodenal histopathology. Contemporary guidelines also emphasize the importance of accurate diagnosis before initiating a gluten-free diet, which remains the principal treatment [1-3].

The immunopathogenesis of CD involves interactions among gluten-derived antigens, tissue transglutaminase 2 (TG2), disease-associated HLA molecules, and intestinal immune cells. Identification of TG2 as the principal endomysial autoantigen established the biological basis for anti-tissue transglutaminase antibody testing [4]. TG2-mediated deamidation facilitates the presentation of gluten peptides to gluten-reactive $CD4^+$ T cells through HLA-DQ2 or HLA-DQ8. However, adaptive immune activation alone does not fully explain epithelial destruction. Experimental work demonstrated that gluten exposure, HLA-DQ8

expression, and increased intestinal interleukin-15 activity act together to produce villous atrophy, highlighting the interaction between antigen-specific immunity and epithelial inflammatory signals [5].

Recent therapeutic and molecular studies further support the central role of TG2 in gluten-induced mucosal injury. In a randomized clinical trial, the selective TG2 inhibitor ZED1227 attenuated duodenal damage during a controlled gluten challenge [6]. Subsequent investigation demonstrated accumulation of the inhibitor-TG2 complex predominantly within villous enterocytes, suggesting that inhibition can occur at the epithelial interface [7]. Transcriptomic analysis subsequently showed that TG2 inhibition preserved molecular signatures associated with epithelial differentiation, mucosal architecture, and nutrient absorption while limiting gluten-induced inflammatory responses [8]. These findings strengthen the mechanistic connection between gluten processing, immune activation, and intestinal tissue injury.

The intestinal response in CD also involves complex interactions among immune, epithelial, and stromal populations. Using single-cell and spatial transcriptomics, FitzPatrick et al. identified interferon-associated epithelial changes, altered lymphocyte populations, and distinct inflammatory tissue niches in intestinal biopsies [9]. Some abnormalities persisted despite treatment, indicating that conventional histological categories do not capture every aspect of the mucosal response. These observations provide a biological rationale for investigating complementary biomarkers that reflect inflammatory activity alongside established serological and histopathological measurements.

Serological assessment primarily relies on IgA antibodies against tissue transglutaminase (anti-tTG IgA), interpreted alongside total serum IgA. IgG-based assays have particular diagnostic relevance in individuals with IgA deficiency, although their interpretation depends on the assay and clinical context [2,10]. Prospective pediatric research and studies across adult cohorts have demonstrated that markedly elevated anti-tTG IgA concentrations can identify patients with a high probability of CD under defined conditions [11,12]. These findings underpin guideline-supported pathways that permit diagnosis without biopsy in selected patients; nevertheless, such pathways require specific eligibility criteria and should not be generalized to all individuals undergoing investigation [2,3,10].

Duodenal histopathology provides direct evidence of mucosal injury through assessment of intraepithelial lymphocytes, crypt architecture, and villous morphology. Previous clinical research has examined relationships among serum antibody concentrations, mucosal damage, and clinical presentation, supporting their combined evaluation rather than reliance on a single measurement [13]. Histological interpretation also depends on adequate specimen orientation and reproducible assessment. Validation studies have demonstrated the utility of quantitative measurements, including the villous height-to-crypt depth ratio and intraepithelial lymphocyte density, for detecting changes in intestinal morphology [14]. The modified Marsh classification remains widely used, with Marsh 3 encompassing partial, subtotal, or total villous atrophy rather than exclusively complete villous destruction [2].

Cell adhesion molecules represent another component of the inflammatory response that may complement these established measurements. Intercellular adhesion molecule-1 (ICAM-1) contributes to interactions between leukocytes and endothelial cells, while vascular cell adhesion molecule-1 (VCAM-1) supports the recruitment of mononuclear leukocytes to activated endothelium. Recent experimental work demonstrated that inflammatory stimulation and transendothelial migration can increase ICAM-1 expression in human neutrophils [15]. Foundational functional studies also showed that endothelial INCAM-110, subsequently recognized as VCAM-1, supports lymphocyte adhesion through a mechanism distinct from ICAM-1-dependent adhesion [16]. Together, these findings support the involvement of adhesion molecules in inflammatory-cell recruitment while indicating that ICAM-1 and VCAM-1 need not display identical patterns of regulation.

Evidence specifically linking adhesion molecules to CD includes both tissue-based investigations and circulating biomarker studies. Sturgess et al. investigated altered ICAM-1 expression in jejunal biopsies from patients with CD [17]. In a separate experimental model involving rectal gluten challenge, Ensari et al. observed increased VCAM-1 and endothelial leukocyte adhesion molecule-1 expression, whereas ICAM-1 expression remained unchanged over the observation period [18]. Although rectal challenge findings cannot be directly equated with circulating concentrations or duodenal Marsh categories, they demonstrate that adhesion-molecule responses can differ according to the molecule examined, tissue compartment, and timing of antigen exposure.

Circulating measurements provide additional clinical evidence. Jelínková et al. reported higher serum soluble ICAM-1 concentrations in active CD than in treated patients and healthy controls [19]. Comba et al. subsequently found elevated circulating ICAM-1 and VCAM-1 concentrations in children with newly diagnosed CD compared with controls; VCAM-1

concentrations were also lower in patients fully adhering to a gluten-free diet than in newly diagnosed patients [20]. These observations support further investigation of adhesion molecules as indicators of disease-associated inflammatory activity. However, they do not establish that serum concentrations directly quantify intestinal vascular damage or can replace established diagnostic investigations.

Evaluating circulating adhesion molecules alongside anti-tTG antibodies and duodenal histopathology may help clarify their potential relevance to mucosal injury. Accordingly, this study assessed serum ICAM-1, VCAM-1, anti-tTG IgA, and anti-tTG IgG concentrations in individuals investigated for suspected celiac disease in Babylon Governorate, Iraq. The objective was to compare biomarker concentrations across modified Marsh categories and characterize their distribution in relation to the severity of duodenal histopathological abnormalities.

2. MATERIALS AND METHODS

2.1 Study Setting and Participants

This hospital-based observational study included 90 individuals of both sexes undergoing evaluation for suspected celiac disease at Marjan Hospital, Babylon Governorate, Iraq, between August 1 and December 1, 2024. The study population included children and adults referred for upper gastrointestinal endoscopy. Venous blood samples were collected before endoscopy to measure serum anti-tissue transglutaminase IgA and IgG antibodies, ICAM-1, and VCAM-1 using enzyme-linked immunosorbent assays. Six duodenal biopsy specimens were obtained from each participant, comprising two from the duodenal bulb and four from the second part of the duodenum. Two pathologists independently assessed the specimens using the modified Marsh classification while blinded to serological findings. The analysis examined biomarker concentrations across histopathological categories and their relationships with mucosal injury.

2.2 Blood Collection and Serum Preparation

A 5-mL venous blood sample was collected from each participant before upper gastrointestinal endoscopy. Following centrifugation, approximately 2 mL of serum was recovered and divided among four microcentrifuge tubes. Serum aliquots were stored at −20 °C until immunological analysis.

2.3 Immunological Measurements

Serum anti-tissue transglutaminase IgA and IgG antibodies, intercellular adhesion molecule-1 (ICAM-1), and vascular cell adhesion molecule-1 (VCAM-1) were measured using enzyme-linked immunosorbent assays. Approximately 2 mL of serum from each participant was divided among four microcentrifuge tubes and stored at −20 °C until analysis. Microplate absorbance was measured using a HumaReader HS instrument.

For each biomarker, the assay manufacturer, country of manufacture, kit name, catalog number, and lot number must be reported. Analytical specifications must include the assay format, detection limit, quantitative measurement range, required sample dilution, and reporting units. Anti-tTG IgA and IgG results require the manufacturer-defined negative, equivocal, and positive thresholds. For ICAM-1 and VCAM-1, any reference intervals must be identified as manufacturer-provided or independently established; study-group means must not be presented as reference ranges.

The laboratory procedure must specify sample preparation, reagent volumes, incubation conditions, washing steps, substrate-development time, stopping procedure, and absorbance-reading wavelength. Concentration calculations must identify the calibration method and any dilution-factor correction.

Quality-control reporting must describe the procedures actually performed, including calibration standards, reagent blanks, positive and negative controls, replicate measurements, assay-run acceptance criteria, and repeat testing. Handling of samples outside the measurement range or affected by hemolysis, lipemia, or repeated freeze–thaw cycles must also be documented. Intra-assay and inter-assay coefficients of variation should be reported where available, distinguishing laboratory measurements from manufacturer specifications.

2.4 Duodenal Biopsy Collection

Six duodenal biopsy specimens were collected from each participant during endoscopy: two from the duodenal bulb and four from the second part of the duodenum, following the center's sampling protocol.

2.5 Histopathological Assessment

Two pathologists independently evaluated the duodenal biopsies while blinded to participants' serological results. Assessment included villous architecture, crypt hyperplasia, and intraepithelial lymphocyte density. Each pathologist assigned a modified Marsh category, and concordant assessments were accepted as the final classification.

Histopathological findings were classified using the modified Marsh system. Marsh 0 was characterized by preserved villous architecture without increased intraepithelial lymphocytes. Marsh 1 showed increased intraepithelial lymphocytes with preserved villous architecture and no crypt hyperplasia, whereas Marsh 2 additionally exhibited crypt hyperplasia. Marsh 3 was characterized by villous atrophy accompanied by crypt hyperplasia and increased intraepithelial lymphocytes. The reported biopsy assessments described fewer than 20 intraepithelial lymphocytes per 100 enterocytes in Marsh 0 and more than 30 per 100 enterocytes in Marsh 1 and Marsh 2. The specimens classified as Marsh 3 exhibited total villous atrophy.

2.6 Study Variables

The principal variables were serum anti-tTG IgA, anti-tTG IgG, ICAM-1, and VCAM-1 concentrations and duodenal modified Marsh categories. Age and sex were included as demographic characteristics. The study examined biomarker concentrations across histopathological categories and their relationships with mucosal injury.

Information still required for a complete, reproducible Methods section

The following cannot be established from the manuscript:

Study population: recruitment method, eligibility criteria, sample-size justification, gluten-consumption status, and criteria confirming celiac disease.

Ethics: approving committee, approval number and date, consent procedures, and confidentiality arrangements.

Laboratory procedures: collection tubes, clotting and centrifugation conditions, storage duration, assay manufacturers and identifiers, units, cutoffs, calibration, quality controls, and whether total IgA was measured.

Histopathology: fixation, processing, section thickness, staining, lymphocyte-counting procedure, handling of discordant readings, and classification when biopsy sites differed.

2.7 Ethical approval

The study was approved by University of Kerbala, under approval number 5464, dated Feb. 2024. Written informed consent was obtained from all adult participants before study-related procedures. For participants younger than 18 years, written consent was obtained from a parent or legal guardian, with age-appropriate assent where applicable. Participation was voluntary, and declining or withdrawing from the study did not affect access to clinical care. Participant confidentiality was maintained by assigning study identification codes and restricting access to identifiable information to authorized research personnel.

3. RESULTS AND DISCUSSION

3.1 Age and Sex Distribution

The age distribution showed that participants aged 16-30 years represented the largest proportion of the study population (43.33%), followed by those aged 3-15 years (36.67%). The remaining age category accounted for 20.00% of participants (Figure 1). These findings demonstrate that individuals undergoing investigation for suspected celiac disease included both children and adults. However, the distribution describes the recruited hospital population and does not establish age-specific disease prevalence in Babylon Governorate.

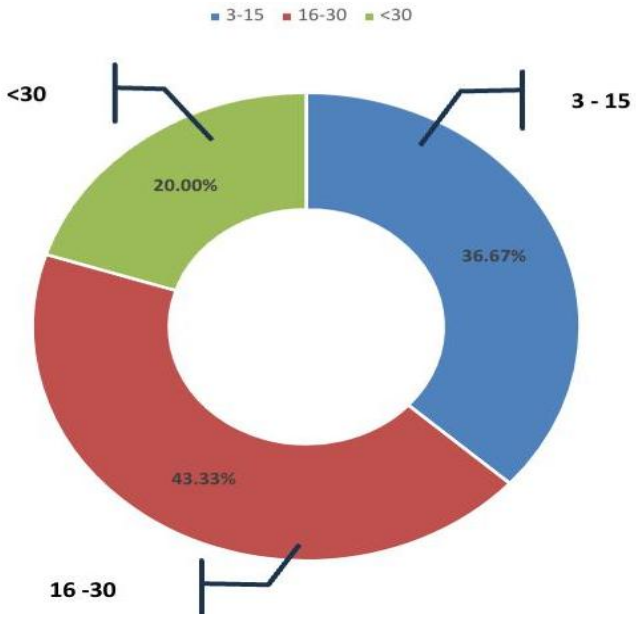

Figure 1. Age distribution of the study participants.

Females constituted 68.9% of participants and males 31.1%, yielding a female-to-male ratio of approximately 2.2:1 (Figure 2). This predominance describes the composition of the hospital-based cohort and does not establish a higher incidence of celiac disease among females. In the absence of population-based recruitment and sex-specific denominators, the observed distribution may also reflect differences in clinical presentation, healthcare-seeking behavior, and referral practices.

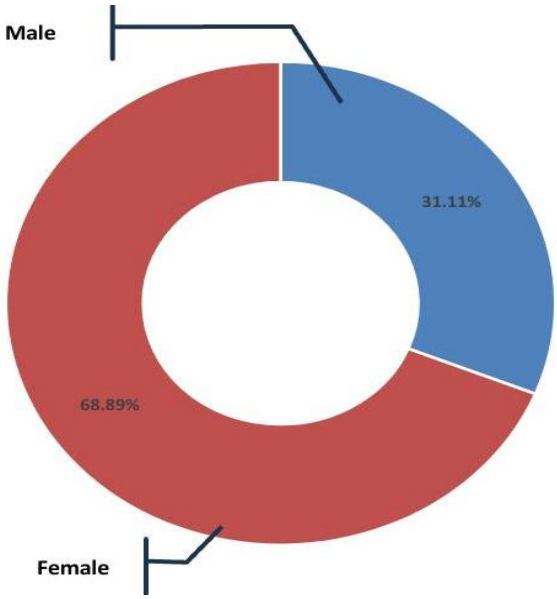

Figure 2. Sex distribution of the study participants.

3.2 Anti-Tissue Transglutaminase Antibodies Across Histopathological Categories

Mean anti-tTG IgA and IgG concentrations increased across the modified Marsh categories (Figure 3). Mean anti-tTG IgA values were 8.206, 11.385, 41.958, and 59.001 in Marsh 0, Marsh 1, Marsh 2, and Marsh 3, respectively. The corresponding anti-tTG IgG values were 12.464, 26.608, 40.003, and 60.619. Both antibody classes therefore showed their highest mean concentrations in the group with villous atrophy.

Natural Resources for Human Health
eISSN: 2583-1194

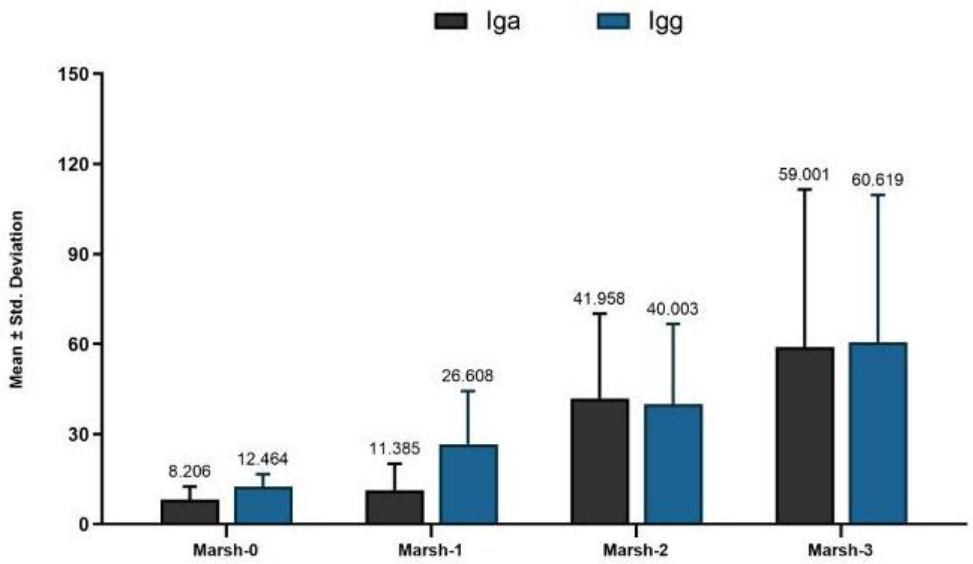

Figure 3. Serum anti-tissue transglutaminase IgA and IgG concentrations across modified Marsh histopathological categories. Bars represent means, and error bars indicate standard deviations.

The increase in antibody concentrations alongside more pronounced histopathological abnormalities supports their joint evaluation when characterizing celiac-associated mucosal injury. Previous research has examined relationships among antibody titers, mucosal damage, and clinical presentation [13]. Moreover, pediatric and adult diagnostic studies have demonstrated that markedly elevated anti-tTG IgA concentrations can identify individuals with a high probability of celiac disease under defined diagnostic conditions [11,12].

Nevertheless, the group-level pattern in Figure 3 does not establish a statistically significant correlation between antibody concentrations and Marsh category. The figure contains substantial variability, particularly in Marsh 3, and does not provide correlation coefficients or significance annotations for antibody comparisons. Anti-tTG IgA and IgG values also require interpretation against their respective assay-specific units and thresholds; their numerical magnitudes should not be treated as directly interchangeable measures of immune activity. Current guidelines prioritize anti-tTG IgA with total serum IgA, while IgG-based assays have particular relevance in IgA deficiency [2,10].

3.3 Duodenal Histopathological Findings

The reported biopsy findings encompassed preserved mucosal architecture, intraepithelial lymphocytic infiltration, crypt hyperplasia, and villous atrophy, as summarized in Table 1 and illustrated in Figures 4-7.

The Marsh 0 biopsy showed preserved villous architecture, a normal villus-to-crypt relationship, and no reported increase in intraepithelial lymphocytes (Figure 4). The Marsh 1 biopsy exhibited increased intraepithelial lymphocytes with preserved villous architecture and no crypt hyperplasia (Figure 5). The Marsh 2 biopsy showed increased intraepithelial lymphocytes and crypt hyperplasia without villous atrophy (Figure 6). The biopsy classified as Marsh 3 demonstrated total villous atrophy, crypt hyperplasia, and increased intraepithelial lymphocytes (Figure 7).

Table 1. Histopathological characteristics of duodenal biopsies according to the modified Marsh classification.

Histological changes	Marsh 0	Marsh 1	Marsh 2	Marsh 3
Endoscope result	negative	negative	positive	
histological changes	Normal villi	Infiltrative lesion	Intraepithelial Crypt	Total villous Atrophy

Lymphocytes	Normal	Increase	Increase	Increase
IELs count	<20/100	>30/100	>30/100	Total
Villus change	No change	No change	Enteritis starts with Crypt Hyperplasia	Positive

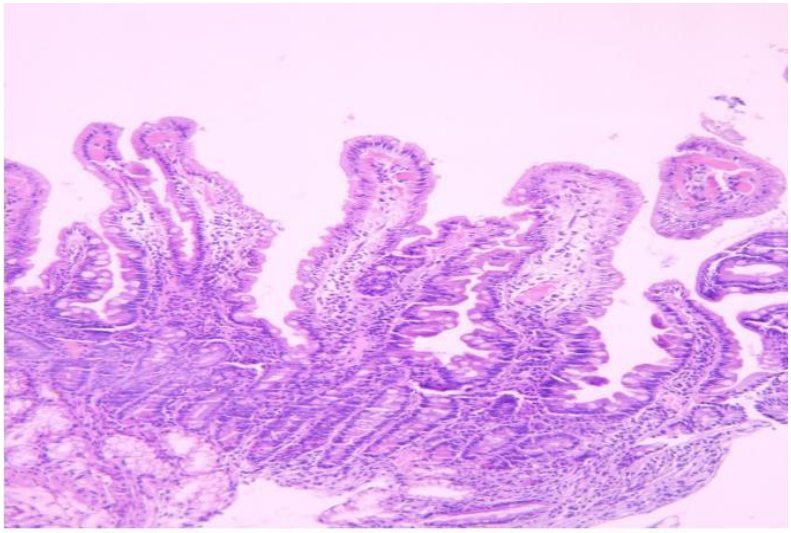

Figure 4. Representative duodenal biopsy classified as Marsh 0, showing preserved villous architecture without crypt hyperplasia or increased intraepithelial lymphocytes (10× objective).

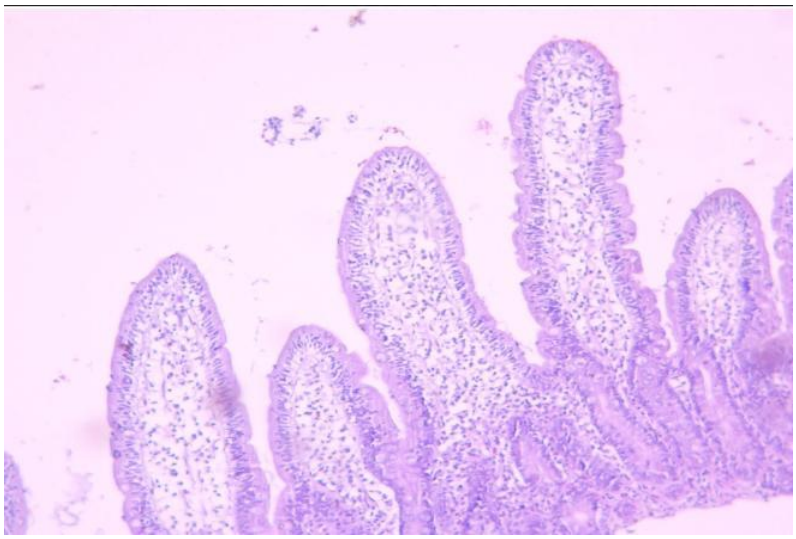

Figure 5. Representative duodenal biopsy classified as Marsh 1, showing preserved villous architecture and increased intraepithelial lymphocytes without crypt hyperplasia (10× objective).

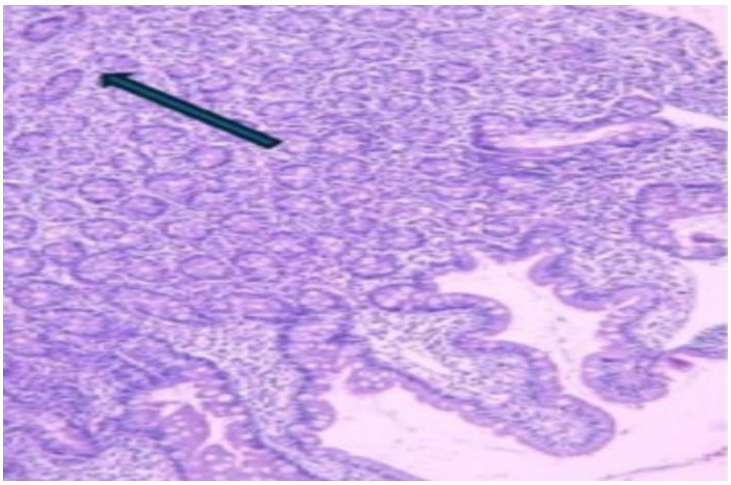

Figure 6. Representative duodenal biopsy classified as Marsh 2, showing crypt hyperplasia and increased intraepithelial lymphocytes with preserved villous architecture (10× objective).

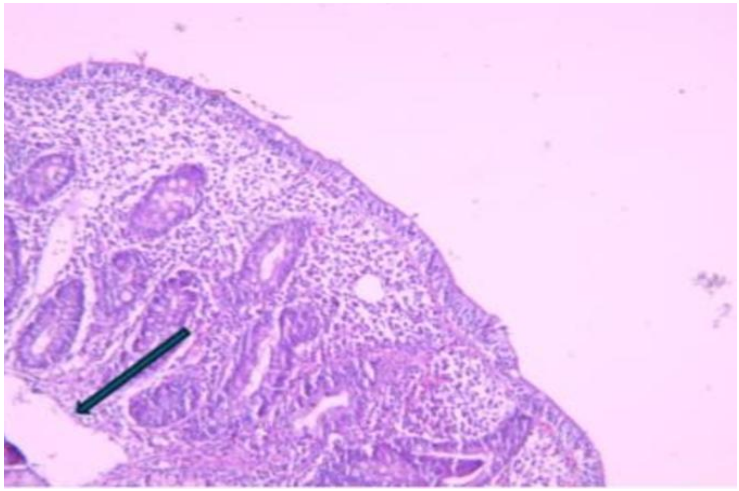

Figure 7. Representative duodenal biopsy showing total villous atrophy, crypt hyperplasia, and increased intraepithelial lymphocytes, consistent with Marsh 3c (10× objective).

These findings demonstrate distinct categories of mucosal injury within the sampled population. They should not be interpreted as longitudinal progression in individual participants, because the study did not document serial biopsies. Furthermore, total villous atrophy represents the Marsh 3c subtype when the modified Marsh subdivisions are applied; Marsh 3 more broadly includes partial, subtotal, and total villous atrophy [2].

Histopathological findings provide a structural context for interpreting circulating biomarker concentrations. Reliable classification requires adequate biopsy sampling, proper specimen orientation, and consistent assessment of villous architecture and intraepithelial lymphocyte density. Standardized morphometric measurements, including the villous height-to-crypt depth ratio and quantitative lymphocyte counts, can improve reproducibility [14]. Histological findings should therefore be interpreted alongside serological and clinical evidence, particularly in cases with preserved villous architecture or mild mucosal abnormalities [2]. Formal interobserver agreement and standardized quantitative lymphocyte assessment should be incorporated into future studies.

3.4 ICAM-1 Across Histopathological Categories

Mean serum ICAM-1 concentrations increased progressively from 419.960 in Marsh 0 to 528.843 in Marsh 1, 614.422 in Marsh 2, and 753.737 in Marsh 3 (Figure 8). According to the displayed significance annotations, the difference between Marsh 0 and Marsh 1 was nonsignificant, whereas Marsh 2 and Marsh 3 differed significantly from Marsh 0. The figure does not establish significant differences between every pair of adjacent categories.

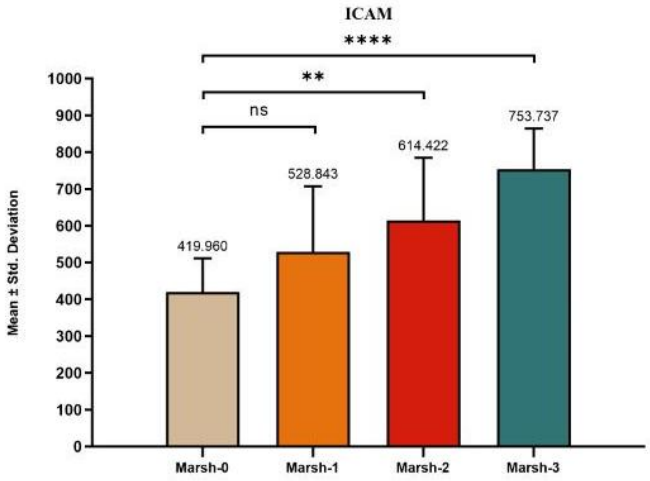

Figure 8. Serum ICAM-1 concentrations across modified Marsh histopathological categories. Bars represent means, and error bars indicate standard deviations. Brackets identify comparisons with Marsh 0; ns indicates a nonsignificant difference.

The numerical increase suggests that circulating ICAM-1 may reflect inflammatory activity accompanying more pronounced mucosal injury. This interpretation is consistent with Jelínková et al., who reported higher circulating soluble ICAM-1 concentrations in active celiac disease than in treated patients and healthy controls [19]. Comba et al. likewise reported elevated ICAM-1 concentrations in children with newly diagnosed celiac disease compared with controls [20].

A biological rationale is provided by the involvement of ICAM-1 in inflammatory-cell interactions and migration. Recent experimental work demonstrated increased ICAM-1 expression in human neutrophils following inflammatory stimulation and transendothelial migration [15]. However, this mechanistic evidence does not establish the cellular source of circulating ICAM-1 in the present participants. Serum measurements cannot distinguish contributions from intestinal tissue, circulating leukocytes, or other vascular and inflammatory compartments.

3.5 VCAM-1 Across Histopathological Categories

VCAM-1 displayed a different pattern from ICAM-1. Mean concentrations were similar in Marsh 0, Marsh 1, and Marsh 2, at 33.626, 34.333, and 34.736, respectively, before increasing to 46.934 in Marsh 3 (Figure 9). The displayed comparisons indicated nonsignificant differences between Marsh 0 and either Marsh 1 or Marsh 2, whereas Marsh 3 differed significantly from Marsh 0.

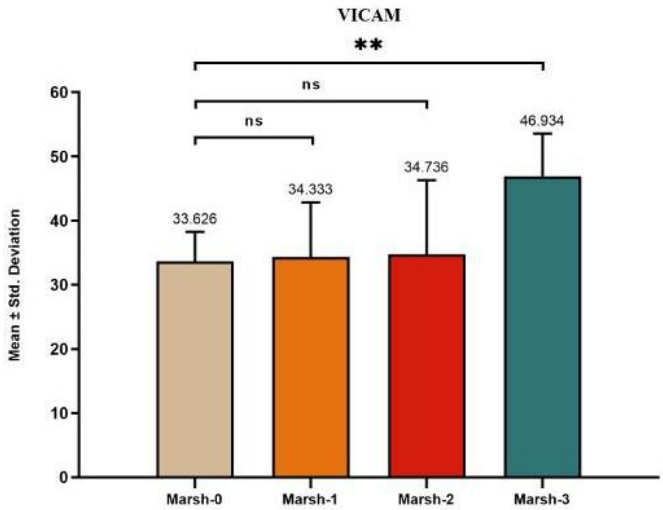

Figure 9. Serum VCAM-1 concentrations across modified Marsh histopathological categories. Bars represent means, and error bars indicate standard deviations. Brackets identify comparisons with Marsh 0; ns indicates a nonsignificant difference.

This pattern suggests that the clearest VCAM-1 elevation occurred in the group with villous atrophy. Nevertheless, the figure does not establish a biological threshold or demonstrate significant differences between Marsh 3 and every other category. The result is consistent with previous clinical evidence of elevated circulating VCAM-1 in newly diagnosed celiac disease [20]. Experimental gluten-challenge research also demonstrated increased tissue VCAM-1 expression, although that study assessed rectal mucosa rather than circulating concentrations or duodenal histopathological categories [18].

The difference between the ICAM-1 and VCAM-1 profiles may reflect distinct regulation or contributions from different inflammatory compartments. This remains an interpretation requiring further investigation. An elevated serum VCAM-1 concentration alone does not demonstrate intestinal vascular destruction, because the present study did not directly assess vascular injury or tissue-specific VCAM-1 expression.

3.6 Integrated Interpretation and Study Limitations

Figures 3-5, Table 1, and Pictures 1-4 indicate that higher mean anti-tTG antibody and ICAM-1 concentrations accompanied greater histopathological severity, whereas VCAM-1 showed its clearest elevation in Marsh 3. These findings support further investigation of complementary biomarkers but do not establish participant-level correlations or diagnostic utility.

Single-center recruitment, the absence of longitudinal measurements, and potential confounding limit interpretation. Total serum IgA was not measured, preventing identification of IgA deficiency and complicating anti-tTG IgA interpretation; anti-tTG IgG testing did not eliminate this uncertainty. Larger longitudinal studies incorporating total IgA assessment, adjusted correlation analyses, diagnostic-performance evaluation, and complete statistical reporting are required to establish clinical value.

3.7 Quantitative Comparison

Mean serum biomarker concentrations across modified Marsh categories are summarized in Table 2. Anti-tTG IgA increased from 8.206 in Marsh 0 to 59.001 in Marsh 3, while anti-tTG IgG increased from 12.464 to 60.619. ICAM-1 increased progressively from 419.960 to 753.737. In contrast, VCAM-1 showed relatively similar mean concentrations in Marsh 0–2, followed by a higher value of 46.934 in Marsh 3.

Table 2. Reported mean serum biomarker concentrations across modified Marsh histopathological categories.

Biomarker	Marsh 0	Marsh 1	Marsh 2	Marsh 3
Anti-tTG IgA	8.206	11.385	41.958	59.001
Anti-tTG IgG	12.464	26.608	40.003	60.619
ICAM-1	419.96	528.843	614.422	753.737
VCAM-1	33.626	34.333	34.736	46.934

The significance annotations in Figure 4 identify differences between Marsh 0 and both Marsh 2 and Marsh 3 for ICAM-1, whereas the comparison between Marsh 0 and Marsh 1 is nonsignificant. In Figure 5, VCAM-1 differs significantly between Marsh 0 and Marsh 3; comparisons of Marsh 0 with Marsh 1 and Marsh 2 are nonsignificant. These annotations do not establish significant differences between every pair of categories. Figure 3 shows increasing antibody concentrations but does not provide inferential statistics for these comparisons.

4. CONCLUSION

The main conclusions of this study can be summarized as follows:

1. Mean serum anti-tTG IgA and IgG concentrations increased across modified Marsh categories, with the highest values observed in Marsh 3.
2. Serum ICAM-1 concentrations increased progressively, with significant elevations in Marsh 2 and Marsh 3 compared with Marsh 0.

3. Serum VCAM-1 concentrations were significantly elevated in Marsh 3 compared with Marsh 0, whereas differences between Marsh 0 and either Marsh 1 or Marsh 2 were nonsignificant.
4. Circulating ICAM-1 and VCAM-1 may provide complementary information about inflammatory activity associated with duodenal mucosal injury.
5. Larger longitudinal studies incorporating correlation analyses and diagnostic-performance assessment are needed to establish the clinical value of these biomarkers.

REFERENCES

[1] Rubio-Tapia, A., Hill, I. D., Semrad, C., Kelly, C. P., & Lebwohl, B. (2023). American College of Gastroenterology guidelines update: Diagnosis and management of celiac disease. *The American Journal of Gastroenterology, 118*(1), 59-76. https://doi.org/10.14309/ajg.0000000000002075

[2] Al-Toma, A., et al. (2025). European Society for the Study of Coeliac Disease 2025 updated guidelines on the diagnosis and management of coeliac disease in adults. Part 1: Diagnostic approach. *United European Gastroenterology Journal, 13*(10), 1855-1886. https://doi.org/10.1002/ueg2.70119

[3] Penny, H. A., et al. (2026). The 2026 British Society of Gastroenterology guidelines on the diagnosis and management of adult coeliac disease. *Gut*. Published online. https://doi.org/10.1136/gutjnl-2025-337747

[4] Dieterich, W., Ehnis, T., Bauer, M., Donner, P., Volta, U., Riecken, E. O., & Schuppan, D. (1997). Identification of tissue transglutaminase as the autoantigen of celiac disease. *Nature Medicine, 3*(7), 797-801. https://doi.org/10.1038/nm0797-797

[5] Abadie, V., et al. (2020). IL-15, gluten and HLA-DQ8 drive tissue destruction in coeliac disease. *Nature, 578*, 600-604. https://doi.org/10.1038/s41586-020-2003-8

[6] Schuppan, D., et al. (2021). A randomized trial of a transglutaminase 2 inhibitor for celiac disease. *The New England Journal of Medicine, 385*(1), 35-45. https://doi.org/10.1056/NEJMoa2032441

[7] Isola, J., et al. (2023). The oral transglutaminase 2 inhibitor ZED1227 accumulates in the villous enterocytes in celiac disease patients during gluten challenge and drug treatment. *International Journal of Molecular Sciences, 24*(13), 10815. https://doi.org/10.3390/ijms241310815

[8] Dotsenko, V., et al. (2024). Transcriptomic analysis of intestine following administration of a transglutaminase 2 inhibitor to prevent gluten-induced intestinal damage in celiac disease. *Nature Immunology, 25*, 1218-1230. https://doi.org/10.1038/s41590-024-01867-0

[9] FitzPatrick, M. E. B., et al. (2025). Immune-epithelial-stromal networks define the cellular ecosystem of the small intestine in celiac disease. *Nature Immunology, 26*, 947-962. https://doi.org/10.1038/s41590-025-02146-2

[10] Husby, S., et al. (2020). European Society Paediatric Gastroenterology, Hepatology and Nutrition guidelines for diagnosing coeliac disease 2020. *Journal of Pediatric Gastroenterology and Nutrition, 70*(1), 141-156. https://doi.org/10.1097/MPG.0000000000002497

[11] Werkstetter, K. J., et al. (2017). Accuracy in diagnosis of celiac disease without biopsies in clinical practice. *Gastroenterology, 153*(4), 924-935. https://doi.org/10.1053/j.gastro.2017.06.002

[12] Penny, H. A., et al. (2021). Accuracy of a no-biopsy approach for the diagnosis of coeliac disease across different adult cohorts. *Gut, 70*(5), 876-883. https://doi.org/10.1136/gutjnl-2020-320913

[13] Taavela, J., et al. (2013). Degree of damage to the small bowel and serum antibody titers correlate with clinical presentation of patients with celiac disease. *Clinical Gastroenterology and Hepatology, 11*(2), 166-171.e1. https://doi.org/10.1016/j.cgh.2012.09.030

[14] Taavela, J., et al. (2013). Validation of morphometric analyses of small-intestinal biopsy readouts in celiac disease. *PLOS ONE, 8*(10), e76163. https://doi.org/10.1371/journal.pone.0076163

[15] Vignarajah, M., Wood, A. J. T., Nelmes, E., Subburayalu, J., Herre, J., Nourshargh, S., Summers, C., Chilvers, E. R., & Farahi, N. (2024). Regulation of ICAM-1 in human neutrophils. *Journal of Leukocyte Biology, 116*(4), 901-908. https://doi.org/10.1093/jleuko/qiae090

[16] Rice, G. E., Munro, J. M., & Bevilacqua, M. P. (1990). Inducible cell adhesion molecule 110 (INCAM-110) is an endothelial receptor for lymphocytes. A CD11/CD18-independent adhesion mechanism. *The Journal of Experimental Medicine, 171*(4), 1369-1374. https://doi.org/10.1084/jem.171.4.1369

[17] Sturgess, R. P., Macartney, J. C., Makgoba, M. W., Hung, C. H., Haskard, D. O., & Ciclitira, P. J. (1990). Differential upregulation of intercellular adhesion molecule-1 in coeliac disease. *Clinical and Experimental Immunology, 82*(3), 489-492. https://doi.org/10.1111/j.1365-2249.1990.tb05477.x

[18] Ensari, A., Ager, A., Marsh, M. N., Morgan, S., & Moriarty, K. J. (1993). Time-course of adhesion molecule expression in rectal mucosa of gluten-sensitive subjects after gluten challenge. *Clinical and Experimental Immunology, 92*(2), 303-307. https://doi.org/10.1111/j.1365-2249.1993.tb03396.x

[19] Jelínková, L., Tucková, L., Sánchez, D., Krupicková, S., Pozler, O., Nevoral, J., Kotalová, R., & Tlaskalová-Hogenová, H. (2000). Increased levels of circulating ICAM-1, E-selectin, and IL-2 receptors in celiac disease. *Digestive Diseases and Sciences, 45*(2), 398-402. https://doi.org/10.1023/A:1005489316037

[20] Comba, A., et al. (2016). Assessment of endothelial dysfunction with adhesion molecules in patients with celiac disease. *Journal of Pediatric Gastroenterology and Nutrition, 63*(2), 247-252. https://doi.org/10.1097/MPG.0000000000001138.