Natural Resources for Human Health
eISSN: 2583-1194

Original Research

Received 24 July 2026
Revised 20 Aug 2026
Accepted 05 Sep 2026

Natural Resources for Human Health 2026, Vol. 6 (22s): 1147–1168

KEYWORDS:
Atopic dermatitis, sinapoyl choline, 2,4-dinitrochlorobenzene, Sinapine; Filaggrin; Mice.

Mitigative Effect of Topical Sinapine on Mouse Model of DNCB-Induced Atopic Dermatitis

Noor Ahmed Abdulredha[1], Ahmed Rahmah Abu-Raghif[2]

[1]M.Sc (Pharmacology), Al-Nahrain University, College of Medicine, Department of Pharmacology, Baghdad, Iraq.
[2]Professor, M.B.Ch.B., PhD (Pharmacology), Al-Nahrain University, College of Medicine, Department of Pharmacology, Baghdad, Iraq.

ABSTRACT: **Background:** Atopic dermatitis (AD) is a long-lasting inflammation-associated dermatosis characterized by erythematous, dry patches. Tacrolimus is a well-defined standard drug utilized to manage AD. Sinapine is a naturally occurring phenolic phytosubstance with robust anti-inflammatory and antioxidative actions.
Objective: This study intended to evaluate the ameliorative effect of sinapine in a 2,4-dinitrochlorobenzene (DNCB)-evoked murine model of AD-resembling dermatitis.
Methods: Fifty male BALB/c albino-kind mice were haphazardly assigned to 5 groups of 10 each, which included healthy control, DNCB induction, vehicle, tacrolimus 0.1%, and sinapine 1% groups. Except for the healthy control group, atopic dermatitis was induced by sensitization with 1% DNCB, followed by repeated challenges with 0.5% DNCB. Mice were treated topically once daily for 3 weeks with vehicle cream, 0.1% tacrolimus ointment, and 1% sinapine cream. The clinical severity of dermatitis was determined along with histopathological investigation and filaggrin immunohistochemistry testing. Serum immunoglobulin E (IgE), levels of cutaneous interleukin (IL)-4 and IL-13, malondialdehyde (MDA), and reduced glutathione (GSH) were tested by ELISA.
Results: Topical sinapine improved histopathological changes and significantly decreased clinical dermatitis scores versus the DNCB-induction group. Immunohistochemical analysis revealed that the treated mice showed increased filaggrin expression. Additionally, sinapine significantly reduced serum IgE and skin tissue IL-4, IL-13, and malondialdehyde (MDA) levels and restored reduced glutathione (GSH) levels, as demonstrated by enzyme-linked immunosorbent assay.
Conclusion: Topical application of sinapine relieves DNCB-induced AD-like symptoms through modulation of inflammatory, immunological, and oxidative parameters and up-regulation of filaggrin expression. These results provide preclinical evidence for the possible therapeutic value of sinapine for further investigation in atopic dermatitis.

1. INTRODUCTION

Atopic dermatitis (AD) is a lifelong allergic dermatosis featured by relentless itchiness and eczematous plaques that recur [1, 2]. Sleep, education, employment, and family relationships can all be negatively impacted; visible deformity from erythema, flaking/scaling, and bleeding abrasions can lead to depression, social stigmatization, and a lower quality of life [3, 4]. AD affects about 4% of adults and 10% of children, and half of adults develop incessant cutaneous malady [5]. The skin barrier protects the body from excessive trans-epidermal water loss and from external hazards such as chemicals, allergens, and infectious agents [6, 7]. The pathophysiology of the condition is multifaceted, involving psychological factors, external triggers, impaired epidermal barrier function, oxidative stress, and immune dysregulation [8, 9]. Therapeutic management remains challenging. Topical or oral corticosteroids, systemic immunosuppressants, and biological agents are the current standard treatments [10]. Although biological agents are the most commonly recommended therapy for AD, their continued use is limited by high cost

and dose-restricting side events, such as epidermal shrinking, telangiectasia, and hyperpigmentation [11-13]. Despite the use of corticosteroid-avoiding medicines, notably cyclosporine and methotrexate, therapeutic outcomes remain suboptimal [14]. This highlights the need for safer and more sustainable treatment options [15].

The selected biomarkers were chosen for their well-established roles in the pathomechanism of AD. Serum IgE, along with IL-4 and IL-13, was measured as a key indicator of Th2-mediated immune responses and allergic inflammation, both central features of AD [16, 17]. Moreover, oxidative stress is important in the pathophysiology of long-term inflammatory dermatoses, as increased formation of reactive oxygen species (ROS), gives rise to skin barrier disruption, inflammation, and disease progression [18-20]. As a result, assessing oxidative stress indices is critical for identifying the pathomechanisms and estimating treatment efficacy [21-24]. In the current investigation, oxidative stress was assessed via determining malondialdehyde (MDA), a commonly used indicator of lipid peroxidation that reflects oxidative injury to membrane lipids [25-27]. Furthermore, reduced glutathione (GSH), a vital intrinsic antioxidant, was tested to assess cellular redox balance and antioxidant defense mechanisms to combat reactive oxygen species [28-30]. In addition, filaggrin expression was assessed by immunohistochemistry as a marker of epidermal barrier integrity, given that filaggrin deficiency is strongly associated with impaired skin barrier function in atopic dermatitis [31, 32].

Recent pharmaceutical advances, including biologic therapies targeting IL-4/IL-13 cytokines and small-molecule blockers, have underscored the significance of modulating inflammatory mechanisms while restoring barrier function. In the current context, plant-based constituents are gaining recognition as potential complements or adjunctive treatments [33, 34]. Sinapic acid is a naturally derived hydroxycinnamic acid abundant in many plants, particularly in Brassicaceae seeds [35]. It is a phenolic phytoconstituent with potent antioxidative and immune-modulating activities. A lot of research has suggested that it is a strong antioxidant [36-38]. Sinapine, also known as sinapoyl choline, is a choline ester of sinapic acid, particularly identified in the seeds of rapeseed (Brassica napus), mustard (Brassica juncea), and other cruciferous plants [39]. In vitro assays showed that sinapine at concentrations typical of rapeseed pomace extracts exhibited ≥50% antioxidant activity relative to the total extract, indicating its capacity to scavenge free radicals and protect biological molecules, such as DNA [40]. Further in vitro studies demonstrated that sinapine's antioxidant capacity, as assessed by radical-scavenging assays, remained robust when embedded in protein-based hydrogels, thereby confirming its radical-neutralizing capabilities in complex media [41].

Sinapine and its derivatives, including sinapic acid, have also shown anti-inflammatory effects in various biological models. Studies indicated that supplementing mice with sinapine hindered the generation of TNF-α and NF-ϰB, two markers of systemic inflammation, in intestinal and adipose tissues. This suggests that sinapine can suppress inflammatory signaling pathways linked to metabolic stress [42]. Proteomic studies examining how sinapine affects macrophages have shown that it can transform them from the pro-inflammatory M1 state to the anti-inflammatory M2 state, which is linked to improved lipid handling in immune cells and reduced inflammatory responses [43]. Sinapine differs from other phytochemicals studied because it has both hydrophilic and robust antioxidant properties. This could make it more effective when applied to the skin [44, 45].

The combined antioxidative and immunomodulatory roles of sinapine make it an attractive therapeutic candidate for controlling AD. Phenolic constituents are studied for anti-inflammatory and antioxidative activities, but there is insufficient proof for the anti-eczematous roles of topically administered sinapine. Although previous studies have investigated sinapine in keratinocytes in vitro and in an AD-like mouse model using oral administration, with DNCB/DFE applied to the ears [46], the effects of topical sinapine administration remain insufficiently characterized. The present study evaluated a 1% sinapine cream in a DNCB-induced murine model, assessing clinical dermatitis severity, serum IgE, skin IL-4 and IL-13, MDA and GSH levels, histopathological changes, and filaggrin immunoreactivity. The study therefore extends previous work by evaluating topical administration and a combined set of clinical, biochemical, histological, and immunohistochemical outcomes. However, the findings should be interpreted in light of the single concentration evaluated and the absence of direct measurements of the proposed molecular mechanisms and functional skin-barrier recovery.

2. MATERIALS AND METHODS

2.1 Drugs and chemicals:

Drugs and chemicals applied in the present trial were supplied from various companies. DNCB was delivered from Shanghai-Aladdin Biochemical-Technology Co., Ltd., catalog no.: C465514-25g, lot #D2527134, while tacrolimus 0.1% ointment was supplied by Ajanta, India. All mouse ELISA kits were acquired from ELK Biotechnology. Sinapine was obtained from Chengdu

Biopurify Phytochemicals Ltd (Chengdu, China) (Catalogue No.: BP1308; CAS No.: 18696-26-9; Lot No.: PRF23022444). The phytocompound had a confirmed purity of 98% (manufacturer specification: 95-99%), a molecular formula of $C_{16}H_{24}NO_5^+$, and a molecular weight of 310.369 g/mol. The purity was established using HPLC-DAD and/or HPLC-ELSD.

Mouse IgE ELISA Kit, cat.: ELK2593, lot: 32475732. Mouse IL4 ELISA Kit, cat.: ELK1153, lot: 52775764. Mouse IL-13 ELISA Kit, cat.: ELK1145, LOT: 32675764. Mouse MDA ELISA Kit, cat.: ELK10925, lot: 52775764. Mouse GSH ELISA Kit, cat.: ELK10913, lot: 32675764. An immunohistochemistry antibody to filaggrin was purchased from Cloud-Clone Corp., cat. no.: PAJ103Mu01, lot: A20251125153. HRP-conjugated IgG with DAB chromogen was purchased from Elabscience, cat. no.: E-IR-R213, lot: DW0686N021246.

2.2 Ethical approval statement:

The Animal Ethics Committee of the Institutional Review Board (IRB) of the College of Medicine/Al-Nahrain University issued an approval statement (approval number 1364, date: October 7, 2025). The authors adhered to ARRIVE 2.0's recommendations [47, 48].

2.3 Experimental animal maintenance and housing:

The Iraqi medical center in Al-Yarmouk's animal house served as the study site. The Al-Rhazi Laboratory provided 50 male Albino BALB/c mice, averaging 20–32 g and maturing at 6–9 weeks, which were selected as a suitable animal strain for the investigation. The animals were given a week to become acquainted with their new surroundings and were kept in SPF settings with 12-hour light/dark cycles, clean, sterile housing, unrestricted access to water, and complimentary feeding. Throughout the experiment, a new, sterile substrate was added to the cage every two days.

2.4 Study design and animal allocation

A prospective, randomized, controlled animal study was conducted. This study included 50 male albino-type mice, which were arbitrarily separated into five groups, with each testing group allocated 10 mice. The research methodology and the data from the initial research reports were utilized to calculate the group size. The sufficiency of the sample size is supposed to be viewed as a methodological constraint because a preceding power estimate had not been recorded.

Group 1 (healthy control): 10 healthy mice that received no medical care and had normal skin.

Group 2 (induction): 10 mice with induced AD that received no treatment.

Group 3 (tacrolimus): 10 mice with induced AD received a topical 0.1% tacrolimus ointment once a day.

Group 4 (vehicle): 10 mice with induced AD were given a vehicle-based cream once daily.

Group 5 (sinapine): 10 mice with induced atopic dermatitis were treated with a 1% sinapine cream once a day.

Figure 1 shows a graphic illustration of the research methodology.

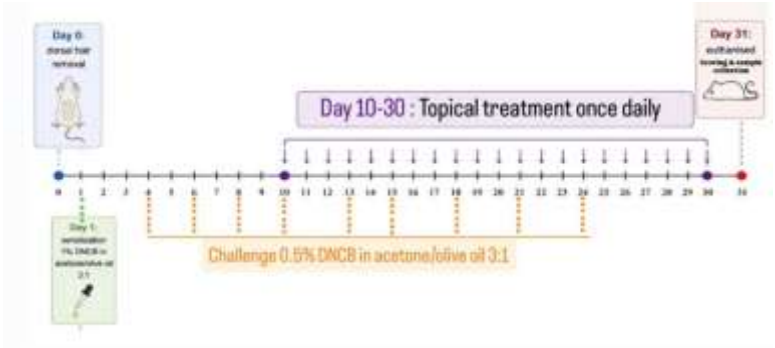

Figure 1. Graphic illustration of the research methodology. Animals were first sensitized with 1% DNCB on day 1. Starting from day 4, they received 0.5% DNCB three times weekly for three weeks. Beginning on day 10, they were treated topically once daily for three weeks with 1% sinapine, a vehicle cream, and 0.1% tacrolimus. On day 31, the mice were assessed using an adapted four-item murine dermatitis severity score and then sacrificed for blood and skin sample collection.

2.5 Induction procedure and treatment of Atopic dermatitis:

After a 7-day acclimatization period, the hair on the cutaneous back surface was meticulously excised with precise electrical shaving. All leftover hair was removed using hair-removing cream, and the animals rested for a day. On day 1, 150 µL of 1% DNCB (dispersed in a 3:1 solution of acetone and olive oil) was utilized once to the back skinfolds (about 4 cm^2) of all mouse groups except the control group. Four days after the sensitization phase, the dose was boosted with 150 µL of 0.5% DNCB three times a week for 3 successive weeks, based on slightly modified versions of previously described protocols [33, 49]. Mice were given tested agents daily for three weeks following visual confirmation of skin sensitization and AD.

All animals in the experiment were sacrificed on day 31. Each mouse was anesthetized with a xylazine/ketamine mixture of 10/80 mg/kg, respectively, administered intraperitoneally (IP). All mice were euthanized by exsanguination (cardiac puncture) after full anesthesia; this method is suitable for tissue collection and preservation. Skin and blood samples were collected for further analysis.

To reduce selection bias, mice were arbitrarily distributed to testing categories by a computer-driven randomizing procedure. Allocation concealment was maintained by an independent investigator not involved in outcome assessment. Topical treatments were applied at consistent time intervals throughout the experimental period. Starting on day 10, topically applied agents were given once daily for 21 days. To guarantee therapeutic comparability, 100 mg of the designated preparation (1% sinapine cream, vehicle cream, or 0.1% tacrolimus ointment) was administered evenly to each mouse's around 4 cm^2 lesioned dorsal skin (about 25 mg/cm^2). All treatment groups followed identical administration protocols during the trial. To prevent observer bias, investigators who performed clinical grading, biochemical testing, and histological examination were blinded to group assignment.

2.6 Tacrolimus Dose Justification

Tacrolimus was administered topically at a concentration of 0.1%, which is a clinically authorized and frequently employed preparation for moderate-to-severe atopic dermatitis [50, 51]. This dose was also extensively utilized in mouse models to provide persistent immune-modulatory and anti-inflammatory benefits, serving as a credible reference standard for comparisons [52, 53].

2.7 Sinapine 1% cream formulation

Sinapine is a hydrophilic alkaloid with anti-inflammatory and antioxidant properties. A standard emulsification technique was used to prepare an oil-in-water cream containing 1% sinapine [54, 55]. After dispersing carbomer (0.5%) in purified water, glycerin (3%) and propylene glycol (5%) were added. The aqueous phase was then heated to 70°C, and sinapine was dissolved. Cetostearyl alcohol (2%) was melted separately at about 70°C and then gradually poured into the aqueous phase with agitation. Triethanolamine was used to modify the pH to 5.5, and phenoxyethanol (0.8%) was added as a preservative [56-58]. The cream was administered to the lesioned skin once per day and kept in sterile containers.

The concentration of sinapine (1%) was chosen in light of preliminary considerations and pertinent earlier research into sinapine and its derivatives, which found strong anti-inflammatory and antioxidative activities at equivalent amounts [59-61]. However, a documented dose–response analysis with supporting quantitative data was not available for reporting. Only the 1% sinapine formulation was evaluated in the present study; therefore, a dose–response relationship and the optimal topical concentration could not be established. Further studies should investigate multiple concentrations to determine the dose–response relationship and local tolerability.

2.8 Vehicle cream formulation:

After dispersing carbomer (0.5%) in purified water, glycerin (3%) and propylene glycol (5%) were added. To create an emulsion, cetostearyl alcohol (2%), separately melted at about 70°C, was gradually added to the aqueous phase while stirring. Triethanolamine was used to adjust the pH to 5.5, and phenoxyethanol (0.8%) was added as a preservative. For topical application, the vehicle cream was stored in sterile containers.

2.9 Sample collection:

The experiment took 31 days to complete. All animals were sacrificed to collect samples, and the heart was punctured to draw blood. To separate serum, blood was gathered in a gel tube and spun for seven minutes at 5000 rpm and kept at -20°C till the

day of analysis [62, 63]. All animals were deeply anesthetized with intraperitoneal xylazine (10 mg/kg) and ketamine (80 mg/kg) and euthanized by exsanguination via cardiac puncture. Blood and skin samples were subsequently collected for biochemical, histopathological, and immunohistochemical analyses.

2.10 Preparation of skin tissue homogenates

After euthanasia, dorsal skin specimens were extracted, washed with freezing-cold phosphate-buffered saline solution (pH 7.2-7.4) to eliminate any residual blood, and weighed [53, 64]. For biochemical analysis, 100 mg of skin tissue was homogenized with a Polytron homogenizer on ice in 1 mL of frozen PBS enriched with protease inhibitors, 0.05% sodium azide and 0.5% Triton X-100. The mixtures were spun up at 5,000 rpm for 10 minutes at 4°C. The supernatant was kept at −20°C until analysis. The residues were gathered and maintained at −20°C for further biochemical analysis. The tissue IL-4, IL-13, MDA, and GSH levels were determined by employing the respective assay kits as per the company's guidance, and the levels of IL-4 and IL-13 were expressed as pg/g tissue, and MDA and GSH levels were expressed as ng/g tissue.

2.11 Observational severity assessment:

Clinical dermatitis severity was assessed using an adapted four-item murine scoring system based on selected clinical features associated with SCORAD. Erythema, erosion/deep excoriation, edema, and scaling were each graded from 0 (absent) to 3 (severe). The total score ranged from 0 to 12, with higher scores indicating greater dermatitis severity. This adapted score was not equivalent to the full SCORAD instrument [65, 66].

2.12 Enzyme-linked immunosorbent assay (ELISA) technique:

After being cleaned with cold normal saline, skin tissues were rinsed with PBS (1X), blotted dry, and weighed. A Polytron homogenizer on ice was used to homogenize 100 mg of tissue in 1 mL of cold PBS (pH 7.2) holding protease inhibitors, 0.05% sodium azide, and 0.5% Triton X-100. After centrifuging the homogenates at 5,000 rpm for 10 minutes at 4°C, the residuals were extracted and kept at -20°C for subsequent testing. Sandwich ELISA kits were used to measure serum IgE levels according to the manufacturer's instructions [67, 68]. Tissue homogenates were used to measure skin tissue biomarkers, including IL-4, IL-13, MDA, and GSH. Sandwich ELISA kits were utilized to determine IL-4 and IL-13, and competitive/colorimetric assay kits were used to measure MDA and GSH depending on the supplier's regulations. A microplate detector (Huma Reader®, HUMAN Diagnostics, USA) was used to measure absorbance at 450 nm for each assay, and concentrations were determined using the corresponding standard curves [69, 70].

To ensure the tests were accurate, all ELISA measurements were performed twice, as the manufacturer specified. The kit manufacturer's specifications were met for assay sensitivity and detection limits. To reduce inter-assay variability, samples were processed consistently.

2.13 Histopathological assessment:

The dorsum epidermis had been preserved in a neutral-buffering formalin before being washed with faucet water. The specimens were wrapped in paraffin and sliced into 5 μm slices with a rotational microtomic reagent (Zeiss AG). The samples had staining with hematoxylin and eosin (H&E) after 3 minutes of deparaffinization and 3 minutes of rehydration. All staining reactions were conducted at room temperature. Histopathological alterations, including acanthosis, hyperkeratosis, parakeratosis, erosion, dermal inflammation, and extracellular edema, were observed. The evaluation was conducted applying a semi-quantitative grading method (0 = no anomaly, where 1+ indicates mild, 2+ moderate, and 3+ severe [71].

For each animal, three non-consecutive cutaneous sections were cut from the lesioned dorsal skin, and five randomly chosen, non-overlapping microscopic fields were analyzed from each section. All specimens were taken from the same DNCB-treated dorsal skin area to guarantee anatomical uniformity among animals. Histopathological analysis of hematoxylin and eosin-stained segments at ×100 magnification was performed using a semi-quantitative scoring method examining acanthosis, hyperkeratosis, parakeratosis, epidermal erosion, dermal inflammatory cell infiltration, and extracellular edema. The values recorded from all studied fields were averaged to produce a single histopathological score for each animal, which was subsequently applied in statistical analyses. All histopathological examinations were completed by an expert pathologist who was blind to the treatment groups during the research process.

2.14 Immunohistochemistry analysis:

After being wrapped in paraffin, the skin tissues were sliced onto positively charged slides and deparaffinized for 30 minutes at 60°C. The sections were rehydrated with ethanol solutions of decreasing concentration and then treated with the antigen retrieval solution included in the Filaggrin IHC kit. The extracts and the kit's main anti-filaggrin antibody were incubated at 4°C for the entire night. After that, the specimens were rinsed with PBS and incubated for 20 minutes with the secondary antibody. Hematoxylin was used as a counterstain for nuclei, and DAB was used to visualize positive staining. While staining magnitude was graded as 0 (no staining), 1 (weak positivity), 2 (moderate positivity), and 3 (strong positivity), the percentage of positive cells was rated as 0= no staining, 1 = <25%, 2 = 25–50%, 3 = 51-75%, and 4 = >75%. The total staining score (IRS) was calculated by summing the staining intensity score (0–3) and the proportion score (0–4), producing an overall score ranging from 0 to 7. With some minor adjustments to fit the current experimental design, the scoring method was taken from a previously published study [72]. Immunohistochemical scores were determined by a histopathologist blinded to the studied groups. For every mouse, five random microscopic areas per section were examined at ×400 power. The animal was used as the unit of analysis, and the average score across all fields analyzed for each animal was used for statistical analysis.

2.15 Statistical analysis:

Data distribution was assessed using the Shapiro–Wilk test. Normally distributed data were analyzed using one-way ANOVA followed by Tukey's post hoc test, whereas non-normally distributed and ordinal data (clinical, histopathological, and immunohistochemical scores) were analyzed using the Kruskal–Wallis test followed by Dunn's multiple-comparisons test. Appropriate adjustments for multiple comparisons were applied. The statistical test and post hoc procedure used for each outcome were specified in the corresponding figure legend. The individual mouse was considered the experimental unit. All analyses were performed using SPSS version 26.0, and $p \leq 0.05$ was considered statistically significant.

3. RESULTS AND DISCUSSION

3.1 The impact of tested agents on observational severity scores:

The observational severity scores for atopic dermatitis exhibited a significant increase in the induction and vehicle groups relative to the normal control group ($P < 0.05$); however, no substantial difference was noted between the induction and vehicle groups ($P > 0.05$). Both the standard treatment (tacrolimus) and sinapine significantly lowered the severity score in comparison to the induction and vehicle groups ($P < 0.05$), with no substantial differences noticed between the two treatment groups, as illustrated in **Figures 2** and **3**.

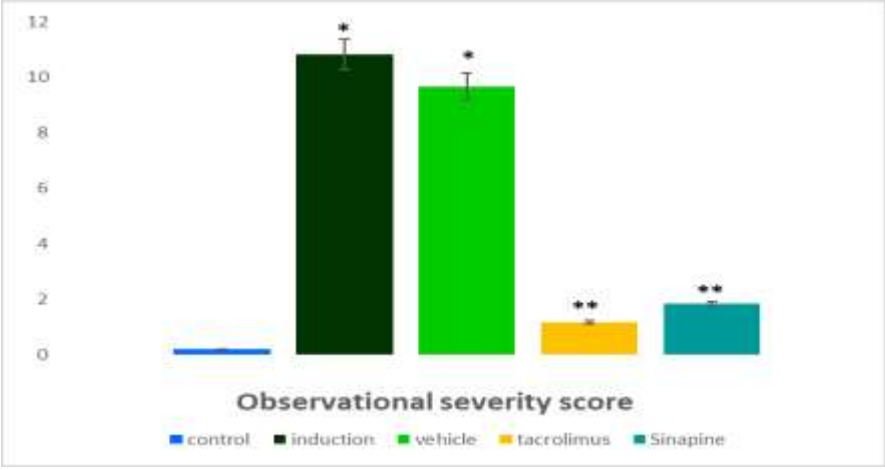

Figure 2: Impact of examined compounds on observational severity scores. Data are displayed as mean ± SD. Each group consisted of 10 mice (n = 10). Differences between groups were assessed via the Kruskal-Wallis test followed by Dunn's multiple comparisons test, with adjustment for multiple comparisons. *=indicates significant differences ($p < 0.05$) versus the control group; **=indicates significant differences ($p < 0.05$) versus the induction and vehicle groups.

Natural Resources for Human Health
eISSN: 2583-1194



Figure 3: Images showing the severity of eczematous lesions in animals from various study groups. A: Control group. B. Induction group. C. Vehicle group. D. Tacrolimus. E. Sinapine.

3.2 Impact of tested agents on serum IgE, skin Th2 cytokines (IL-4, IL-13) in experimental atopic dermatitis:

The induction and vehicle groups exhibited significantly greater serum IgE, skin tissue IL-4, and IL-13 levels than the controls ($p < 0.05$), as indicated in **Figure 4**. In contrast to the induction and vehicle groups, the tacrolimus-treated and sinapine-treated groups showed dramatically reduced levels of IL-4, IL-13, and IgE ($p < 0.05$). However, no significant differences were identified between sinapine and tacrolimus in terms of IgE, IL-4, or IL-13 ($p > 0.05$).

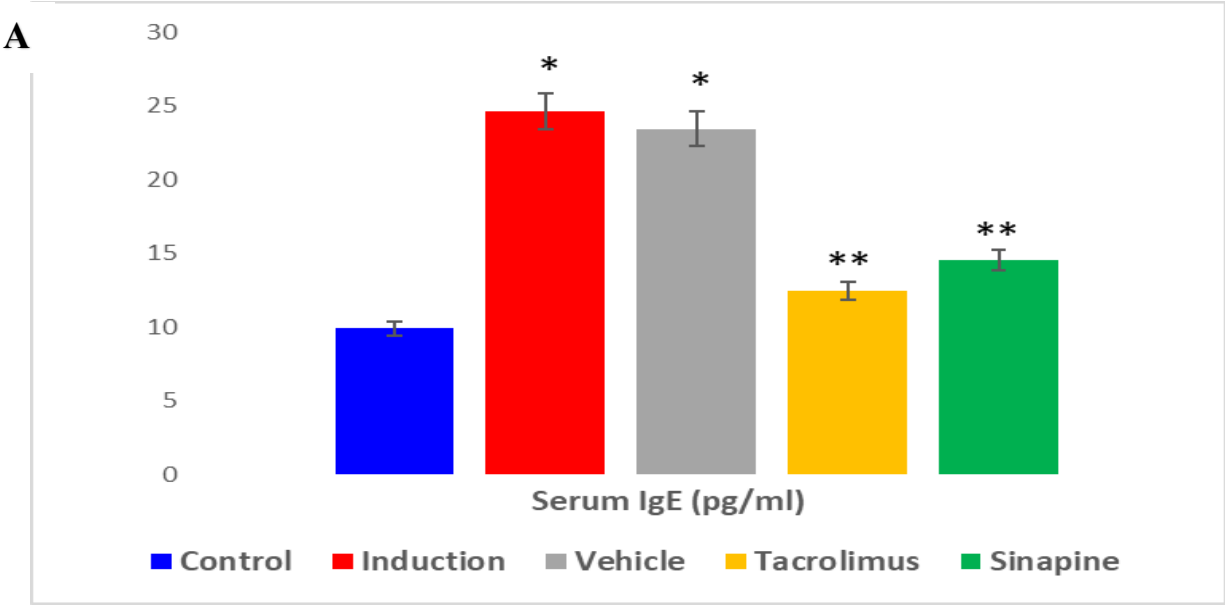

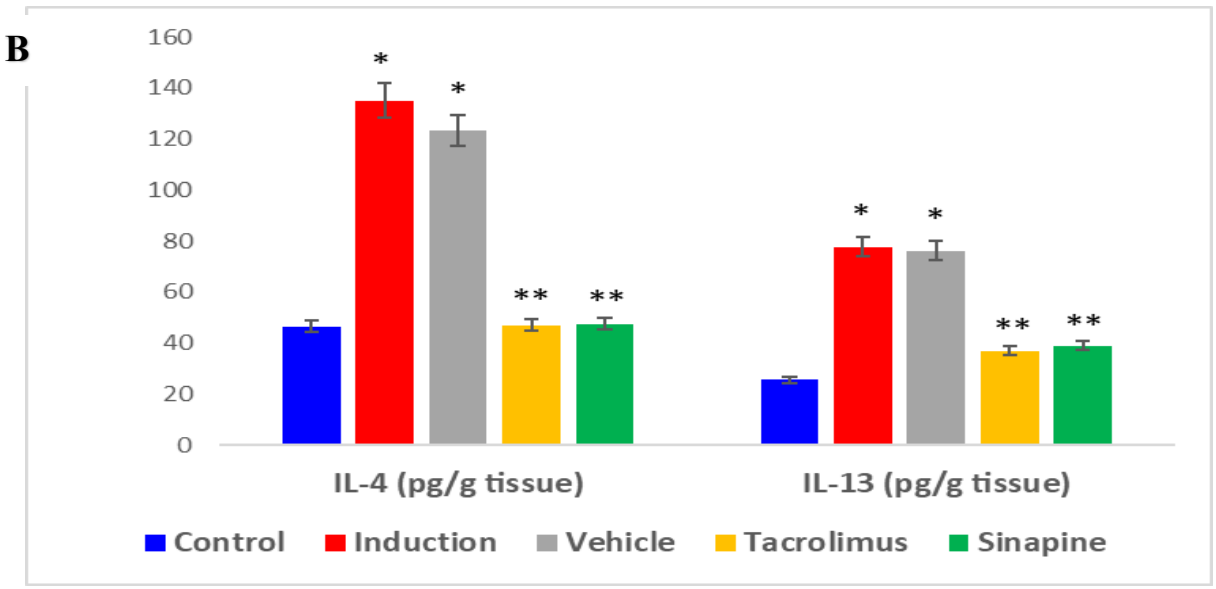

Figure 4: **Effects of examined compounds on serum IgE and tissue IL-4 and IL-13. (A)** Effect of tested agents on serum IgE levels. **(B)** Effect of examined compounds on skin tissue IL-4 and IL-13 levels in skin tissues. Data are displayed as mean ± SD. Each group consisted of 10 mice (n = 10). Data were analyzed using one-way ANOVA followed by Tukey's post-hoc test. *=indicates significant differences ($p < 0.05$) versus the control group; **=indicates significant differences ($p < 0.05$) versus the induction and vehicle groups.

3.3 Impact of tested agents on oxidative stress markers in experimental atopic dermatitis:

In comparison to the healthy controls, the induction (DNCB) and vehicle groups showed a significant decrease in GSH levels and a significant increase in skin tissue MDA levels ($p < 0.05$), as illustrated in **Figure 5**. There was no remarkable variation between the vehicle and induction groups in terms of MDA or GSH.

In contrast to the DNCB-induction and vehicle groups, the treatment groups markedly hindered MDA levels and restored GSH levels. Importantly, there were no statistically meaningful variations between the tacrolimus and sinapine groups with respect to the amounts of MDA or GSH ($p > 0.05$).

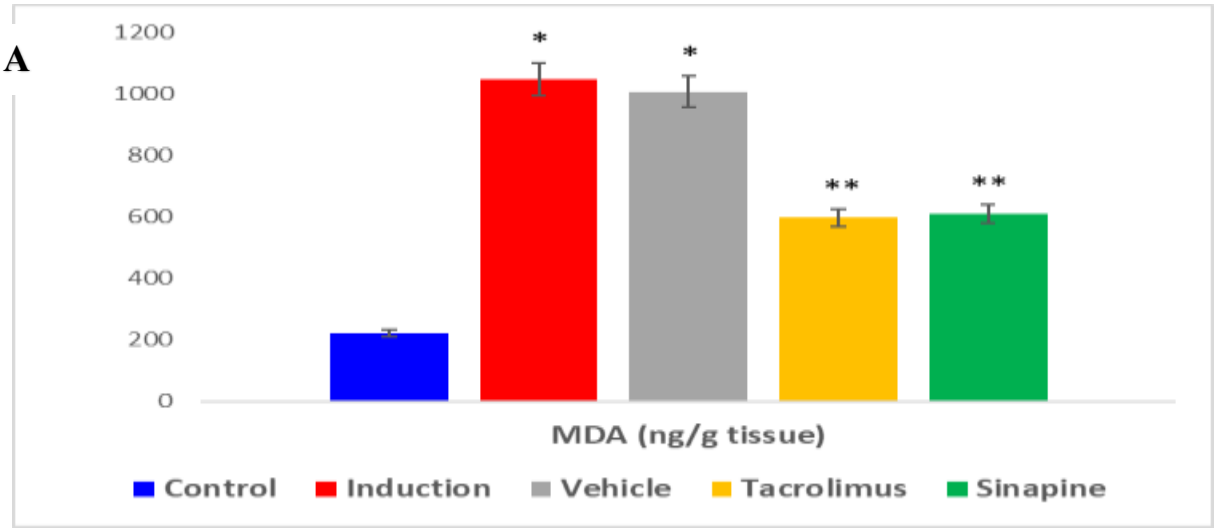

Natural Resources for Human Health
eISSN: 2583-1194

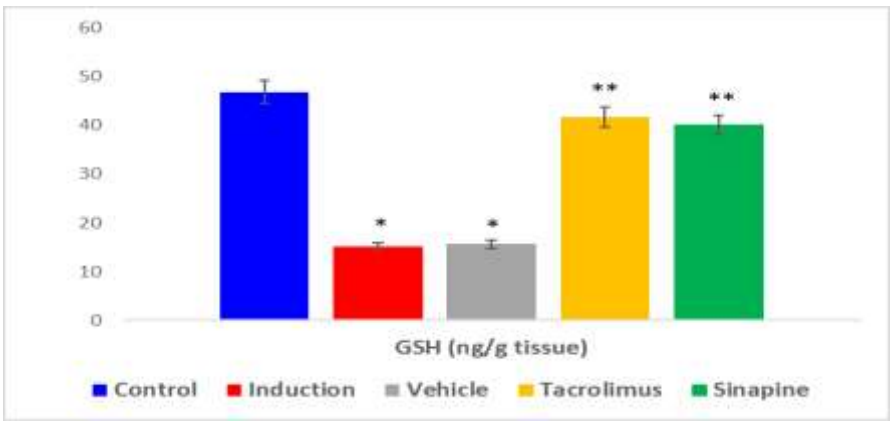

Figure 5: Effects of examined compounds on oxidative stress indicators. (A) Effect of examined compounds on MDA levels. (B) Effect of examined compounds on GSH levels. Data are displayed as mean ± SD. Each group consisted of 10 mice (n = 10). Group comparisons were performed using one-way ANOVA followed by Tukey's post-hoc test. *= indicates significant differences ($p < 0.05$) versus the control group; ** indicates significant differences ($p < 0.05$) versus the induction and vehicle groups.

3.4 Impact of tested agents on alterations in skin histopathology:

The histological study demonstrated that the healthy control group's skin structure was typical, with no pathological changes. Conversely, the induction (DNCB) group had a substantial rise in all examined histopathological metrics, comprising acanthosis, hyperkeratosis, parakeratosis, erosion, dermal inflammation, and extracellular edema, in comparison to the healthy controls. There were no substantial distinctions between the vehicle-treated and induction groups, suggesting that the vehicle had no effect on the development of the disease.

The tacrolimus-treated and sinapine-treated groups dramatically diminished all histopathological characteristics versus the DNCB-induction and vehicle groups ($p < 0.05$) (**Figures 6** and **7**). Interestingly, no statistically substantial variations were seen between the tacrolimus and sinapine groups in any of the variables tested ($p > 0.05$).

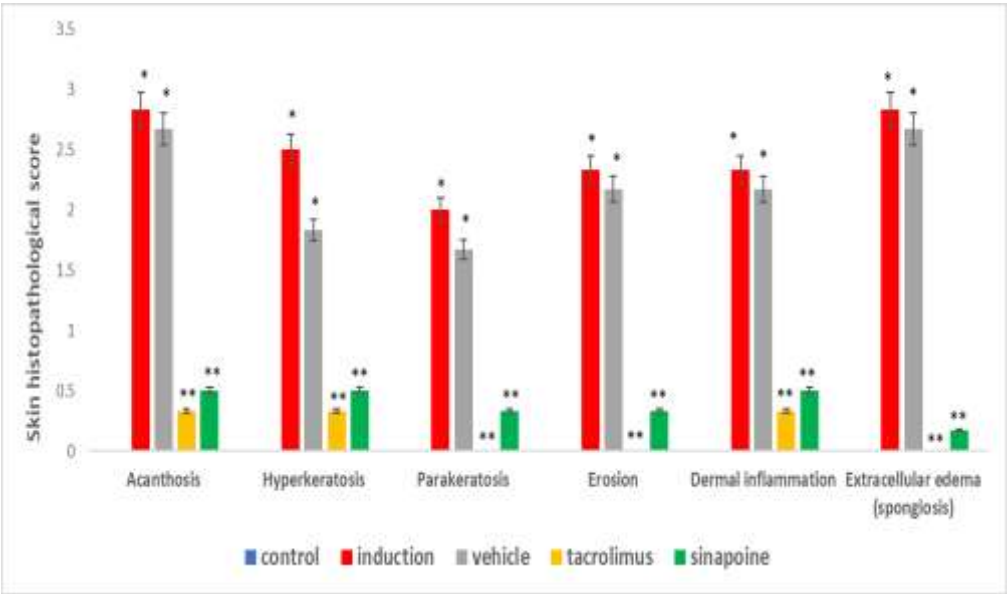

Figure 6: Impact of tested agents on skin histopathological score. Data are displayed as mean ± SD. Each group consisted of 10 mice (n = 10). Group comparisons were performed using the Kruskal–Wallis test followed by Dunn's multiple-comparisons test, with adjustment for multiple comparisons. *=indicates significant differences ($p < 0.05$) compared to the control group; **=indicates significant differences ($p < 0.05$) compared to the induction and vehicle groups.

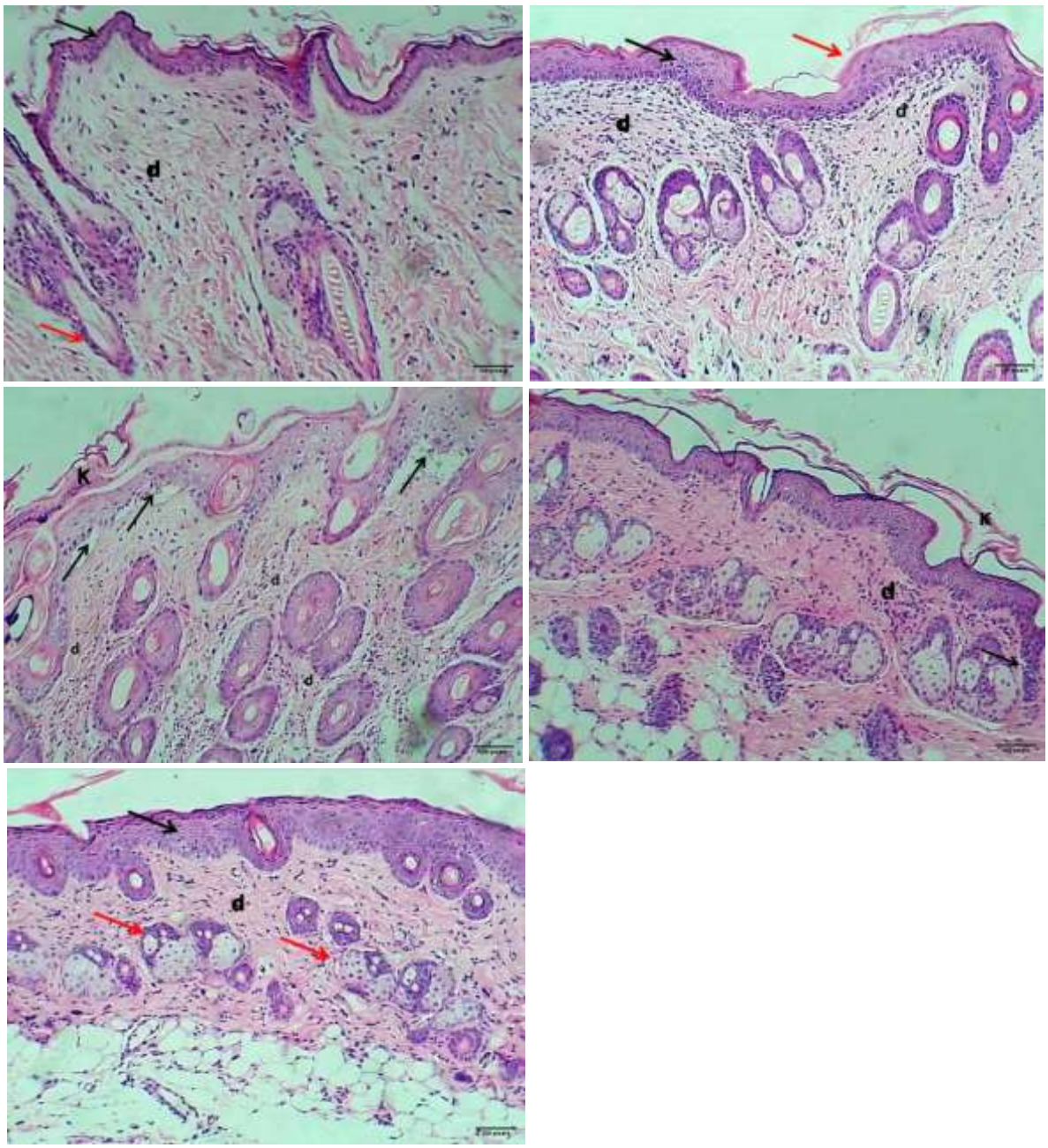

Figure 7: Impact of studied agents on mouse skin histopathology alterations. (A) Cross-section of skin under light microscopy for a healthy control presenting normal appearance of epidermis lining cells with normal keratin layer (black arrow), dermis fibrous tissue (yellow arrow), and hair follicles (red arrow). H&E stain, 100x. (**B). Cross-section of skin for induction (DNCB) group** showing acute atopic dermatitis with marked acanthosis with spongiosis featuring little hyperkeratosis (red arrow) and fibroplasia of dermis fibrous tissue with active angiogenesis (d), H&E stain, 100x (**C). Cross-section of skin for vehicle group** revealing severe degeneration with necrosis of lining cells and spongiosis from formation of epidermis (black arrow), hyperkeratosis and parakeratosis (k) & dermal papillae formation that revealed angiogenesis with perivascular and perifollicular infiltration of leukocytes (d). H&E stain. 100x. **(D). Cross-section of skin for the standard (tacrolimus) group** demonstrating little focal acanthosis of lining cells of the epidermis (black arrow), little hyperkeratosis (k), and dermis fibrous tissue infiltrated with leukocytes (d). H&E stain. 100x. **(E). Cross-section of skin for the sinapine group**

exhibiting normal stratum basale cells of the epidermis with normal stratum corneum (black arrows) and normal dermis fibrous tissue (d). & related sebaceous glands (red arrows). H&E stain. 100x. Scale bar = 100 μm.

3.5 Impact of tested agents on Immunohistochemistry expression of Filaggrin:

Using a semi-quantitative scoring system, the immunohistochemical cutaneous expression of filaggrin was assessed across the various study groups. The immunohistochemistry score (IRS) was computed as the sum of the intensity and percentage scores for both staining intensity and the percentage of positively stained cells. The induction and vehicle groups showed remarkable reductions in immunohistochemical expression of filaggrin versus controls.

In comparison with healthy controls, the DNCB-induction and vehicle groups revealed substantially reduced filaggrin expression, with weak and discontinuous staining, indicating epidermal barrier degradation ($p < 0.05$). The tacrolimus-treated group exhibited substantial enhancements in filaggrin expression compared to the DNCB-induction and vehicle groups. Likewise, sinapine (1%) treatment effectively corrected filaggrin expression relative to the induction group ($p < 0.05$), resulting in greater staining intensity and a higher proportion of positively stained keratinocytes. A comparison of the sinapine and tacrolimus groups displayed no statistically noteworthy distinction in filaggrin immunoreactivity ($p > 0.05$). This observation suggests that, in the circumstances of the current analysis, sinapine therapy is correlated with elevated filaggrin expression. **Figure 8** summarizes the findings by providing mean ± SD values for each parameter throughout the tested groups, while **Figure 9** displays representative images.

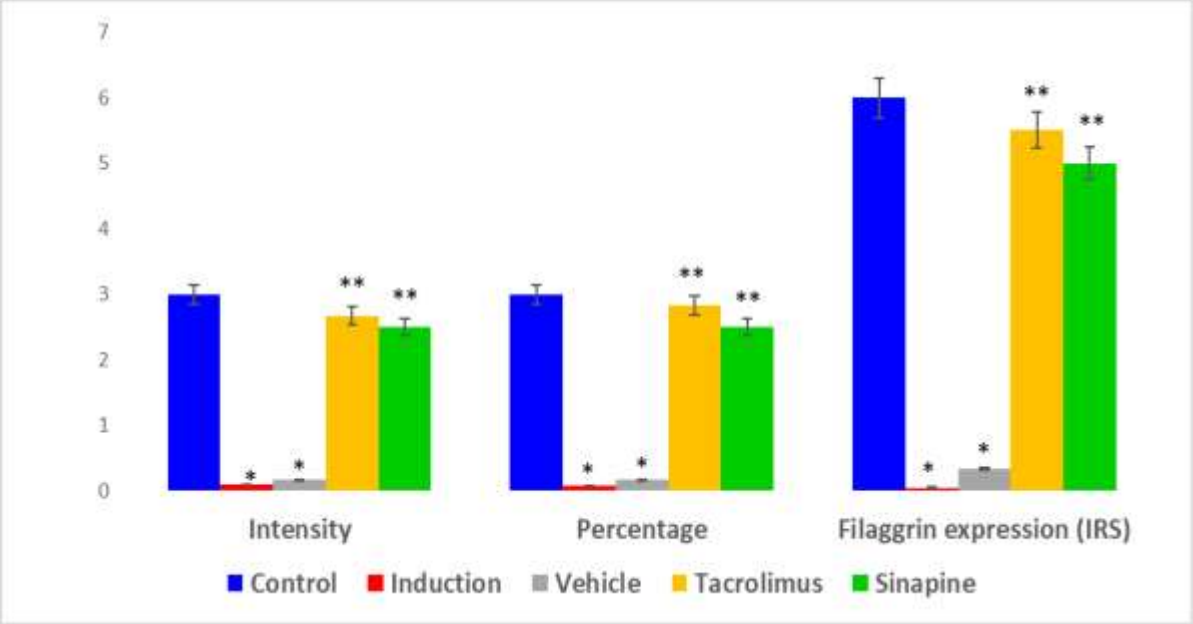

Figure 8: Effects of tested agents on immunohistochemistry scores of filaggrin expression in an experimental atopic dermatitis model. Data are displayed as mean ± SD. Each group included 10 mice (n = 10). Group comparisons were performed using the Kruskal–Wallis test followed by Dunn's multiple-comparisons test, with adjustment for multiple comparisons. *=indicates significant differences ($p < 0.05$) compared to the control group; **=indicates significant differences ($p < 0.05$) compared to the induction and vehicle groups.

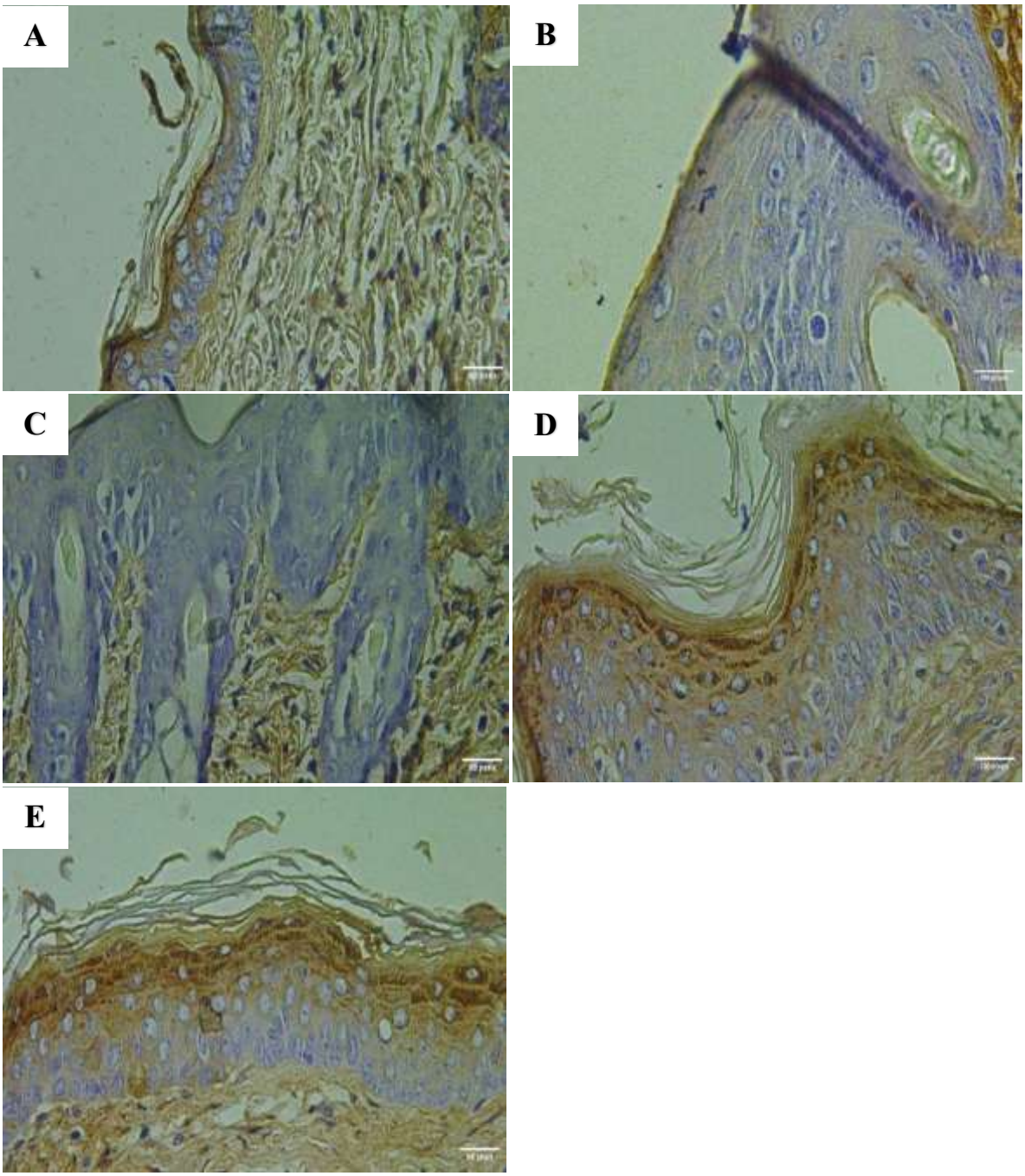

Figure 9: Representative immunohistochemical staining of filaggrin expression in the skin of the experimental groups. (A) The healthy controls had prominent cytoplasmic staining in the epidermis, notably in the stratum granulosum and stratum corneum (×400). **(B)** The Induction (DNCB-induced) group exhibited significantly reduced filaggrin expression in epidermal keratinocytes (×400). **(C)** The vehicle group demonstrated low filaggrin expression in epidermal keratinocytes (×400). **(D)** The standard (0.1% tacrolimus) group showed significant restoration of cytoplasmic filaggrin expression in the epidermis (×400). **(E)** The sinapine-treated group displayed high cytoplasmic filaggrin expression in the epidermis, affecting over 80% of keratinocytes (×400). Scale bar = 100 μm.

3.6 Discussion:

Atopic dermatitis is a widespread autoinflammatory and allergic skin disorder characterized by recurrent eczematous patches with redness, dryness, and itching triggered by a complicated interaction of cutaneous barrier breakdown, immunological

disturbance, and oxidative damage [73, 74]. Considering the risks and negative side effects resulting from long-term administration of traditional medicines, investigating naturally occurring, plant-based, bioactive compounds became a key literature priority [75-77].

The current investigation employed a well-known mouse model in which repeated administration of the hapten DNCB effectively mimicked a human AD-like phenotype, as demonstrated by substantial increases in clinical dermatitis scores, increased concentrations of inflammatory Th2 cytokines (IL-4 and IL-13), elevated serum IgE amounts, raised lipid peroxidation markers (MDA), and decreased skin antioxidant (GSH) and barrier protein (filaggrin) levels. Moreover, typical atopic dermatitis-like changes, such as hyperkeratosis, epidermal thickening, and inflammatory cell infiltration, were confirmed by histopathological examination. Taken together, these results confirm that the AD model was successfully established.

Increased serum IgE is characteristic of atopic dermatitis, with about 80% of patients displaying elevated IgE levels [78]. Moreover, IL-4 and IL-13 are pivotal in the pathogenesis of AD by facilitating B-cell class switching to IgE, recruiting eosinophils, and sustaining allergic inflammation [79, 80]. Upregulated IgE levels confirm systemic hypersensitivity and are strongly associated with disease severity [81]. The current results also showed a marked increase in MDA levels, suggesting increased oxidative damage and lipid peroxidation [82-84]. Simultaneously, a significant reduction in GSH was observed, indicating weakened antioxidant defenses [83, 85].

This study also found no statistically significant differences in major structural endpoints between the vehicle-exposed group and the DNCB-induced group in mice. Park et al. (2020) reported analogous findings, indicating no significant disparity in histopathology grades among the vehicle-exposed and DNCB-induced groups [86]. Another study found that the total serum IgE and cutaneous IL-4, IL-13, and MDA amounts were not markedly different among the groups treated with the vehicle and those that were not [53, 80].

The vehicle-treated group showed no statistically significant improvement in the major disease-related outcomes compared with the untreated DNCB-induced group, suggesting that the vehicle alone did not account for the observed therapeutic effects. In contrast, topical sinapine treatment was associated with improvements in several assessed outcomes, including inflammatory and oxidative-stress markers, histopathological findings, and filaggrin immunoreactivity. These findings suggest that sinapine may contribute to the observed effects beyond those attributable to the vehicle formulation.

Elevated Th2 cytokines, especially IL-4 and IL-13, which are established to suppress filaggrin generation and worsen barrier dysfunction, may be the cause of this persistent decrease in filaggrin, which is consistent with atopic dermatitis pathology [87, 88]. These results imply that the pathological and immunological alterations in atopic dermatitis are not considerably impacted by vehicle treatment [89-91].

Topically applied corticosteroids are still a primary choice of therapy for atopic dermatitis and several other dermatoses [92-94], but the present investigation did not include them as a comparator group, which would provide a broader therapeutic context. The main goal was to compare sinapine to tacrolimus, a non-steroidal immune-modulating drug that is frequently prescribed for those whose prolonged steroid administration is restricted because of undesirable side effects including skin shrinkage and inhibition of the hypothalamic-pituitary-adrenal axis [95-97]. Prospective research that incorporates corticosteroid-comparing agents would offer an increasingly detailed assessment of therapy.

Tacrolimus ointment 0.1% is a safe and efficient nonsteroidal macrolide option for long-term AD treatment. Tacrolimus is an efficacious topically utilized immunomodulator that reduces T-lymphocyte activation and inflammatory cytokine production by inhibiting calcineurin phosphatase activity [98-100]. Topical tacrolimus has been shown in prior research to alleviate atopic dermatitis by inhibiting Th2 cytokines, specifically IL-4 and IL-13, which are vital mediators of allergic inflammation and IgE production [101]. Furthermore, a decrease in total serum IgE levels has been linked to tacrolimus treatment [102]. The histopathological scores also revealed a significant decrease in epidermal thickness, alongside diminutions in hyperkeratotic growth, parakeratosis, erosions, inflammation, and oedema versus the DNCB-induced group. This outcome is consistent with previous studies demonstrating a similar reduction in dermatitis severity scores following tacrolimus treatment [103, 104].

The administration of 1% sinapine cream once daily for 21 days resulted in significant improvements in both macroscopic and microscopic disease characteristics. When contrasted with the DNCB-evoked and vehicle-exposed groups, administration of 1% topical sinapine was linked to reductions in a number of clinical, biological, histological, and immunohistochemical endpoints. The assessment of statistics indicated that there was no statistically important distinction in the findings among the

tacrolimus-treated and sinapine-treated groups. And such results ought to be viewed as comparative analyses among the studied agents instead of as proof that the two formulations possess similar therapeutic impact because the lack of statistically significant results cannot demonstrate comparable or non-inferior effectiveness.

The observed decrease in serum levels of IgE, IL-4, and IL-13 suggests that sinapine may regulate Th2-mediated immune responses, which are critical components of atopic dermatitis pathogenesis [46]. IL-4 is recognized for its ability to induce IgE class-shifting in B lymphocytes and, in conjunction with IL-13, to enhance allergic inflammation, impair skin barrier function, and facilitate the recruitment of inflammatory cells [105]. Sinapine is a choline ester of sinapic acid, a polyphenolic constituent recognized for its anti-allergic actions, which are ascribed to its capacity to inhibit critical mediators such as IL-4, IL-13, and IgE [106, 107]. The inhibition of the allergic immunological responses seen with sinapine therapy in this research could thus be attributable, at least partially, to the same fundamental mechanisms. This immune-modulatory impact is expected to have contributed to the amelioration in clinical symptoms, as well as the notable decrease in histological abnormalities and skin inflammation reported in treated mice. Besides, the decline in IgE levels provides evidence for the concept that sinapine efficiently controls Th2-driven immune responses, thus mitigating AD severity. These results are in line with earlier research showing sinapine reduced Th2 cytokines and IgE [108, 109].

The detected alterations in indices of inflammation and filaggrin immunnologic reactivity are possibly congruent with the mechanisms formerly linked to AD [110, 111]. In pertinent laboratory settings, NF-ϰB and STAT6 activations were responsible for inflammatory reactions and type 2 immunity function [112-114]. Prior studoes showed that sinapine probably suppresses the formation of pro-inflammatory cytokines like IL-4 and IL-13 through inhibiting NF-ϰB activation [115]. Furthermore, filaggrin expressions could potentially be restored, and Th2 polarization may be reduced as a result of STAT6 signaling blockade [116, 117]. Yet, the current research did not specifically evaluate either NF-ϰB or STAT6. Therefore, based on the identified alterations in IL-4, IL-13, and filaggrin, it isn't possible to conclude that sinapine functioned via NF-ϰB suppression or STAT6 blocking mechanisms. These paths are still viable molecular theories that need to be confirmed through actual experimentation.

The observed reduction in MDA levels suggests decreased lipid peroxidation, while the increase in GSH levels is consistent with improved antioxidant status following topical sinapine treatment [108, 118]. GSH contributes to intracellular antioxidant defense, whereas MDA is commonly used as a marker of lipid peroxidation [18, 119, 120]. Previous studies have suggested that sinapine may help mitigate oxidative damage through its phenolic structure and potential free-radical-scavenging activity [121, 122]. Similarly, increased GSH levels may reflect improved cellular redox balance, potentially through reduced oxidative stress or changes in antioxidant defense mechanisms, including GSH synthesis and regeneration [123-125]. However, these mechanisms were not directly investigated in the present study.

Furthermore, suppressing cutaneous inflammation could indirectly assist in alleviating oxidative injury since inflammatory cells are an important supplier of ROS in allergic and inflammatory dermatoses [126-128]. Together, these immune-modulatory and antioxidant effects can boost the stability of the cutaneous barriers and lessen the clinical manifestations associated with atopic dermatitis. However, the current findings cannot determine if the alterations were triggered by a diminished inflammatory cellular response, modified GSH production or regenerating cells, effective free radical detoxification, or different mechanisms. Such pathways represent probable clarifications instead of verified impacts of sinapine owing to the fact that they have not been properly explored.

More importantly, no full dose-response analysis was executed. As a result, neither the minimal effective dosage nor the optimum therapeutic level nor the possibly harmful concentrations have been established. Prospective research ought to explore different topical concentrations and suitable tolerability evaluations with a complete dosage-response evaluation to determine dosage-response association and maximize therapeutic effectiveness.

The histopathology analysis showed modifications in numerous aspects of DNCB-triggered epidermal lesions after interventions. The documented analyses revealed that sinapine therapy yielded substantially decreased observational severity scores and histopathological features, such as acanthosis, hyperkeratosis, parakeratosis, epidermal erosion, inflammatory penetration, and extracellular edema, relative to both the induction and vehicle-treated groups. Although keratinocytic hypergrowth wasn't clearly determined, the decrement in parakeratosis could suggest improvements in this histology characteristic [87]; therefore, an explicit antiproliferation mechanism cannot be inferred from this observation.

Filaggrin is a structural protein necessary for hydration, defense against environmental allergens, and maintenance of the epidermal barrier's integrity [129, 130]. Yet, boosted filaggrin immunoreaction by itself fails to demonstrate effective repair of the cutaneous barrier since transdermal fluid depletion and additional obvious signs of barrier function have not been measured. It's notable that filaggrin expression is negatively regulated by IL-4 and IL-13, which also contribute to epidermal barrier dysfunction in atopic dermatitis. Thus, elevated IL-4 and IL-13 cytokine activity may contribute to epidermal dysfunction in atopic dermatitis by downregulating filaggrin and other barrier-related genes in human skin [131, 132].

There were no visible signs of skin irritation, worsening of erythema, or adverse reactions in the animals administered sinapine during the course of this trial. However, it deserves to be pointed out that sinapine was formulated in a custom cream base, while tacrolimus was given as a commercial ointment. Variations in vehicle composition and preparation could have an impact on penetration of the skin and local pharmacokinetics, thus influencing therapeutic effectiveness. The two prepared formulaizations cannot be directly compared because of such considerations. The findings need to be taken as a reflection of the examined formulas under the settings of this study, given that composition homogenization, pharmacological release, dermal penetration, and localized compound levels weren't thoroughly described.

Furthermore, the consequences of this trial fail to confirm the complete safety of topically administered sinapine. The lack of a healthy control group receiving sinapine restricts conclusions on its local tolerability or toxicity in non-irritated skin. However, despite no obvious irritations being noted, a dearth of gross regional events must not be regarded as confirmation that the composition has no detrimental side effects, and a full safety assessment warrants additional examination. Moreover, a full toxicological evaluation, including studies on skin toxicity and systemic absorption, is needed before it can be used in humans.

4. CONCLUSION

Topically applied sinapine 1% cream substantially ameliorated the DNCB-triggered murine model of AD-mimicking lesions by regulating clinical dermatitis severity scores, selected inflammatory and oxidative-stress determinants, histopathology parameters, and filaggrin antibody reactivity. The findings presented here offer initial experimental confirmation of potential benefits of topically administered sinapine in subsequent studies. However, the research failed to show non-inferiority or similarity to tacrolimus and couldn't explicitly identify the putative mechanistic pathways or effective recovery of the epidermal barriers. Additionally, interpretation is limited by only one dosage examined, variances among the analyzed formulations, and lack of specific safety evaluation. Nonetheless, due to the preclinical nature of this study, further investigations are warranted to refine dosing strategies, elucidate molecular mechanisms, describe the effectiveness of the preparation, determine safety profiles, and validate efficacy in clinical environments.

5. STUDY LIMITATIONS

This study has certain limitations that should be acknowledged when interpreting the findings. The use of a single concentration (1%) of sinapine without evaluation of a dose–response relationship limits the ability to determine the optimal therapeutic dose. The absence of comprehensive toxicity evaluation, including dermal irritation testing and systemic exposure assessment, restricts conclusions regarding the safety profile of topical sinapine. The formulation was not subjected to detailed physicochemical characterization (e.g., stability, permeability, drug release kinetics), which may influence translational applicability. Mechanistic insights remain limited, as key signaling pathways (e.g., NF-$\varkappa$B, STAT6, and MAPK) were not directly evaluated at the molecular level, making the proposed mechanisms largely inferential.

The DNCB-induced murine model, while widely used, does not fully replicate the complexity of human atopic dermatitis, particularly regarding genetic predisposition and microbiome interactions, thereby limiting direct clinical extrapolation. Despite sinapine having already been researched in several experimental modalities, clinical trials are required to demonstrate its therapeutic efficacy in humans. The current study provides crucial preclinical evidence for its possible function in AD; however, additional research, including clinical trials, is needed to validate these results. Furthermore, future studies should address current limitations by incorporating dose optimization, extended treatment duration, mechanistic validation, safety profiling, and potentially translational clinical investigations.

ACKNOWLEDGEMENTS

THE RESULTS OF THIS EXPERIMENT WERE SUBMITTED AS PART OF THE MASTER'S THESIS TO THE COLLEGE OF MEDICINE, AL-NAHRAIN UNIVERSITY.

AUTHOR CONTRIBUTIONS

NOOR A. ABDULREDHA WAS RESPONSIBLE FOR CONCEPTUALIZATION, METHODOLOGY, EXPERIMENTAL WORK, DATA COLLECTION, DATA ANALYSIS, AND DRAFTING OF THE MANUSCRIPT. **AHMED R. ABU-RAGHIF** CONTRIBUTED TO STUDY DESIGN, SUPERVISION, CRITICAL REVISION OF THE MANUSCRIPT, AND FINAL APPROVAL OF THE VERSION TO BE PUBLISHED. ALL AUTHORS HAVE READ AND APPROVED THE FINAL MANUSCRIPT.

CONFLICT OF INTEREST

There is no competing interest to declare.

ETHICS STATEMENT

The research project was approved by the Institutional Review Board (IRB) (Approval No.: 1364) on 7 October 2025. All experimental procedures were conducted in accordance with institutional guidelines for the care and use of laboratory animals and complied with the National Institutes of Health Guide for the Care and Use of Laboratory Animals.

DATA AVAILABILITY STATEMENT

All data generated or analyzed supporting the findings of this study are available from the corresponding author upon reasonable request.

REFERENCES

[1] Courtney, A., et al., *Burden of Disease and Unmet Needs in the Diagnosis and Management of Atopic Dermatitis in Diverse Skin Types in Australia.* Journal of clinical medicine, 2023. **12**.

[2] Habbas, A.H., et al., *Therapeutic effect of bosentan on 2, 4-dinitrochlorobenzene (DNCB)-induced atopic dermatitis mouse model.* Arch Dermatol Res, 2025. **317**(1): p. 436.

[3] Talamonti, M., et al., *Quality of life and psychological impact in patients with atopic dermatitis.* Journal of Clinical Medicine, 2021. **10**: p. 1–9.

[4] Simpson, E.L., et al., *Two Phase 3 Trials of Dupilumab versus Placebo in Atopic Dermatitis.* New England Journal of Medicine, 2016. **375**: p. 2335–2348.

[5] Leung, D.Y.M. and E. Guttman-Yassky, *Assessing the current treatment of atopic dermatitis: Unmet needs*, in *Journal of Allergy and Clinical Immunology*. 2017, Mosby Inc. p. S47–S48.

[6] Proksch, E., J.M. Brandner, and J.M. Jensen, *The skin: An indispensable barrier.* Experimental Dermatology, 2008. **17**: p. 1063–1072.

[7] Baroni, A., et al., *Structure and function of the epidermis related to barrier properties*, in *Clinics in Dermatology*. 2012. p. 257–262.

[8] Agrawal, R. and J.A. Woodfolk, *Skin barrier defects in atopic dermatitis topical collection on allergic skin diseases.* Current Allergy and Asthma Reports, 2014. **14**.

[9] Ahn, K., et al., *Recent advances in atopic dermatitis*, in *Current Opinion in Immunology*. 2020, Elsevier Ltd. p. 14–21.

[10] Wei, H., et al., *Aqueous extracts of Portulaca oleracea L. alleviate atopic dermatitis by restoring skin barrier function.* Frontiers in pharmacology, 2025. **16**: p. 1591394–1591394.

[11] Boguniewicz, M., *Biologic therapy for atopic dermatitis: moving beyond the practice parameter and guidelines.* The Journal of Allergy and Clinical Immunology: In Practice, 2017. **5**(6): p. 1477–1487.

[12] Fabbrocini, G., et al., *Treatment of atopic dermatitis with biologic drugs.* Dermatology and therapy, 2018. **8**(4): p. 527–538.

[13] Vu, H.X., et al., *A LITERATURE REVIEW OF BIOLOGICS FOR TREATMENT OF ATOPIC DERMATITIS.* Tạp chí Da liễu học Việt Nam, 2025(49).

[14] Nie, W., et al., *Chlorogenic acid alleviates DNCB-induced atopic dermatitis by inhibiting the Akt1/NF-κB signaling pathway.* European Journal of Pharmacology, 2025. **998**.

[15] Lee, J.H. and D.S. Im, *Honokiol suppresses 2,6-dinitrochlorobenzene-induced atopic dermatitis in mice.* Journal of Ethnopharmacology, 2022. **289**.

[16] Mitroi, G.G., et al., *Exploring the potential of IL-4 and IL-13 plasma levels as biomarkers in atopic dermatitis.* Life, 2024. **14**(3): p. 352.

[17] Čelakovská, J., et al., *Evaluation of the levels of interleukins IL-4, IL-13, IL-5, IL-10 and IL-33 in atopic dermatitis patients with and without dupilumab therapy.* Frontiers in Immunology, 2025. **16**: p. 1604883.

[18] Luo, Y., et al., *Oxidative stress products and managements in atopic dermatitis.* Frontiers in Medicine, 2025. **12**: p. 1538194.

[19] Abbas, A., et al., *The Attenuated Effects of Cimifugin on Imiquimod-Induced Model of Psoriasis in Mice.* Latin American Journal of Pharmacy, 2023. **42**(Special issue): p. 362–369.

[20] Park, G., et al., *Coriander alleviates 2, 4-dinitrochlorobenzene-induced contact dermatitis-like skin lesions in mice.* Journal of medicinal food, 2014. **17**(8): p. 862–868.

[21] Hebert, A.A., *Oxidative stress as a treatment target in atopic dermatitis: The role of furfuryl palmitate in mild-to-moderate atopic dermatitis.* International Journal of Women's Dermatology, 2020. **6**(4): p. 331.

[22] Beken, B., et al., *Quercetin improves inflammation, oxidative stress, and impaired wound healing in atopic dermatitis model of human keratinocytes.* Pediatric allergy, immunology, and pulmonology, 2020. **33**(2): p. 69–79.

[23] Abbas, A.H., et al., *Mitigative effects of a topically-applied combination of cimifugin and vinpocetine on a murine psoriasis-like model.* Pharmakeftiki, 2025. **37**(2S).

[24] Abdulbari, A.S., et al., *Impact of azithromycin on specific biochemical markers and sebum composition in acne vulgaris patients.* Archives of Dermatological Research, 2025. **317**(1): p. 798.

[25] Cordiano, R., et al., *Malondialdehyde as a potential oxidative stress marker for allergy-oriented diseases: an update.* Molecules, 2023. **28**(16): p. 5979.

[26] Shihab, E.M., H.M. Kadhim, and S.S. Shahooth, *The impact of carvedilol on level of interleukin-6, superoxide dismutase, elastin levels and epidermal thickness in experimentally aging induced mice model.* Journal of Research in Pharmacy, 2025. **29**(1): p. 11–19.

[27] Al-Oudah, G.A., et al., *The Effect of Metformin and Biological Therapy on Insulin Resistance in Iraqi Psoriatic Patients.* International Journal of Drug Delivery Technology, 2023. **13**(1): p. 224–227.

[28] Bertino, L., et al., *Oxidative stress and atopic dermatitis.* Antioxidants, 2020. **9**(3): p. 196.

[29] Khorsheed, S.M. and A.R. Abu Raghif, *Anti-proliferative, Anti-oxidant and Anti-inflammatory Effects of Topical Rutin on Imiquimod-Induced Psoriasis in Mice.* Pakistan Journal of Life and Social Sciences, 2024. **22**(1): p. 1962–1976.

[30] Park, G., et al., *6-Shogaol, an active compound of ginger, alleviates allergic dermatitis-like skin lesions via cytokine inhibition by activating the Nrf2 pathway.* Toxicology and applied pharmacology, 2016. **310**: p. 51–59.

[31] Batista, D., et al., *Profile of skin barrier proteins (filaggrin, claudins 1 and 4) and Th1/Th2/Th17 cytokines in adults with atopic dermatitis.* Journal of the European Academy of Dermatology and Venereology, 2015. **29**(6): p. 1091–1095.

[32] Ilves, T., et al., *Epidermal expression of filaggrin/profilaggrin is decreased in atopic dermatitis: reverse association with mast cell tryptase and IL-6 but not with clinical severity.* Dermatitis, 2015. **26**(6): p. 260–267.

[33] Hassan, Z.Y., T.Y. Hassan, and A.R. Abu-Raghif, *Evaluation the Effectiveness of Phenolic Compound of Salvia frigida on Induced Atopic Dermatitis in Experimental Mice.* Iraqi Journal of Pharmaceutical Sciences, 2022. **31**: p. 154–166.

[34] Hussein, M.N., et al., *Flavonoids from Conyza Canadensis mitigates CDNB-induced mouse model of atopic dermatitis.* Comparative Clinical Pathology, 2025. **34**(5): p. 987–1010.

[35] Nguyen, V.P.T., et al., *Sinapic Acid and Sinapate Esters in Brassica: Innate Accumulation, Biosynthesis, Accessibility via Chemical Synthesis or Recovery From Biomass, and Biological Activities.* Frontiers in Chemistry, 2021. **9**: p. 664602–664602.

[36] Natella, F., et al., *Benzoic and cinnamic acid derivatives as antioxidants: structure-activity relation.* Journal of agricultural and food chemistry, 1999. **47**(4): p. 1453–1459.

[37] Pekkarinen, S.S., et al., *Antioxidant activity and partitioning of phenolic acids in bulk and emulsified methyl linoleate.* Journal of agricultural and food chemistry, 1999. **47**(8): p. 3036–3043.

[38] Zou, Y., et al., *Peroxynitrite scavenging activity of sinapic acid (3,5-dimethoxy-4-hydroxycinnamic acid) isolated from Brassica juncea.* Journal of agricultural and food chemistry, 2002. **50**(21): p. 5884–5890.

[39] Nićiforović, N. and H. Abramovič, *Sinapic Acid and Its Derivatives: Natural Sources and Bioactivity.* Comprehensive reviews in food science and food safety, 2014. **13**(1): p. 34–51.

[40] Yates, K., et al., *Determination of sinapine in rapeseed pomace extract: Its antioxidant and acetylcholinesterase inhibition properties.* Food Chemistry, 2019. **276**: p. 768–775.

[41] Li, Y., et al., *Effect of Sinapine on Microstructure and Anti-Digestion Properties of Dual-Protein-Based Hydrogels.* Foods 2024, Vol. 13, 2024. **13**(20).

[42] Li, Y., et al., *Sinapine reduces non-alcoholic fatty liver disease in mice by modulating the composition of the gut microbiota.* Food & function, 2019. **10**(6): p. 3637–3649.

[43] Liu, A., et al., *Quantitative Proteomic Analysis Reveals the Mechanisms of Sinapine Alleviate Macrophage Foaming.* Molecules (Basel, Switzerland), 2023. **28**(5).

[44] Menezes, J.C.J.M.D.S. and V.R. Campos, *Unlocking the Potential of Hydroxycinnamic Acid Bioconjugates: Tailored Derivatives for Biomedical, Cosmetic, and Food Applications*, in *Compounds*. 2024, Multidisciplinary Digital Publishing Institute (MDPI). p. 604–625.

[45] Martinović, N., N. Poklar Ulrih, and H. Abramovič, *Sinapic Acid and its Derivatives Increase Oxidative Stability in Different Model Lipid Systems.* European Journal of Lipid Science and Technology, 2019. **121**.

[46] Kang, R., et al., *Effects of Sinapine on inflammatory responses in keratinocytes and atopic dermatitis-like lesions.* The Korea Journal of Herbology, 2025. **40**(3): p. 45–57.

[47] du Sert, N.P., et al., *Reporting animal research: Explanation and elaboration for the ARRIVE guidelines 2.0.* PLOS Biology, 2020. **18**(7): p. e3000411–e3000411.

[48] Leary, S.L., *AVMA guidelines for the euthanasia of animals : 2020 edition*. 2020: American Veterinary Medical Association. 121–121.

[49] Kasim, V.N.K.M., et al., *Oral and topical administration of a geranyl acetophenone attenuates DNCB-induced atopic dermatitis-like skin lesions in BALB/c mice.* Scientific Reports, 2024. **14**: p. 17623.

[50] Ashcroft, D.M., et al., *Efficacy and tolerability of topical pimecrolimus and tacrolimus in the treatment of atopic dermatitis: meta-analysis of randomised controlled trials.* Bmj, 2005. **330**(7490): p. 516.

[51] Wollenberg, A., et al., *Proactive treatment of atopic dermatitis in adults with 0.1% tacrolimus ointment.* Allergy, 2008. **63**(6): p. 742–750.

[52] Elaf Mahmood, S., et al., *Ramelteon Ameliorates DNCB-Induced Atopic Dermatitis by Targeting Inflammatory and Oxidative Mechanisms in Mice.* Current Drug Therapy, 2026. **21**: p. 1–12.

[53] Shallal, A.M., et al., *Ezetimibe mitigates DNCB-induced mouse model of eczematous dermatitis.* European Journal of Clinical and Experimental Medicine, 2025. **23**: p. 882–897.

[54] Kurebayashi, A.K., et al., *Strategic approaches in formulation development for atopic dermatitis.* Cosmetics, 2024. **11**(4): p. 113.

[55] Mahdi, Z.A., et al., *Amlodipine topical cream: an effective hair growth promoter for an alopecia mouse model via VEGF-mediated angiogenesis and vasodilation.* Archives of Dermatological Research, 2026. **318**(1): p. 134.

[56] Mohiuddin, A.K., *Skin care creams: formulation and use.* Dermatol Clin Res, 2019. **5**(1): p. 238–271.

[57] Al-Athari, A.J.H., et al., *Anti-psoriatic effects of topical ezetimibe on imiquimod-induced psoriasis mouse model.* Pharmacia, 2026. **73**: p. 1–13.

[58] Khaleel, R.A., S.M. Shareef, and T.M. Maryoosh, *ASSESSMENT OF THE ANTI-PSORIASIS EFFECT OF SCROPHULARIA DESERTI METHANOLIC EXTRACT IN MICE MODEL.* ScienceRise: Pharmaceutical Science, 2024. **47**(1): p. 99–105.

[59] Kaltalioglu, K., *Sinapic acid-loaded gel accelerates diabetic wound healing process by promoting re-epithelialization and attenuating oxidative stress in rats.* Biomedicine & Pharmacotherapy, 2023. **163**: p. 114788.

[60] Jin, Z., L. Yin, and Z. Huang, *Sinapic Acid Attenuates Hypertrophic Scarring by Modulating the TGF-β1/Smad Pathway: An In Vivo and In Vitro Investigation.* International Journal of Clinical Practice, 2025. **2025**(1): p. 3671828.

[61] Malviya, N., A. Prabakaran, and A. Alexander, *Comparative study on ethosomes and transferosomes for enhancing skin permeability of sinapic acid.* Journal of Molecular Liquids, 2023. **383**: p. 122098.

[62] Mekkey, S.M., M.A. Ameen, and N.K. Hadi, *A Study of Serum Levels of Ferritin, Hepatic and Renal functions in Beta-Thalassemia Major (BTM) Patients Treated With Deferasirox (DFX) Tablets, Desferioxamine (DFO) Vial, or Combination of Both (DFX+ DFO) in Thalassemia Center/Karbala.* Al-Mustaqbal Journal of Pharmaceutical and Medical Sciences, 2024. **2**(1): p. 4.

[63] Idan, H.M., R.A.M. Hasani, and I.Q. Othman, *Effect of anemia on oral cavity and hematological assessments.* Diyala Journal of Medicine, 2024. **26**(1): p. 153–162.

[64] Kim, Y.-J., et al., *Topical administration of EGF suppresses immune response and protects skin barrier in DNCB-induced atopic dermatitis in NC/Nga mice.* Scientific Reports, 2018. **8**(1): p. 11895.

[65] Riedl, R., et al., *Establishment and Characterization of Mild Atopic Dermatitis in the DNCB-Induced Mouse Model.* International Journal of Molecular Sciences, 2023. **24**.

[66] Kim, M.J., et al., *The beneficial effects of ethanolic extract of Sargassum serratifolium in DNCB-induced mouse model of atopic dermatitis.* Scientific Reports, 2024. **14**.

[67] Hong, S., et al., *Solanum nigrum Linne improves DNCB-induced atopic dermatitis-like skin disease in BALB/c mice.* Mol Med Rep, 2020. **22**(4): p. 2878–2886.

[68] Al-Jabbar, W.A., et al., *Hesperetin Alleviate Renal Ischemia-Reperfusion Injury in Male Mice Model by Suppressing Inflammation & Oxidative Stress Pathway.* International Journal of Membrane Science and Technology, 2023. **10**(3): p. 410–420.

[69] Jiang, X., et al., *Topical Application of Fluoxetine Improves DNCB-Induced Atopic Dermatitis in Mice.* Experimental Dermatology, 2025. **34**(4): p. e70096.

[70] Motib, A.S. and H.M. Idan, *Effect of Vitamin D3 on Colonization Genes Expression of Haemophilus influenzae Isolated from Children with Otitis Media Associated with Temporomandibular Joint Pain.* Al-Kindy College Medical Journal, 2025. **21**(2): p. 136–142.

[71] Watanabe, T., et al., *Oral Administration of Lactic Acid Bacteria Isolated from Traditional South Asian Fermented Milk `Dahi' Inhibits the Development of Atopic Dermatitis in NC/Nga Mice.* Journal of Nutritional Science and Vitaminology, 2009. **55**(3): p. 271–278.

[72] Nagano, N., et al., *Immunohistochemical expression of filaggrin is decreased in proton pump inhibitor non-responders compared with proton pump inhibitor responders of eosinophilic esophagitis.* Esophagus, 2021. **18**: p. 362–371.

[73] Hassan, Z.Y., T.Y. Hassan, and A.R. Abu Raghif, *Evaluation the Effect of Phytosterol Fraction of Chenopodium Murale in Comparison with Tacrolimus on Mice Induced Atopic Dermatitis.* Iraqi Journal of Pharmaceutical Sciences, 2023. **32**(1): p. 84–91.

[74] Hameed, M.F., E.J. Kadhim, and A.R. Abu-Raghif, *Effect of topical artemisinin from artemisia annua in comparison with tacrolimus on induced atopic dermatitis in mice.* Journal of Global Pharma Technology, 2020. **12**(2): p. 447–453.

[75] He, S., et al., *Osthole ameliorates chronic pruritus in 2,4-dichloronitrobenzene-induced atopic dermatitis by inhibiting IL-31 production.* Chinese Herbal Medicines, 2025. **17**: p. 368–379.

[76] Kim, H.M., et al., *Morus alba fruits attenuates atopic dermatitis symptoms and pathology in vivo and in vitro via the regulation of barrier function, immune response and pruritus.* Phytomedicine, 2023. **109**.

[77] Tahir, A., *Ethnopharmacology, Phytochemistry, and Pharmacological Potential of Philenoptera laxiflora: An Emerging African Medicinal Plant for Drug Discovery.* Al-Mustaqbal Journal of Pharmaceutical and Medical Sciences. **4**(1): p. 3.

[78] Gether, L., et al., *Skin and systemic inflammation in adults with atopic dermatitis before and after whole-body topical betamethasone 17-valerate 0.1% or tacrolimus 0.1% treatment: A randomized controlled study.* Journal of the European Academy of Dermatology and Venereology : JEADV, 2025. **39**(2): p. 308–321.

[79] Rossi, M., et al., *Dupilumab Treatment Efficacy and Impact on Clinical Scores, Serum Biomarkers, and Itch in Adult Patients with Atopic Dermatitis: A Retrospective Analysis.* Journal of Asthma and Allergy, 2023. **16**: p. 1233–1240.

[80] Kim, H., et al., *7,8,4'-Trihydroxyisoflavone Attenuates DNCB-Induced Atopic Dermatitis-Like Symptoms in NC/Nga Mice.* PLoS ONE, 2014. **9**(8): p. e104938–e104938.

[81] Brunner, P.M., E. Guttman-Yassky, and D.Y.M. Leung, *The immunology of atopic dermatitis and its reversibility with broad-spectrum and targeted therapies.* The Journal of allergy and clinical immunology, 2017. **139**(4S): p. S65–S76.

[82] Kvedariene, V., M. Vaskovic, and J.B. Semyte, *Role of Oxidative Stress and Antioxidants in the Course of Atopic Dermatitis*, in *International Journal of Molecular Sciences*. 2025, Multidisciplinary Digital Publishing Institute (MDPI).

[83] Ji, H. and X.K. Li, *Oxidative Stress in Atopic Dermatitis.* Oxidative medicine and cellular longevity, 2016. **2016**.

[84] Najim, R.A., K.E. Sharquie, and A.R. Abu-Raghif, *Oxidative stress in patients with Behcet's disease: I correlation with severity and clinical parameters.* Journal of Dermatology, 2007. **34**(5): p. 308–314.

[85] Sharif, S.J., et al., *Gastroprotective effect of salvianolic acid B on rat model of diclofenac-induced gastric ulceration.* Comparative Clinical Pathology, 2026. **35**(1).

[86] Park, J.H., et al., *Combretum quadrangulare Extract Attenuates Atopic Dermatitis-Like Skin Lesions through Modulation of MAPK Signaling in BALB/c Mice.* Molecules, 2020. **25**.

[87] Langan, S.M., A.D. Irvine, and S. Weidinger, *Atopic dermatitis.* The Lancet, 2020. **396**(10247): p. 345–360.

[88] Weidinger, S. and N. Novak, *Atopic dermatitis.* The Lancet, 2016. **387**(10023): p. 1109–1122.

[89] Parga, A.D., et al., *Transdermal drug delivery systems in atopic dermatitis: A review of vehicle innovation and skin barrier challenges.* Cureus, 2025. **17**(10).

[90] Danby, S.G., et al., *Vehicles for atopic dermatitis therapies: more than just a placebo.* Journal of Dermatological Treatment, 2022. **33**(2): p. 685–698.

[91] Gatmaitan, J.G. and J.H. Lee, *Challenges and future trends in atopic dermatitis.* International journal of molecular sciences, 2023. **24**(14): p. 11380.

[92] Tribolet-de-Abreu, I., I. Pereira-Amaral, and P. Filipe, *Topical and systemic corticosteroids in the modern Management of Atopic Eczema: A scoping review.* International Immunopharmacology, 2026. **176**: p. 116477.

[93] Ingurgio, A., *Long-term topical corticosteroid treatment for atopic dermatitis: an in-depth analysis of safety, efficacy, withdrawal, and patient experiences.* Drugs & Therapy Perspectives, 2024. **40**(7): p. 269–275.

[94] Harvey, J., et al., *The long-term safety of topical corticosteroids in atopic dermatitis: a systematic review.* Skin health and disease, 2023. **3**(5): p. ski2. 268.

[95] Ghazy, D.N., et al., *Therapeutic Effect of Niclosamide versus Triamcinolone on Rabbit Ear Model of Hypertrophic Scar.* Aesthetic Plastic Surgery, 2026.

[96] Salman, R.A., et al., *Impact of antenatal steroid treatment on steroidogenic function and apoptotic remodeling in the suprarenal cortex of neonatal rats.* Pharmacia, 2026. **73**: p. e182945.

[97] Al-Rajhi, S.H., et al., *Protective effect of a combined glutathione and prednisolone administration on mice subjected to a lipopolysaccharide-induced cytokine storm.* Pharmakeftiki, 2025. **37**(2S): p. 122–126.

[98] Umar, B.U., et al., *Management of Atopic Dermatitis: The Role of Tacrolimus.* Cureus, 2022. **14**: p. e28130–e28130.

[99] Kraaijeveld, R., et al., *Inhibition of T Helper Cell Differentiation by Tacrolimus or Sirolimus Results in Reduced B-Cell Activation: Effects on T Follicular Helper Cells.* Transplantation Proceedings, 2019. **51**: p. 3463–3473.

[100] Pascual, J.C. and A.B. Fleisher, *Tacrolimus ointment (Protopic) for atopic dermatitis.* Skin therapy letter, 2004. **9**: p. 1–5.

[101] He, H., et al., *Comparison of anti-atopic dermatitis activities between DHMEQ and tacrolimus ointments in mouse model without stratum corneum.* International Immunopharmacology, 2019. **71**: p. 43–51.

[102] Mo Ku, J., et al., *The prevention of 2,4-dinitrochlorobenzene-induced inflammation in atopic dermatitis-like skin lesions in BALB/c mice by Jawoongo.*

[103] Wang, Y., et al., *Integrating tacrolimus into eutectic oil-based microemulsion for atopic dermatitis: Simultaneously enhancing percutaneous delivery and treatment efficacy with relieving side effects.* International Journal of Nanomedicine, 2019: p. 5849–5863.

[104] Walters, K.A. and M.E. Lane, *Dermal and Transdermal Drug Delivery Systems.* Dermal Drug Delivery, 2020: p. 1–60.

[105] Bernstein, Z.J., et al., *Engineering the IL-4/IL-13 axis for targeted immune modulation.* Immunological reviews, 2023. **320**(1): p. 29–57.

[106] Saeedavi, M., et al., *Sinapic acid ameliorates airway inflammation in murine ovalbumin-induced allergic asthma by reducing Th2 cytokine production.* Life Sciences, 2022. **307**: p. 120858–120858.

[107] Liu, F., et al., *Pingchuan formula improves asthma via restoration of the Th17/Treg balance in a mouse model.* BMC Complementary and Alternative Medicine, 2015. **15**(1): p. 234.

[108] Styrczewska, M., et al., *Use of natural components derived from oil seed plants for treatment of inflammatory skin diseases.* Current Pharmaceutical Design, 2019. **25**(20): p. 2241–2263.

[109] Xiang, S.-j., et al., *Altered metabolites in guinea pigs with allergic asthma after acupoint sticking therapy: New insights from a metabolomics approach.* Phytomedicine, 2019. **54**: p. 182–194.

[110] Noor Ahmed, A., et al., *Therapeutic effect of cilostazol in DNCB-induced atopic dermatitis in mice.* Journal of Advanced Biotechnology and Experimental Therapeutics, 2026. **10**(1): p. 02.

[111] Zhang, X., et al., *Myricetin alleviates DNCB-induced atopic dermatitis by modulating macrophage M1/M2 polarization.* International Immunopharmacology, 2025. **163**: p. 115212.

[112] Li, Y., J. Xie, and M. Liao, *Patchouli alcohol attenuates DNFB-induced atopic dermatitis-like inflammatory dermatitis associated with NF-κB/STAT6 signaling and macrophage polarization.* Molecular & Cellular Toxicology, 2026: p. 1–12.

[113] Furue, M., *Regulation of skin barrier function via competition between AHR axis versus IL-13/IL-4–JAK–STAT6/STAT3 axis: pathogenic and therapeutic implications in atopic dermatitis.* Journal of Clinical Medicine, 2020. **9**(11): p. 3741.

[114] Al-Oudah, G.A., et al., *Clinical and Anti-Oxidant Effect of Adding CoQ10 to Biological Therapy in Treating Moderate to Severe Psoriasis.* Iranian Journal of War and Public Health, 2024. **16**(2): p. 201–205.

[115] Gong, C., et al., *Investigating the mechanism of action of Yanghe Pingchuan Granule in the treatment of bronchial asthma based on bioinformatics and experimental validation.* Heliyon, 2023. **9**(11).

[116] Dębińska, A., *New treatments for atopic dermatitis targeting skin barrier repair via the regulation of FLG expression.* Journal of Clinical Medicine, 2021. **10**(11): p. 2506.

[117] Sehra, S., et al., *Increased Th2 activity and diminished skin barrier function cooperate in allergic skin inflammation.* European journal of immunology, 2016. **46**(11): p. 2609–2613.

[118] Yang, Z., et al., *Extraction and separation of sinapine from rapeseed cake and the mode of action of melanin production inhibition.* Molecular Biology, 2020. **54**(6): p. 911–918.

[119] Minzaghi, D., et al., *Excessive production of hydrogen peroxide in mitochondria contributes to atopic dermatitis.* Journal of Investigative Dermatology, 2023. **143**(10): p. 1906–1918. e8.

[120] Al-Oudah, G.A., et al., *MELATONIN AS AN ADJUNCTIVE THERAPY WITH ETANERCEPT FOR IRAQI PSORIATIC PATIENTS*. Gomal Journal of Medical Sciences, 2025. **23**(3): p. 313–317.

[121] Li, Y., et al., *Sinapine Improves LPS-Induced Oxidative Stress in Hepatocytes by Down-Regulating MCJ Protein Expression.* SSRN Electronic Journal, 2022.

[122] *Sinapine-enriched rapeseed oils reduced fatty liver formation in high-fat diet-fed C57BL/6J mice - RSC Advances (RSC Publishing) DOI:10.1039/D0RA00215A.*

[123] Liu, Y., et al., *Natural ingredients in the regulation of abnormal lipid peroxidation: a potential therapy for pulmonary diseases.* Frontiers in Pharmacology, 2024. **15**: p. 1507194.

[124] Zhang, Q., et al., *Induction of ferroptosis by natural products in non-small cell lung cancer: a comprehensive systematic review.* Frontiers in Pharmacology, 2024. **15**: p. 1385565.

[125] Sharquie, K.E., et al., *Oxidative stress in patients with premature hair grayness.* Saudi Medical Journal, 2005. **26**(8): p. 1310–1311.

[126] Alyoussef, A., *Arjunolic acid protects against DNCB-induced atopic dermatitis-like symptoms in mice by restoring a normal cytokine balance.* European Cytokine Network, 2015. **26**(2): p. 38–45.

[127] AlBairmani, R.J.H., et al., *D-limonene attenuates D-galactose-induced skin aging mouse model.* Journal of Molecular Histology, 2025. **56**(6): p. 364.

[128] Kantor, R. and J.I. Silverberg, *Environmental risk factors and their role in the management of atopic dermatitis.* Expert review of clinical immunology, 2017. **13**(1): p. 15–26.

[129] Zaniboni, M.C., et al., *Skin barrier in atopic dermatitis: beyond filaggrin.* Anais brasileiros de dermatologia, 2016. **91**(4): p. 472–478.

[130] Kezic, P.S., *Causes of epidermal filaggrin reduction and their role in the pathogenesis of atopic dermatitis.* Journal of Allergy and Clinical Immunology, 2014. **134**(4): p. 792–799.

[131] D'Avino, P., et al., *Distinct Roles of IL-4, IL-13, and IL-22 in Human Skin Barrier Dysfunction and Atopic Dermatitis.* Allergy, 2026. **81**(2).

[132] Furue, M., *Regulation of filaggrin, loricrin, and involucrin by IL-4, IL-13, IL-17A, IL-22, AHR, and NRF2: Pathogenic implications in atopic dermatitis*, in *International Journal of Molecular Sciences*. 2020, MDPI AG. p. 1–25.