Natural Resources for Human Health
eISSN: 2583-1194

Original Research

Received 24 July 2026
Revised 30 Aug 2026
Accepted 20 Sep 2026

Natural Resources for Human Health 2026, Vol. 6 (22s): 958-965

KEYWORDS:
electromagnetic field, Testicular tissue, histology, sperm

Changes of Testicular Functions in Adult Male Rabbit after Exposure to Mobile Phone Radiation

Nawal Badawi Ali Badawi[1], Nagwa S. Ahmed[2], Omyma G. Ahmed[3], Eman Mohamed Faruk[4]

[1]Assistant Professor of Medical Physiology, Medical Physiology Department, Al-Azhar University for Boys, Assiut Branch, Assiut Governorate, Egypt.
Email: nawalbadawi67@gmail
[2]Biochemistry Department, Faculty of Medicine Sohag, Sohag,
[3]Physiology Department, Faculty of Medicine Assiut, Assiut university,
[4]Department of Anatomy, Faculty of Medicine, Umm Al-Qura University, Makkah, Saudi Arabia Email: faruk_eman@yahoo.com, emkandel@uqu.edu.sa https://orcid.org/0000-0002-8963-790X.
Corresponding author: Eman Mohamed Faruk

ABSTRACT: Numerous organs are impacted by the cumulative effects of electromagnetic field (EMF) emissions from mobile phones. However, its impact on testicular function remains controversial. The study's goal is to elucidate the changes in testicular functioning following exposure to mobile phone electromagnetic radiation and to look into potential recovery.

Methods: Three groups of eighteen adult male rabbits are assigned: the control group, the exposed group, and the recovery group. For 14 weeks, they were exposed to cell phones in standby mode for eighteen hours a day, six days a week. For a further 14 weeks, the recovery group was observed.

Results: Sperm count, motility, and fast forward motility all significantly decreased after exposure to EMR on the sixth, twelfth and ninth weeks, respectively, with the greatest inhibition occurring on the fourteenth. These findings coincided with degenerative alterations in Leydig's interstate cells and seminiferous tubules. These detrimental effects could be explained by a discernible drop in testosterone and gonadotrophic hormone levels in the serum, an increase in oxidative stress, and direct degeneration of testicular tissue. Body and testicular weight is the other research point. There was no change in body temperature or the percentage of sperm morphology and live sperm. During the 14-week recovery period, the hormonal and oxidative indicators were restored and the inhibited testicular functions were much improved.

In conclusion: Long-term exposure to EMR results in testicular dysfunction, which may be mediated by hormonal imbalances. Testicular tissue may be directly damaged or undergo oxidative stress, which could be reversed and improved during the healing process.

INTRODUCTION:

The communication technology that permits wireless speech and data transmission through mobile devices, such smartphones, is known as mobile telephony. For convenient and portable connectivity, it depends on cellular networks. Cell phones, often known as mobile phones, are a very helpful and essential element of our everyday lives for communication. It has made telecommunication easier and solved the issue of communication amongst people who are on the go **(Jayram et al., 2024).**

According to **Assefa and Abdu (2025),** mobile phones emit electromagnetic radiation (EMR) while operating within a frequency range of 450 to 2,700 MHz. The quantity of radiofrequency energy that mobile phones' tissues absorb is measured by the specific absorption rate, or SAR. SAR values for cell phones vary from 0.12 to 1.6 W/kg body weight, depending on the model **(Kesari et al., 2010).**

The electromagnetic radiation that cell phones emit can be absorbed by the testes when they are carried in pockets close to the scrotum. This has sparked worries about possible negative health impacts on the testes and other male reproductive organs **(Karaman et al., 2014).** Numerous investigations have revealed that the testes—more especially, the Leydig cells—are extremely vulnerable to electromagnetic radiation exposure **(Xu et al., 2008).**

Radiation can be classified as either ionizing or non-ionizing, with the latter being further subdivided into radio frequency (RF) and extremely low frequency (ELF) or power line (60 Hz) electromagnetic field (EMF). Produced by products using microwaves and radio waves. Global public concern over the potential health effects of modulated radio frequency electromagnetic fields (RF-EMF) from base stations, cell phones, cordless phones, and Wi-Fi routers is growing **(Alghannam et al., 2021).**

The reproductive systems of both humans and animals are impacted by reactive oxygen species (ROS), which are created in reaction to increased EMR exposure. ROS and free radicals are also involved. Concern over EMR exposure is increasing as population fertility falls **(Kivrak et al., 2017).**

Testicular oxidative stress brought on by RFR exposure is typically linked to decreased sperm production as well as aberrant sperm function, sperm motility and structural problems, or poor sperm delivery **(Kesari et al., 2011).**

The aim of this study that MPs radiation may induce changes in testicular functions and stopping the exposure possibly may ameliorate these changes is to characterize the alteration of testicular functions after long term exposure to MPs radiation through monitoring sperm parameters (concentration, morphology, motility and viability), body temperature, hormonal levels (testosterone, FSH and LH), oxidative stress biomarker and testicular structure.

Also study the effect of recovery from exposure to EMFs on all previous parameters.

MATERIAL AND METHODS:

Animals and maintenance:

A total of 18 adult male White New Zealand rabbits (Nihon SLC, Hamamatsu, Japan), 20-weeks old and weighing 3.15–3.25 kg were enrolled in this study. They were obtained from Assiut University Animal Nutrition and Care House.

The experimental protocol was approved by the Institutional Animal Research Committee of the Faculty of Medicine, Sohage University, Egypt.

Rabbits were individually caged and kept in a temperature-controlled environment (22–24 _C) under a 12 h light/dark cycle (light on at 7:00 am).

Animals were provided standard rabbit chow and water.

Mobile phones: 12 mobile phones Phones used were conventional GSM (global system for mobile communications) MP handsets (800 MHz) which were turned to the standby position with an average strength of the electric field of 2.92 V/m, estimated at 0.5 cm away from the phone and 0.487 V/m at the most distant region inside the cage.

The MPs were applied for 18hrs. (2.00-8.00) per day and 6 days per week for 14 weeks.

Experimental Design: Animals were equally and randomly alienated into three groups. First group "control group" in which the rabbits were left throughout the time of the study in the conventionally available cages provided by the animal house. Second group "exposed group" placed individually in their cages and were exposed to mobile phones of the conventional GSM (global system for mobile communications) MP handsets (800 MHz) which were turned to the standby position with an average strength of the electric field of 2.92 V/m, estimated at 0.5 cm away from the phone and 0.487 V/m at the most distant region inside the cage. The MPs were applied for 18hrs. (2.00-8.00) per day and 6 days per week for 14 weeks. Third group "recovery group" was exposed to MPs similarly to the second group, after that they stopped exposure for another 14 weeks to study the possibility of recovery from the MPs radiation effects.

Rectal temperature assessment

This was carried out for all animals in this study twice per week. The check-up was made in the morning before and in the evening before removal of the MP.

Statistics analysis:

Data were expressed as mean ± SD. Statistical analysis was carried out using spss statistical software (SPSS 27 for Windows; SPSS Inc, Chicago, IL, USA), and non-parametric analysis with Mann–Whitney test was performed to examine the difference between each of the two groups and the longitudinal change within each group. A p-value <0.05 was considered to be significant.

RESULTS:

In this study, the effect of exposure to mobile phone EMFs on the testicular functions of adult male rabbits was studied. Semen analysis as well as hormonal assay (total testosterone, FSH & LH), testicular weights and histological examination of the testes were done and the results were recorded. The effect of recovery from exposure to EMFs on all previous parameters was also recorded.

A) **Effect of mobile radiation exposure on body weight gain and testicular weights:**

The present study showed that mobile radiation exposure didn't significantly affect body weight gain or testicular weight.

B) **Effect of exposure to mobile phone on semen analysis:**

In control group non-significant decline in sperm count, percentage of sperm motility and percentage of fast forward motility was observed throughout the experiment (Table 1-3).

1-Effect on sperm count (Table1): There was a signifcant decline (P<0.02) of sperm number from 205milions/ml at the baseline to 143 millions/ml at the 6th. Week (30% reduction) after 18hrs. /day exposure to MPs.

This decline progressed until it reached maximum at the 14th. Week (89.33millions/ml). The count dropped 56% relative to the value at the base line. During the period of recovery, sperm count increased significantly (P<0.03) from 73.17millions/ml at the baseline to 113.3millions/ml at 9th. Week of recovery (53.0% increase relative to the baseline value). This rise became more significant (P<0.000) and reached to 147.0 million/ml at the end of the 14th. Week recovery (100% relative those at the baseline).

2-Effect on sperm motility:

It is seen in Table (2) that motile sperm population significantly (P<0.01) dropped in the exposed group from 71.0% to 56.0% at the 12th. Week and reached 51.0% at the 14th. Week, p<0.005, relative to the baseline values. Whereas, there was a slight increase in motile sperm population in the recovery group that became significant (P<0.03) at the week (10% increase relative to the baseline).

3-Effect on sperm fast forward motility:

Exposure to MPs radiation induced a significant (P<0.01) decrease of the percentage ratio of sperm fast forward motility from 26.7% to 18.33% at the 9th. Week. This drop progressed and reached to 5.0% at the 14th. Week relative to the base line value. While in the recovery group it rose significantly (P<0.03) at the 11th. Week relative to the baseline (Table 3). Studying of sperm count and motility revealed a significant reduction of sperm number, % of sperm motility and fast forward motility in exposed group relative to those of control while in the recovery group a significant raise was detected only in the number of sperm relative to exposed group.

C) **Effect of exposure to mobile phone on biochemical parameters:**

1-Effect on serum testosterone, FSH and LH: Exposure MPs induced a significant reduction of serum total testosterone, FSH and LH level in the exposed group (0.41 vs. 0.82ng/ml, 0.33 vs. 0.39ng/ml and 0.25 vs. 0.35 ng/ml respectively) relative to the control values by 50% , 15% and 28% respectively. However, the levels of testosterone, FSH and LH increased by 50%, 9% and 32% respectively in the recovery group (Fig. 1).

2-Effect on oxidation stress biomarkers: It has been seen in Fig (2) that the plasma total lipid peroxide level was slightly higher but non-significant in exposed group (31.59 vs. 24.13 mmol Eq/L) relative to the control value, the increase was 31%. While its value slightly decreased to 22.67 m mol Eq/L (28%) in the recovery group when compared to the exposed group value. Upon measuring the plasma TAC , a significant (P<0.000) reduction was evident in the exposed group in comparison to the

control value (0.43 vs. 3.01 m mol Eq/L, 857%). For the recovery group the values of TAC showed a highly significant (P<0.000) rise to 1.96 m mol Eq/L (356%) when compared with exposed group. The oxidative stress index (OSI) was significantly (P<0.000) higher in exposed group (82.15 vs. 7.95) than in control group (932%) whereas, its value significantly (P<0.001) reduced to 12.04in the recovery group when compared with yhose of the exposed group (85%).

D) **Effect of exposure to mobile phone on histological structure of the testis:**

As Compared to the control testes examination of the exposed testes revealed the presence of seminiferous tubules with irregular outlines accompanied with marked degenerative changes with wide lumen. The interstitial space shows acidophilic exudates and mononuclear cell infiltration. Interstitial cells of Leyding are few in number, pale stained and vacuolated . After 14th. Week recovery period partial return of normal histological structure was observed (Fig 3).

DISCUSSION:

The rapid growth in the use of mobile phones has been accompanied by a parallel increase in electromagnetic field (EMF) density **(Alghannam et al., 2021).** The direct biological effect of EMF is the thermal effect of absorbing EMF energy through induced current or the thermal effect of long-term exposure **(Oh et al., 2018).**
Broad controversy was observed in the literature due to variable study design signifcant alteration of testicular function and sperm parameters **(Vignera et al.,2012).**
In current study exposure of the rabbits to the MPs can reveal several signifcant negative changes including progressive decline in sperm count, percentage of sperm motility and fast forward movement that appeared at the 6th. , 12th., and 9th. Week respectively. These results confirm a possible link between MP use and decreased semen quality and are in accordance with results **(Sharma et al., 2017).**
Exposure of mobile phone (EMR) decreased the total sperm count, living sperm cells and increased the percentage of abnormal sperm, sperm viability, motility, total antioxidant capacity, spermatogonia, spermatids and spermatogenesis. It also affected sperm head and caused significant changes in sperm morphology **(Oh et al., 2018).**
Research study done by **Tas et al,(2013)** show that exposure to mobile phone 900 MHz EMR was not affecting epididymal sperm concentration and sperm motility. Study done by Yaseen, in rats where mobile phone (EMR) exposure being in standing mode did not have any effects on sperm concentration and sperm morphology **(Yaseen, 2022).**
Some researches being done in rat shows that exposure of mobile phone radiation/2100 MHz RFR reduced the serum testosterone level, follicle stimulating hormone and luteinising hormone.11,16,25-27 Contrary above studies, Nisbet et al, shows that exposure to EMF 1800 MHz and 900 MHz increased the serum testosterone level in male Albino Wistar rats following exposure of 2 hours/day for 90 days **(Tas et al., 2013).**

Researches being done by various researchers show that exposure of mobile phone (EMR 900 MHz/1800 MHz/Wi-Fi 2.45 GHz RFR) increased the abnormal sperm cells in the semen sample and decreased the sperm motility sperm count, affected sperm morphology and sperm viability **(Rago et al., 2013).** According to **Al-Bayyari,(2017)** who conducted a study on 159 human male volunteers showed that exposure to EMR affected the sperm concentration, volume, viscosity and liquefaction time and sperm morphology and increased the immotile sperms in semen sample.

Some researchers reviewed that exposure of micro-wave/wifi/ mobile phone radiation affected sperm quality and viability their motility, morphology, count, leaky plasma membranes, calcium depletion and oxidative stress **(Adams et al., 2014).** Review article of Darvish et al, showed that the exposure to EMR affected the sperm motility, sperm viability, sperm morphology, volume, sperm density, and sperm fertility **(Darvish et al., 2021).**

In the current study, the hormonal levels of total testosterone, FSH & LH are estimated as they are mostly affected by the electromagnetic radiation (EMR) with disrupting spermatogenesis and decrease sperm production. The reduced total testosterone level is found to be obviously (50.0%) than that of FSH and LH (15% and 28% respectively) in exposed group which verify primary suppression effect on testosterone production. This result documented by the observed degenerative changes that appeared in Leydig cells of the exposed group. **Wang et al., (2003)** also suggested that Leydig cells are among the most susceptible cells to EMR, and injury to Leydig cells may directly explain the recorded lower testosterone hormone and indirectly interfere with spermatogenesis.

Regarding oxidative stress markers, this study showed that testicular malondialdehyde increased significantly in rats exposed to mobile radiation, and testis SOD and GPx antioxidant activities were significantly reduced.

La vigneira and others. (2012) revealed that the damage caused by electromagnetic radiation promotes increased ROS production. Regarding the consumption of antioxidants, electromagnetic radiation can overwhelm the defense system and cause cell damage and apoptosis **(Kesari et al., 2018).**

Furthermore, **Gautam et al. (2019)** Lipid peroxidation and neurodegeneration in rat testes were found to be enlarged and GPx antioxidant enzymes were reduced.

Contrary to published results, some studies have found the beneficial effects of ELF-EMF on male reproductive potential **Hori and colleagues (2005).** In addition, **Darbandi et al. (2018)**It is assumed that exposure to 50 Hz ELF-EMF for several hours may have a beneficial effect on sperm morphology and movement, while longer exposure or ELF-EMF with different characteristics will negatively affect sperm quality or no effect.

It has been suggested that the seminiferous tubules are the main target of the major histological and morphological changes that EMF exposure causes in the testicular parenchyma. Exposure to electromagnetic fields at different frequencies, such as 800 MHz and 2.45 GHz, is directly linked to a significant decrease in seminiferous tubule diameter, according to evidence from mouse models **(Çakmak et al., 2026).**

CONCLUSION AND RECOMMENDATION:

From this study we have verified that mobile phone radiation has detrimental impacts on male rabbits' testicular function based on the findings of the current study. The oxidative stress brought on by this radiation exposure alters the structure and function of the testicular tissue, resulting in modifications to sperm, sex hormones, and testicular tissue parameters.

REFERENCES:

[1] Adams JA, Galloway TS, Mondal D, Esteves SC, Methews, P. Effect of mobile telephones on sperm quality: A systematic review and meta-analysis. Environ Intern J. 2014; 70(1):106-12.

[2] Al-bayyari N. The effect of cell phone usage on semen quality and fertility among Jordanian males. Middle East Fertility Society J. 2017; 22:178-82.

[3] Assefa EM and Abdu SM . Histopathologic effects of mobile phone radiation exposure on the testes and sperm parameters: a systematic literature review of animal studies. Front. Reprod. Health.2025; 6:1515166.

[4] Darbandi M, Darbandi S, Agarwal A, Henkle R, Sadeghi MR.: The Effects of Exposure to Low Frequency Electromagnetic Fields on Male Fertility. Altern Ther Health Med. 2018; 24(4):24-29.

[5] Darvish L, Amraee A, Amjadi MA, Kashani ZA, Ghazanfarpour M, Roozbeh N, et al. The Impact of radiofrequency waves on male infertility: a systematic review. Shiraz E-Med J. 2021;22(3):1-9.

[6] Eser Çakmak , Birşen Bilgici1, Begüm Korunur Engiz & Adem Kocaman. Effects of wireless local area network exposure on testicular morphology and VEGF levels. Scientific Reports .2026. 16:6387

[7] Gautam R, Singh K, Nirala J, Murmu N, Meena R, Rajamani, P.: "Oxidative stress-mediated alterations on sperm parameters in male Wistar rats exposed to 3G mobile phone radiation. Andrologia 2019; 51(3): e13201.

[8] Hori T, Yamsaard T, Ueta YY, Harakawa S, Kaneko E, Miyamoto A et al.: Exposure of C57BL/6J male mice to an electric field improves copulation rates with super ovulated females. J. Reprod Dev. 2005; 51(3):393-7.

[9] Jayram, Mukesh Kumar, M. S. Srinivasa. Effect of mobile telephony on male reproduction: a review. Int J Reprod Contracept Obstet Gynecol. 2024 ;Oct;13(10):2983-2986

[10] Karaman MI, Gokce AM, Koca O, Karaman B, Ozturk MI, Yurdakul N, et al. The effects of electromagnetic waves emitted by the cell phones on the testicular tissue. Arch Ital Urolrol. 2014; 30:274–7.

[11] Kesari KK, Agarwal A, Henkel R: Radiations and male fertility. Reprod Biol Endocrinol 2018; 16(1):118-26.

[12] Kesari KK, Kumar S, Behari J. Mobile phone usage and male infertility in Wistar rats. Indian J Exp Biol. 2010; 48:987–92.

[13] Kesari KK, Kumar S, Behari J.: Effects of radiofrequency electromagnetic wave exposure from cellular phones on the reproductive pattern in male Wistar rats. Appl. Biochem. Biotechnol 2011; 164, 546–59.

[14] Kivrak, EG, Yurt KK, Kaplan AA, Alkan I, Altun G. Effects of electromagnetic fields exposure on the antioxidant defense system. J. Microsc. 2017; 5(4):167-76.

[15] La Vignera S; Condorelli RA, Vicari E, D'Agata R.Calogero AE. :Effects of the exposure to mobile phones on male reproduction: A review of the literature. J. Androl 2012; 33, 350–6.

[16] Mohamed A. Alghannam, Randa S. Gomaa, Eman R. Abozaid, Yasmeen A. A. Diab. Effect of exposure to cell phone radiation on testicular function of male albino rats. zumj.2021;78572.2248.

[17] Oh JJ, Byun SS, Lee SE, Choe G, Hong SK.: Effect of Electromagnetic Waves from Mobile Phones on Spermatogenesis in the Era of 4G-LTE. Biomed Res Int. 2018; 1801798.

[18] Rago R, Salacone P, Caponecchia L, Sebastianelli A, Marcucci I, Calogero AE. The semen quality of the mobile phone users. J Endocrinol Invest 2013; 36:970-4.

[19] Sharma A, Kesari KK, Verma HN, Sisodia R. Neurophysiological and behavioral dysfunctions after electromagnetic field exposure: a dose response relationship. In: Kesari K, editor. Perspectives in environmental toxicology. Basel, Switzerland: Springer International Publishing 2017; 01–30.

[20] Tas M, Dasdag S, Akdag MZ, Cirit U, Yegin K, Seker U, et al. Long-term effects of 900 MHz radiofrequency radiation emitted from mobile phone on testicular tissue and epididymal semen quality. Electromag Bio Med. 2013; 33(3):216-22.

[21] Vignera SL, Rosita AC, Enzo V , Rosario D, Aldo EC . Effect of the exposure to mobile phones on male reproduction. J. Androl. 2012;33(3), PP.350-6.

[22] Wang SM, Wang DW, Peng RY, Gao YB, Yang y, Hu WH. Effect of electromagnetic pulse irradiation on structure and function of Leydig cells in mice. Zhonghua Nan Ke Xue.2003; 9. PP. 327-30.

[23] Xu G, Intano GW, McCarrey JR, Walter RB, McMahan CA, Walter CA. Recovery of a low mutant frequency after ionizing radiation-induced mutagenesis during spermatogenesis. Mutat Res.2008; 654(2):150–7.

[24] Yaseen NJ. Effects of radiofrequency electromagnetic radiation of mobile phones on sperms shape and number in male albino mice. J Pure Appl Sci. 2022; 34(4):108-9.

Table (1): Time course monitoring of sperm count (millions/ml) in young male rabbits exposed to MPs for 14 weeks.

Week / Rabbit	Baseline	1st	2nd	3rd	4th	5th	6th	7th	8th	9th	10th	11th	12th	13th	14th
Control group	176.3 ± 8.28	170 ± 9.12	171.5 ± 10.42	165.5 ± 13.25	163 ± 17.8	166.7 ± 17.64	169.3 ± 16.99	180.8 ± 14.15	165.8 ± 12.56	163 ± 15.29	167 ± 15.27	173.7 ± 17.17	169.3 ± 16.65	167.8 ± 18.41	168.2 ± 13.35
Exposed group	205.2 ± 10.53	188 ± 3.54	186.2 ± 5	190.5 ± 9.53	186 ± 11.79	156.2 ± 23.3	143.7 ± 21.3 *	128.2 ± 22.55 *	135 ± 18.46 **	135.7 ± 20.12 *	120.7 ± 23.24 **	121.8 ± 28.1 *	118 ± 23.92 **	123.7 ± 25.68 *	89.33 ± 12.81 ***
% of change	↑ 16%	↑ 11%	↑ 9%	↑ 15%	↑ 14%	↓ 6%	↓ 15%	↓ 29%	↓ 19%	↓ 17%	↓ 28%	↓ 30%	↓ 30%	↓ 26%	↓ 47%
Mean ± SE	73.17 ± 10.77	71.5 ± 8.973	75.5 ± 10.79	75.33 ± 10.77	76.5 ± 10.5	76 ± 11.03	82.5 ± 9.2	80.83 ± 9.76	107.5 ± 4.23	113.3 ± 4.13 €	116.2 ± 4.11 €	127.8 ± 1.87 €€	149.3 ± 2.5 €€€	149.5 ± 2.85 €€€	147 ± 2.68 €€€
% of change	0	↓ 2%	↑ 3%	↑ 3%	↑ 5%	↑ 4%	↑13 %	↑13 %	↑47 %	↑55 %	↑59 %	↑75 %	↑104 %	↑104 %	↑101 %

Natural Resources for Human Health
eISSN: 2583-1194

Table (2): Time course monitoring of percentage ratio of sperm motility in young male rabbits exposed to MPs for 14 weeks.

Results are presented as: (the mean value ± SE) and were analyzed by a Student–3Newman–Keuls t-test.

Week / Rabbit	Baseline	1st	2nd	3rd	4th	5th	6th	7th	8th	9th	10th	11th	12th	13th	14th
Control group	71.67 ± 4.01	70 ± 3.65	70 ± 3.65	73.33 ± 4.22	71.67 ± 3.07	73.33 ± 3.33	70 ± 3.65	70 ± 4.47	73.33 ± 3.33	71.67 ± 3.07	71.67 ± 1.67	70 ± 2.58	68.33 ± 1.67	76.67 ± 2.11	73.33 ± 3.33
Exposed group	71.67 ± 4.01	68.33± 4.01	71.67± 3.07	71.67± 3.07	73.33± 3.33	70.00± 3.65	66.67± 2.11	63.33± 4.94	68.33± 3.07	68.33± 1.67	66.67± 3.33	65.00± 3.42	56.67 ± 3.33 *	55.00 ± 5 *	51.67 ± 4.01 **
% of change	0	↓ 2%	↑2%	↓ 2%	↑2%	↓ 5%	↓ 5%	↓10 %	↓ 7%	↓ 5%	↓ 7%	↓ 7%	↓17 %	↓28 %	↓30 %
Recovery group	48.33± 1.67	48.33± 1.67	45.00± 2.24	46.67± 2.11	43.33± 2.11	43.33± 2.11	48.33± 1.67	45.00± 2.24	43.33± 2.11	47.50± 1.71	49.17± 1.54	49.17± 1.54	51.67± 1.05	48.33± 1.05	53.33± 1.05
% of change	0	0	↓ 7%	↓ 3%	↓10 %	↓10 %	0	↓ 7%	↓10 %	↓ 2%	↑ 2%	↑ 2%	↑ 7%	0	↑10 %

SE = standard error.
% of change = percentage of change when comparing recovery group with their baseline (↑=increase, ↓=decrease).
Significant levels are: € P<0.05, €€ P<0.01, €€€ P<0.001 as compared recovery group of Rabbits with the baseline.

Table (3): Time course monitoring of percentage ratio of sperm fast forward motility in young male rabbits exposed to MPs for 14 weeks.

Week / Rabbit	Baseline	1st	2nd	3rd	4th	5th	6th	7th	8th	9th	10th	11th	12th	13th	14th
Control group	18.33 ± 3.07	20 ± 2.58	20 ± 2.58	20 ± 2.58	18.33 ± 1.67	25 ± 3.42	18.33 ± 1.67	20 ± 2.58	23.33 ± 2.11	20 ± 2.58	18.33 ± 1.67	20 ± 2.58	15 ± 2.24	18.33 ± 4.01	18.33 ± 4.01
Exposed group	26.67± 2.11	23.33± 2.11	23.33± 2.11	25.00± 2.24	23.33± 3.33	23.33± 2.11	21.67± 1.67	21.67± 1.67	21.67± 1.67	18.33± 1.67 *	18.33± 1.67 *	18.33± 1.67 *	8.33 ± 3.07 ***	8.33 ± 1.05 ***	5.00 ± 1.83 ***
% of change	↑45 %	↑17 %	↑17 %	↑25 %	↑27 %	↓7%	↑18 %	↑8%	↓7%	↓8%	0	↓8%	↓44 %	↓55 %	↓73 %
Recovery group	5 ±	3.33 ±	3.33 ±	2.5 ±	3.33 ±	4.17 ±	5.83 ±	6.67 ±	5.83 ±	6.67 ±	7.5 ±	8.33 ±	8.33 ±	8.33 1.05	8.33 ±

	1.83	1.67	1.67	1.12	1.05	0.83	0.83	1.05	0.83	1.05	1.12	1.05 €	1.05 €	€	1.05 €
% of change	0	↓33 %	↓33 %	↓50 %	↓33 %	↓17 %	↑17 %	↑33 %	↑17 %	↑33 %	↑50 %	↑66 %	↑66 %	↑66 %	↑66 %

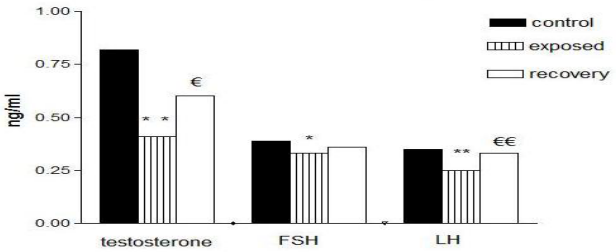

Figure (1): Comparison of hormonal levels of testosterone, FSH & LH in different groups at the end of experiment

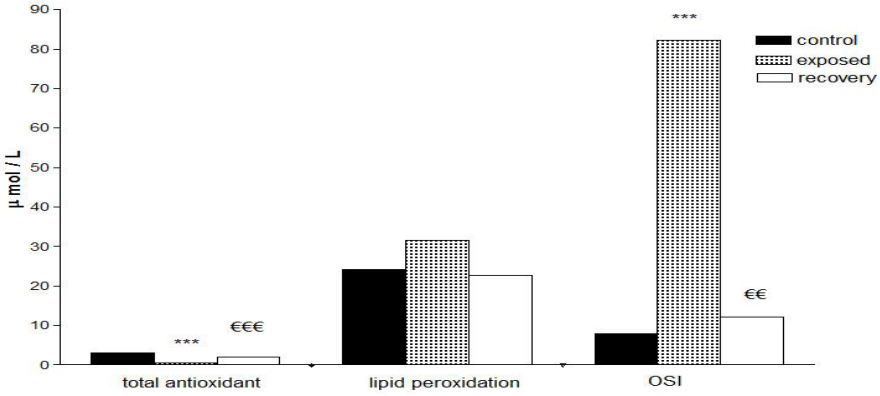

Figure (2): Comparison of oxidative stress index in different groups

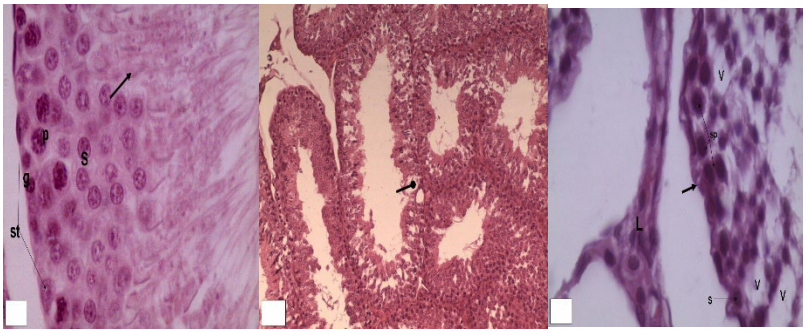

Control **Exposed** **Recovery**

Fig (3): A photomicrograph in testis of adult rabbit exposed to MPs for 14 weeks showing lost normal distribution of the epithelial lining. The cells showed marked cellular with irregular outlines and marked degenerative changes with wide lumen. Interstitial cells of Leydig are few in number, pale stained and vacuolated. After 14th. Week recovery period partial regeneration of germinal cells with return of normal histological structure was observed.