Natural Resources for Human Health

eISSN: 2583-1194

Original Research

Received 22 July 2026
Revised 28 Aug 2026
Accepted 10 Sep 2026

Natural Resources for Human Health 2026, Vol.6(22s): 841–852

KEYWORDS:
Arm wrestling, Scoping review, Radiology, Diagnostic imaging, Humeral shaft fracture, Fracture morphology, Radial nerve, Biomechanics.

Radiological Patterns of Arm-Wrestling Injuries: A Scoping Review of Injury Morphology, Imaging Findings, and Biomechanical Mechanisms

Ankita Kumari[1*], Inderpreet Kaur Saluja[2], Ishra Ajaz[3], Neha Kumari[4], Priya Singh[5], Sandeep Kumar[6]

[1,3,4,6] Assistant Professor, Department of Radiology & Imaging Technology (RIT), College of Allied Healthcare Sciences, T.S. Mishra University, Lucknow, UP
[5]Tutor, Department of Radiology & Imaging Technology (RIT), College of Allied Healthcare Sciences, T.S. Mishra University, Lucknow, UP
[2]BMRIT Scholar, Department of Radiology & Imaging Technology (RIT), College of Allied Healthcare Sciences, T.S. Mishra University, Lucknow, UP
Corresponding author: Ankita Kumari, Email-ankita.at9999@gmail.com

ABSTRACT:

Background: Arm wrestling can produce clinically important injuries despite being commonly regarded as a recreational test of strength. Humeral shaft fractures, particularly spiral fractures involving the distal third or middle-to-distal junction, are repeatedly described, but reports also document injuries around the elbow and associated neurological complications. The evidence spans clinical reports, observational cohorts, imaging studies, biomechanical models, and video-based analyses, which do not provide equivalent forms of evidence.

Objective: To map the published evidence on radiologically documented arm-wrestling injuries and examine how anatomical distribution, injury morphology, imaging findings, and associated complications have been related to proposed or observed biomechanical mechanisms.

Methods: The review framework uses the Population–Concept–Context approach and PRISMA-ScR reporting guidance. Planned sources are MEDLINE/PubMed, Embase, Scopus, Web of Science, and SPORTDiscus, where available. Formal searches, deduplication, and screening have not yet been completed in this draft; therefore, search totals and a final study-selection flow are not reported. The synthesis must be updated after the formal search and screening process.

Evidence map: Published reviews and clinical studies consistently describe spiral humeral shaft fractures, frequently in the distal third or at the junction with the middle third. Wedge or medial butterfly fragments and radial nerve palsy are also reported. Medial humeral epicondyle fracture-separation is an important pattern in adolescents. CT has been used for detailed fracture characterization and computational modelling; ultrasound has been reported for medial collateral ligament assessment. Recent video-based research associates fracture occurrence with trunk rotation and disruption of the hand–elbow–shoulder axis, but video cannot directly measure internal bone stress.

Conclusion: An imaging-centred synthesis should distinguish documented structural findings from mechanisms inferred through anatomy, modelling, or video. The final review will require completed reproducible searches and screening before its coverage and conclusions can be considered definitive.

1. INTRODUCTION

Arm wrestling is practised recreationally and competitively and exposes the upper limb to substantial muscular effort while the hand and forearm are constrained by an opponent's resistance. The combination of muscle-generated force, external resistance, limb position, and rapid changes in loading can produce musculoskeletal injury. Reported injuries include fractures, joint and apophyseal injuries, and less frequently described ligamentous or other soft-tissue damage. The clinical importance of these injuries is not limited to the initial structural lesion: associated neurological dysfunction, pain, loss of movement, and delayed return to activity may complicate recovery [1].

Humeral shaft fracture is the most frequently described serious injury in the published arm-wrestling literature. A systematic review by Ogawa and colleagues identified 153 patients across 57 studies. The reported fractures were almost uniformly spiral, and approximately 90% involved the distal third or the junction between the middle and distal thirds of the humerus. A medial butterfly fragment was reported in 48% of cases with the relevant data, while primary radial nerve palsy was reported in 19 of 103 patients (18.4%) for whom this outcome was available [2]. These figures describe selected published cases; they should not be interpreted as population incidence or as the absolute risk faced by people who arm wrestle.

The injury spectrum is broader than shaft fractures. A separate systematic review examined medial humeral epicondyle fracture-separation associated with arm wrestling, an injury of particular relevance in skeletally immature patients [3]. A case report has also described sonographic assessment of medial collateral ligament injury after arm wrestling [4]. Such reports indicate that imaging assessment should be guided by the suspected anatomical injury rather than assuming that all presentations share the same fracture pattern.

Imaging provides the structural description against which proposed mechanisms can be considered. Plain radiographs commonly establish fracture location, configuration, displacement, and alignment. CT may clarify complex osseous anatomy and can also provide geometry for computational biomechanical modelling. Ultrasound and MRI may be relevant when the clinical question concerns ligament, tendon, muscle, or selected nerve pathology. However, the number of reports involving a modality does not establish its comparative diagnostic accuracy or demonstrate that it should be used routinely in every case.

The proposed mechanism of humeral shaft fracture generally involves torsional loading generated by shoulder and arm muscle activity against an opposing force. A spiral fracture is mechanically compatible with torsion, but morphology alone cannot reconstruct the exact sequence of muscle contraction, limb motion, external resistance, and force transmission in an individual event. Clinical case reports, computational models, and video analysis address different parts of this process and must not be treated as interchangeable evidence.

Existing reviews have already synthesized the general injury spectrum and humeral shaft fractures [1,2], while another has focused on medial epicondyle fracture-separation [3]. The rationale for this review is therefore not to claim that arm-wrestling injuries have never been reviewed. Instead, it is to organize the evidence around the interface between imaging findings and proposed biomechanics, identify which observations are directly documented, and make clear where mechanistic interpretations remain indirect.

The review question is: "What radiologically documented injury patterns have been reported following arm wrestling, and how have these patterns been related to observed, measured, or proposed biomechanical mechanisms?" The objectives are to characterize anatomical distribution and morphology; map imaging modalities and their reported contributions; document associated neurological and soft-tissue injuries; distinguish direct observations from inferred mechanisms; and identify gaps in radiological reporting and biomechanical investigation.

2. MATERIALS AND METHODS

2.1 Review design and reporting

The review is designed as a scoping review because the available literature includes case reports, case series, retrospective cohorts, systematic reviews, imaging investigations, computational models, and video-based analyses. These sources address different questions and are unlikely to support a single pooled estimate. The purpose is to map the evidence and its characteristics rather than estimate population incidence or infer causal effects from heterogeneous studies. The final report should follow the PRISMA Extension for Scoping Reviews (PRISMA-ScR) [5].

Search execution, duplicate removal, title/abstract screening, full-text review, and data charting must be completed and documented before this draft can be reported as a completed scoping review. Accordingly, final record counts and PRISMA-ScR selection totals are not reported here and must be drawn from the completed review record.

2.2 Review question and PCC framework

The Population–Concept–Context framework is defined as follows. Population: individuals of any age or sex injured during recreational or competitive arm wrestling. Concept: radiologically documented injury, anatomical location, fracture or soft-tissue morphology, imaging modality, associated complications, and the relationship between findings and proposed mechanisms. Context: clinical, sports, recreational, experimental, and biomechanical settings relevant to arm-wrestling injury.

2.3 Information sources and search strategy

The planned databases are MEDLINE/PubMed, Embase, Scopus, Web of Science Core Collection, and SPORTDiscus, subject to institutional access. Reference lists of eligible studies and relevant reviews should be screened, and forward citation searching should be performed where feasible. Google Scholar may be used as a supplementary discovery source but should not substitute for reproducible database searches. Each database, platform, search date, and exact search string must be documented in the final report.

The preliminary PubMed strategy below combines arm-wrestling terms with injury, imaging, fracture, and biomechanical concepts:

("Arm Wrestling"[Mesh] OR "arm wrestling"[tiab] OR "arm-wrestling"[tiab] OR "wrist wrestling"[tiab] OR "Indian wrestling"[tiab] OR Skanderbeg[tiab]) AND ("Wounds and Injuries"[Mesh] OR "Fractures, Bone"[Mesh] OR "Diagnostic Imaging"[Mesh] OR "Radiography"[Mesh] OR "Tomography, X-Ray Computed"[Mesh] OR "Magnetic Resonance Imaging"[Mesh] OR injur*[tiab] OR fracture*[tiab] OR radiolog*[tiab] OR imag*[tiab] OR biomechanic*[tiab] OR torsion*[tiab] OR "mechanism of injury"[tiab])

This is a draft search string, not evidence that a formal search has already been conducted. It should be tested against known relevant publications and adapted to each database's syntax and indexing vocabulary. An additional broader search for arm-wrestling injury should be considered so that records that do not mention imaging in their title or abstract are not missed. Search dates and yields must be added only after execution.

2.4 Eligibility criteria

Eligible sources should include primary clinical reports, case series, observational studies, imaging investigations, experimental or computational biomechanical studies, and video-based analyses specifically concerning injury during arm wrestling or a mechanism relevant to such injury. Sources should provide information about anatomical location, injury morphology, imaging findings, associated complications, or a relevant mechanism. Case reports should be eligible because rare injuries and unusual imaging findings may otherwise be omitted.

Studies should be excluded if the injury mechanism is unrelated to arm wrestling, if they provide no usable information relevant to the review question, or if they are duplicate reports of the same dataset without additional relevant information. Reviews may be used to identify primary reports and to contextualize the field, but their patient totals should not be added to primary-study totals. Where several publications report overlapping cases, overlap should be assessed and described.

2.5 Study selection and data charting

After the searches are completed, records should be exported into reference-management software and deduplicated. Two reviewers should independently screen titles and abstracts, then assess potentially eligible full texts against the predefined criteria. Disagreements should be resolved by discussion or a third reviewer. If only one reviewer is available, the manuscript must state this transparently and describe any checking procedure used. Full-text exclusion reasons should be recorded, and the final flow diagram should report actual counts at each stage.

A standardized charting form should capture author and year, country, design, number of participants or cases, age and sex where reported, injury setting, anatomical site, imaging modality, fracture classification and morphology, associated neurological or soft-tissue injury, treatment or outcome where relevant, proposed mechanism, and study limitations. For

biomechanical studies, charting should also record whether loading was directly measured, modelled, visually observed, or inferred. Data should be checked against the source article before inclusion in the final tables.

2.6 Evidence categorization and synthesis

Evidence should be synthesized descriptively and thematically. Clinical imaging findings should be separated from mechanisms inferred from fracture morphology, anatomical reasoning, computational modelling, or video. For clarity, mechanisms may be classified as: directly measured, when forces or relevant physical variables are instrumentally measured; directly observed, when the injury event or body position is documented; model-derived, when estimates arise from a defined computational or experimental model; and hypothesized, when an explanation is proposed without direct measurement of the specific mechanism. These categories are intended to organize evidence, not to create a validated hierarchy of study quality.

The synthesis should cover anatomical distribution and morphology; modality-specific observations; neurological and soft-tissue complications; relationships between imaging and biomechanical explanations; and gaps in reporting. Numerical summaries should be reported only when denominators are clear and data are sufficiently comparable. Frequencies from case reports or selected cohorts should not be presented as population risk. If formal critical appraisal is not undertaken, this should be stated; the limitations of study design and reporting should still be considered when interpreting findings.

3. RESULTS: PRELIMINARY EVIDENCE MAP

Study-level characteristics are summarized in Table 1, while Table 2 maps reported injury patterns to imaging evidence, mechanistic interpretation, and diagnostic implications. Together, the tables distinguish documented findings from proposed mechanisms.

This preliminary synthesis maps studies identified through literature review and reference checking. The final evidence map and screening counts must be based on the completed database searches, deduplication, and formal study selection.

3.1 Dominant reported injury pattern

The most consistently described serious injury is a spiral humeral shaft fracture, commonly located in the distal third or at the junction between the middle and distal thirds. Ogawa and colleagues' systematic review included 153 patients from 57 studies and reported spiral configuration in nearly all included cases. A medial butterfly fragment was reported in 48% of cases with available information, and primary radial nerve palsy was recorded in 18.4% of patients for whom nerve status was reported [2]. These results provide a useful description of published cases but remain vulnerable to selection, publication, and incomplete-reporting biases.

A retrospective study of 27 young men reported distal-third spiral humeral shaft fractures in all patients and used radiographs, CT, and three-dimensional reconstruction for characterization [6]. In that cohort, radial nerve injury was reported in 7 of 16 patients with AO/OTA type 12-B2 fractures and in none of 11 patients with type 12-A1 fractures [6]. The small sample makes this an exploratory association rather than a validated prediction rule. Figure 1 provides an original schematic comparison of common spiral and wedge-fragment patterns [2,6].

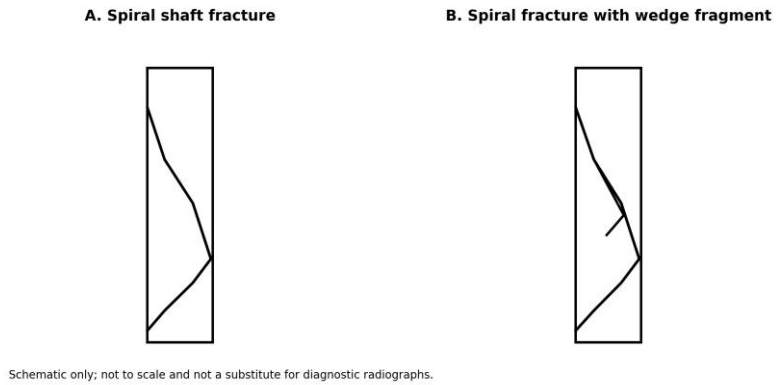

Figure 1. Schematic patterns of humeral shaft fracture reported in arm wrestling.

Source: Author-created schematic informed by published descriptions of fracture morphology [2,6].

3.2 Other anatomical patterns

Medial humeral epicondyle fracture-separation is a distinct pattern described in younger patients. A systematic review identified 68 patients across 27 studies, all boys, with a mean age of 14.6 years [3]. The developing skeleton and the attachment of the flexor–pronator musculature provide a plausible anatomical context for this injury, but the published case-based evidence does not establish age-specific incidence or comparative risk.

Soft-tissue injury is less extensively documented in the imaging-focused literature identified so far. Lee and colleagues reported sonography in the assessment of medial collateral ligament injury after arm wrestling [4]. A single case can demonstrate a possible diagnostic application but cannot establish how frequently ligament injury occurs or the diagnostic accuracy of ultrasound in this setting. The broader narrative review by Moloney and colleagues describes a wider range of bony and soft-tissue injuries, underscoring that a fracture-only synthesis would not represent the entire reported spectrum [1].

3.3 Imaging modalities and their reported contributions

Plain radiography is the central modality in published reports of humeral shaft fracture because it documents location, configuration, displacement, and alignment. CT and three-dimensional reconstruction have been used to characterize fracture anatomy in clinical cohorts [6]. CT-derived geometry has also supported biomechanical modelling of humeral fracture patterns [7]. The diagnostic role of CT should be distinguished from its research role: a model based on CT geometry estimates behaviour under specified assumptions and does not directly measure the forces experienced at the moment of injury.

Ultrasound has been described for selected elbow soft-tissue assessment [4]. The preliminary evidence identified for this manuscript contains much less arm-wrestling-specific MRI evidence than radiographic evidence for fracture. This finding should be treated as a gap in the identified literature, not proof that MRI is unnecessary. Modality choice in clinical practice should remain driven by the suspected structure and the diagnostic question.

3.4 Biomechanical evidence

The proposed explanation for humeral shaft fracture centres on torsional loading generated by internal rotator muscle activity against external resistance. Kruczyński and colleagues combined clinical radiological analysis with biomechanical modelling to examine humeral fracture mechanisms [7]. The model provides a plausible framework for considering stress distribution, but conclusions depend on the assumptions used to represent anatomy, material properties, and loading.

More recent video-based research analysed 74 arm-wrestling videos in which a humeral shaft fracture occurred and compared injured competitors with their uninjured opponents. Fractures were more frequent in the study's defensive zone, and trunk rotation and disruption of the hand–elbow–shoulder axis were associated with fracture occurrence [8]. These observations contribute information about visible position and movement. They do not directly quantify internal bone stress or establish that one observed posture alone caused fracture.

A 2026 questionnaire study of 46 competitive arm wrestlers reported self-recalled injury patterns and exploratory associations with technique [9]. Because injuries were self-reported and not independently verified clinically or radiologically, its findings should be treated as contextual evidence about athlete experience, not as imaging-confirmed injury prevalence.

Additional biomechanical and clinical reports extend this evidence map. Pedrazzini and colleagues combined CT, bone-density assessment, and strength-of-materials analysis to examine humeral geometry and the lower bone mineral concentration described in the distal third [10]. A four-patient case series included two oblique fractures, one spiral fracture, and one comminuted fracture; one patient had radial nerve injury, and the authors reported union in all four cases [11]. A separate retrospective cohort of 18 male military patients assessed humeral shaft fracture patterns and radiological and clinical outcomes [12]. These small or selected series add descriptive detail but do not establish population-level risk.

3.5 Overall character of the evidence

The identified literature combines secondary reviews, small clinical cohorts, case reports, biomechanical modelling, video analysis, and self-reported survey data. These sources complement one another but answer different questions. Clinical imaging establishes the structural lesion; clinical cohorts can describe associated findings and outcomes; models estimate stresses under assumptions; video studies document visible circumstances; and questionnaires capture reported experiences.

The completed review should preserve these distinctions and assess overlap between reviews and their underlying primary studies before reporting any aggregate totals.

Table 1. Characteristics of selected studies relevant to arm-wrestling injuries

Study	Design / evidence source	Evidence base	Imaging / assessment	Main contribution
Moloney et al. (2021) [1]	Narrative review	Published clinical reports; review-level denominator	Synthesis of bony and soft-tissue injury reports	Mapped the broader injury spectrum and discussed humeral fractures and nerve complications.
Ogawa et al. (2022) [2]	Systematic review	153 patients across 57 studies	Imaging reports and clinical descriptions	Summarized humeral shaft fracture morphology, location, fragments, and radial nerve palsy.
Ogawa et al. (2022) [3]	Systematic review	68 patients across 27 studies	Clinical and radiological reports	Reviewed medial humeral epicondyle fracture-separation, mainly in adolescent boys.
Lee et al. (2014) [4]	Case report	One patient	Sonography of medial elbow ligament	Demonstrated possible ultrasound assessment of medial collateral ligament injury.
Shen et al. (2023) [6]	Retrospective cohort	27 young men	Radiographs, CT, 3D reconstruction	Reported distal-third spiral fractures; compared 12-A1 and 12-B2 patterns and nerve findings.
Kruczyński et al. (2012) [7]	Clinical cases + biomechanical modelling	Nine clinical cases; CT-based model	Radiographs, CT-derived model, finite-element analysis	Explored fracture morphology and modelled stress distribution; elevated modelled stress reported near the distal humerus.
Öğümsöğütlü and Özcan (2026) [8]	Video-analysis study	74 publicly available injury videos	Video-based positional analysis	Reported associations with trunk rotation and hand–elbow–shoulder axis disruption.
Melkonyan and Petrosyan (2026) [9]	Athlete questionnaire	46 competitive athletes	Self-reported questionnaire; not independently radiologically verified	Contextual evidence on reported injury/technique; not imaging-confirmed injury morphology.
Pedrazzini et al. (2012) [10]	Biomechanical investigation	Adult arm-wrestling humeral-fracture biomechanical analysis; sample size not reported in the abstract	CT, bone-density assessment, strength-of-materials analysis	Examined humeral geometry and distal-third bone-density characteristics as possible contributors to fracture morphology.
Shivashankara et al. (2025) [11]	Case series	Four patients	Radiographic and clinical assessment	Two oblique, one spiral, and one comminuted fracture; one radial nerve injury; union reported in all four cases.

Study	Design / evidence source	Evidence base	Imaging / assessment	Main contribution
Yoo-Sun Won et al. (2025) [12]	Retrospective military cohort	18 male military patients	Radiological analysis and clinical follow-up	Described radiological fracture patterns and clinical/surgical outcomes in a selected military cohort.

Abbreviations: CT, computed tomography; 3D, three-dimensional. Patient totals from reviews should not be added to totals from their underlying primary studies unless overlap has been excluded.

Table 2. Injury morphology, imaging evidence, and diagnostic implications

Injury / region	Imaging or evidence source	Reported finding	Mechanistic interpretation	Diagnostic implication
Humeral shaft fracture [1,2,6]	Plain radiography	Spiral morphology; often distal third or middle-to-distal junction	Compatible with torsional loading; not mechanism-specific	Document site, orientation, displacement, angulation, and fragments.
Fracture with wedge fragment [2,6]	Radiography; CT/3D in selected cohorts	Wedge-fragment patterns, including AO/OTA 12-B2	May reflect more complex loading; exact sequence cannot be inferred from morphology alone	Describe fragment location/displacement and use classification consistently.
Possible radial nerve injury [1,2,6]	Radiography plus clinical neurological examination	Nerve palsy described in reviews and cohorts	Possible traction, contusion, compression, or entrapment	Correlate images with motor/sensory findings; radiographs do not prove nerve integrity.
Medial epicondyle fracture-separation [3]	Radiography; additional imaging if indicated	Reported particularly in younger patients	May involve force transmitted through medial elbow structures and a developing apophysis	Assess displacement, joint involvement, stability, and relevant nerve symptoms.
Medial collateral ligament injury [4]	Ultrasound/sonography	A case report describes sonographic assessment	Possible ligament loading; population frequency unknown	Consider targeted ultrasound when clinically indicated; evidence is case-based.
Complex osseous injury / modelling [6,7]	CT and 3D reconstruction; CT-derived computational model	More detailed fragment geometry; modelled stress distribution	Model output depends on geometry, material properties, and loading assumptions	Use CT selectively when added detail is expected to affect management.
Movement-associated fracture circumstances [8]	Video analysis	Associations with trunk rotation and hand–elbow–shoulder alignment	Observed position may be associated with injury but does not measure internal stress	Use as hypothesis-generating evidence, not a diagnostic test.
Self-reported technique-related injury [9]	Questionnaire	Recalled injuries and technique factors	Not direct evidence of radiological morphology or causation	Keep separate from imaging-confirmed injury data.

Abbreviations: AO/OTA, Arbeitsgemeinschaft für Osteosynthesefragen/Orthopaedic Trauma Association; CT, computed tomography; MRI, magnetic resonance imaging. Table note: The clinical implications summarize the limited arm-wrestling literature and general imaging reasoning; they are not a validated arm-wrestling-specific guideline.

4. DISCUSSION

4.1 Principal interpretation

The preliminary evidence map suggests that spiral humeral shaft fracture is the most consistently reported serious injury associated with arm wrestling, with a recurring distribution in the distal third or middle-to-distal junction. Other important patterns include medial humeral epicondyle fracture-separation in adolescents and selected elbow soft-tissue injuries. The central interpretive point is that injury morphology and injury mechanism are related but not synonymous: imaging documents the structural outcome, whereas the explanation for how it occurred requires additional evidence.

The systematic review of humeral shaft fractures provides the strongest descriptive summary currently identified, but its figures represent patients selected into published reports rather than all participants in arm wrestling [2]. The same caution applies to case reports and retrospective cohorts. A scoping review should therefore map what has been documented without claiming to quantify the population incidence of arm-wrestling injuries.

4.2 Interpreting fracture morphology

The fracture-pattern schematic in Figure 1 is an author-created explanatory illustration based on the morphology reported in clinical reviews and cohorts [2,6]; it is not a reproduced patient radiograph.

Spiral morphology is compatible with torsional loading, making rotational force a plausible component of the fracture mechanism. A wedge or butterfly fragment may indicate a more complex distribution of loading, including bending components, but fracture configuration is not a unique signature of a single force sequence. The observed morphology is influenced by limb position, bone geometry, muscle activation, external resistance, and the timing of changes in force. Consequently, the radiograph can support a biomechanical interpretation without proving every step of the causal sequence.

Computational modelling contributes a different kind of evidence. CT-based models can estimate stress distribution within a reconstructed bone under specified boundary conditions [7]. Their explanatory value depends on how accurately the model represents the individual's anatomy, material properties, muscle forces, and constraints. Model-derived stress values should not be reported as directly measured in-vivo forces. Future studies would be stronger if they documented model assumptions and tested whether the predicted stress concentration remained stable under plausible alternative loading conditions.

4.3 Radial nerve complications

Figure 2 provides a simplified anatomical orientation diagram to support this discussion; it should be interpreted as a schematic rather than a diagnostic depiction.

Radial nerve dysfunction is clinically important because the nerve lies in close anatomical relationship to the humeral shaft. The reported 18.4% frequency in the subset of cases with available data in Ogawa and colleagues' review indicates that nerve palsy is a recurring complication in published humeral shaft fracture cases [2]. The retrospective cohort by Shen and colleagues found more nerve injuries among patients with type 12-B2 fractures than among those with type 12-A1 fractures, but the sample was small [6]. The association should therefore be considered hypothesis-generating.

Radiographic proximity between a fracture fragment and the expected nerve course does not, by itself, establish nerve injury. Likewise, a relatively simple fracture appearance does not exclude a neurological deficit. Clinical assessment should document motor and sensory function, and imaging findings should be interpreted alongside examination and follow-up. Future studies should use standardized fracture classification and neurological outcome definitions to assess whether morphology independently predicts nerve complications.

Natural Resources for Human Health
eISSN: 2583-1194

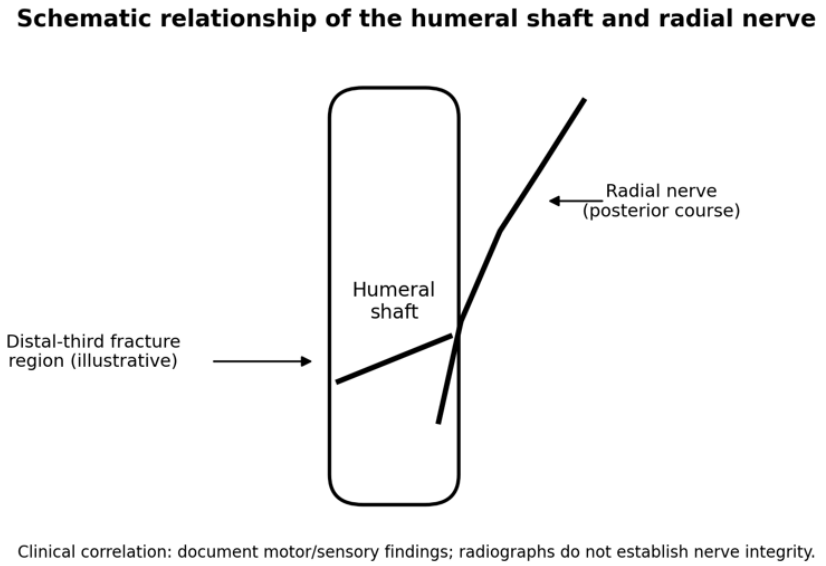

Figure 2. Schematic anatomical relationship between the humeral shaft and radial nerve.

Source: Author-created schematic informed by clinical reports of radial nerve complications [1,2,6].

4.4 Imaging beyond plain radiography

Radiography remains the starting point for suspected humeral shaft fracture because it establishes the fracture location and configuration. CT can provide additional detail when complex osseous anatomy is not adequately characterized or when the information is likely to affect management. Its use should be selective and justified by the clinical question rather than recommended routinely for every arm-wrestling injury. CT also has a research role in providing anatomical input for biomechanical modelling, but that role should not be confused with direct measurement of injury forces.

When symptoms are localized to the elbow or suggest ligamentous or tendinous pathology, the diagnostic question differs from that in an obvious shaft fracture. The reported use of ultrasound for medial collateral ligament assessment illustrates how targeted soft-tissue imaging may contribute in selected cases [4]. MRI may also be considered when clinically suspected soft-tissue injury remains unresolved after initial assessment. However, the arm-wrestling-specific evidence located in this preliminary map is insufficient to compare ultrasound and MRI performance or to support a universal imaging algorithm.

The practical implication is a question-driven approach: select the modality according to the suspected anatomical structure, the examination, and whether additional information is expected to change management. This is a clinically reasoned framework, not a validated arm-wrestling-specific guideline. The final review should describe the actual indications and findings reported in eligible studies rather than infer modality effectiveness from the number of publications.

4.5 Age and anatomical vulnerability

The medial epicondyle review suggests a distinct injury pattern in younger patients [3]. In adolescents, skeletal maturity and the anatomy of the apophysis may influence the response to force transmitted through the flexor–pronator attachment. The clinical lesson is not that age alone predicts a particular injury, but that the reader should consider the patient's skeletal development and the location of symptoms when interpreting elbow imaging.

The available reports do not provide a sound basis for estimating age-specific incidence or comparing injury rates between children, adolescents, and adults. Published cases are selected and denominators are generally unavailable. Larger registries or multicentre prospective datasets would be required to examine age-related patterns reliably.

4.6 Integrating movement and imaging evidence

Figure 3 summarizes the proposed relationship between muscular effort, external resistance, loading, and fracture morphology. It is conceptual and does not establish a unique causal sequence [2,6–8].

Video-based research adds observations about body position at the moment of fracture. In the 2026 study by Öğümsöğütlü and Özcan, trunk rotation and disruption of the hand–elbow–shoulder axis were associated with fracture occurrence in a comparison of injured competitors and their opponents [8]. These findings are consistent with the hypothesis that body position may influence the way forces are transmitted through the arm. Nonetheless, video records visible motion rather than internal tissue loading. Camera angle, recording quality, incomplete pre-injury sequences, and selection of publicly available injury footage may affect interpretation.

The most informative research strategy would combine multiple methods: radiographs or CT to characterize the resulting injury, high-quality video or motion capture to document movement, and validated biomechanical modelling or instrumentation to estimate internal loads. This integrated approach could test rather than simply repeat plausible mechanisms. It would also help distinguish a risk-associated posture from a posture that is merely present in a selected collection of injury videos.

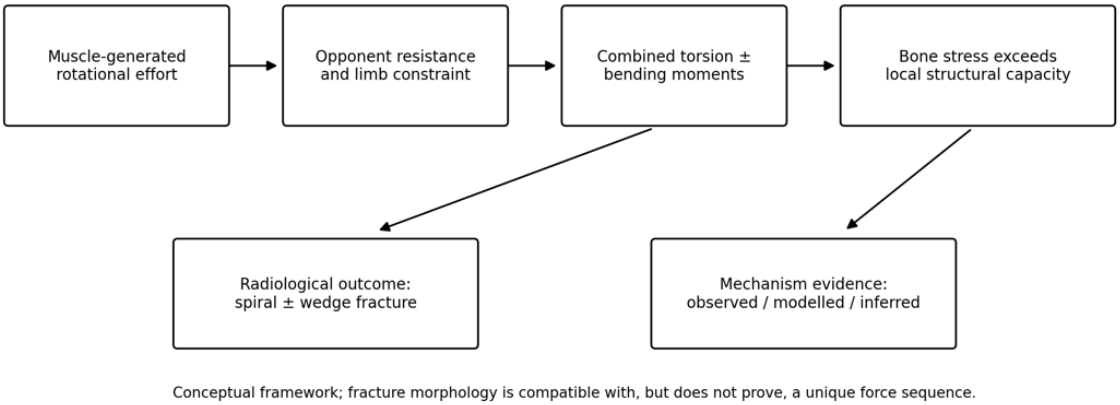

Figure 3. Conceptual pathway linking arm-wrestling loading to fracture morphology and evidence interpretation.

Source: Author-created conceptual framework informed by clinical and biomechanical investigations [2,6–8].

4.7 Reporting standards and future research

The literature would benefit from a minimum reporting dataset covering age, sex, arm involved, recreational or competitive setting, injury circumstances, anatomical site, imaging modality, fracture configuration and classification, displacement, associated fragments, neurological findings, treatment, and follow-up. Soft-tissue injuries should be described with the diagnostic method and reference standard stated explicitly. Reports should distinguish absent findings from findings that were not assessed.

Prospective multicentre data collection is likely to be more feasible than a single-centre study because severe arm-wrestling injuries are uncommon in many institutions. Standardized reporting could clarify whether particular fracture features are associated with radial nerve palsy and whether imaging findings correlate with recovery. Patient-centred outcomes—such as neurological recovery, range of motion, pain, return to activity, and disability—should be reported alongside radiographic union.

Biomechanical research should also make its assumptions transparent. Studies using CT-derived models should specify boundary conditions and material properties, while video studies should describe their sampling strategy, observer agreement, and operational definitions of body position. Questionnaire studies should identify self-reported outcomes as such and avoid presenting them as radiologically confirmed diagnoses.

4.8 Strengths and limitations

The principal strength of an imaging-centred review is its ability to organize clinical, radiological, and biomechanical evidence within a common framework while preserving the differences between them. This can clarify which injury patterns are repeatedly documented and which explanations remain indirect. Including non-fracture injuries also reduces the risk of treating humeral shaft fracture as the entire injury spectrum.

Several limitations apply to the preliminary evidence map and must be addressed in the completed review. Much of the clinical literature consists of case reports and small series, which are useful for describing uncommon patterns but weak for estimating incidence or comparative risk. Reporting varies across studies, and incomplete imaging or neurological data limit comparison. Publication bias may favour severe or unusual injuries. Secondary reviews may include the same primary cases, so their totals cannot simply be added together. Computational and video studies also have distinct methodological limitations and should not be pooled as though they measured the same exposure.

The main limitation at this stage is that the formal database search and study-selection process have not yet been documented as complete. Search dates, complete database-specific strategies, screening counts, full-text exclusion reasons, and the flow diagram must be finalized from the actual search and screening record before submission. The present synthesis should therefore be regarded as preliminary, and its conclusions revised if additional eligible studies materially alter the evidence map.

4.9 Clinical implications

The question-driven pathway in Figure 4 is a proposed educational framework informed by the limited injury-specific literature [2,4,6], not a validated guideline.

For clinical practice, the evidence supports careful assessment of the suspected anatomical injury and its complications rather than reliance on a single characteristic fracture pattern. Radiographs can define a suspected humeral shaft fracture, while a neurological examination is essential when radial nerve injury is possible. CT should be considered when additional osseous detail is clinically important. For elbow-dominant symptoms or suspected soft-tissue injury, ultrasound or MRI may be appropriate according to the suspected structure and clinical context.

These points are consistent with general imaging principles and the limited arm-wrestling-specific reports; they should not be interpreted as a formal protocol derived from comparative diagnostic trials. The present evidence does not establish the sensitivity or specificity of different modalities for arm-wrestling injury, nor does it justify routine advanced imaging in every patient.

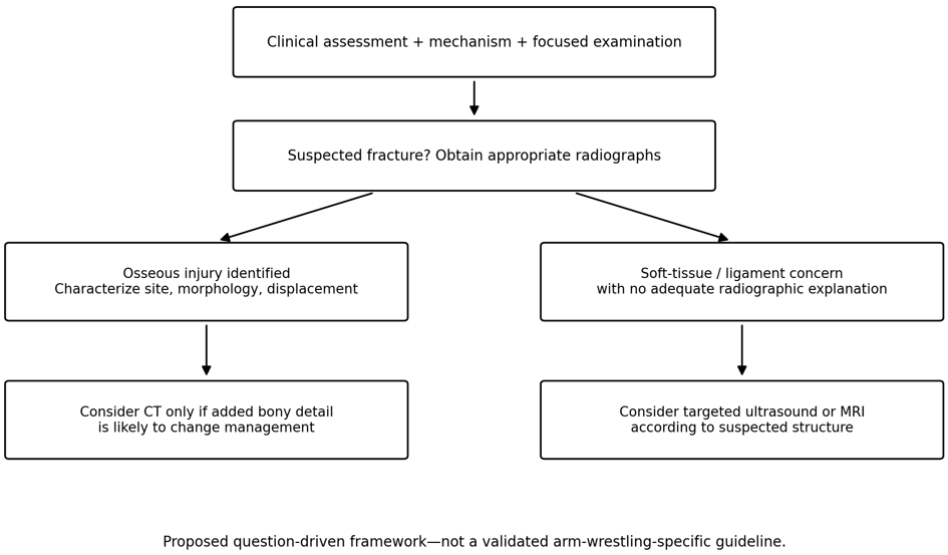

Figure 4. Question-driven imaging pathway for suspected arm-wrestling injury.

Source: Author-created framework informed by published fracture and soft-tissue imaging reports [2,4,6].

4.10 Implications for the completed scoping review

The final review should contribute an auditable map of the literature, not simply a narrative assertion that torsion causes spiral fractures. Its value will depend on transparent search and selection methods, accurate study-level extraction, consistent references, and a clear distinction between primary evidence and review-level synthesis. A structured evidence matrix linking

anatomical site, imaging findings, proposed mechanism, evidence category, and limitations could make this distinction especially useful to radiologists, orthopaedic clinicians, and biomechanical researchers.

5. CONCLUSION

Published reports most consistently describe spiral humeral shaft fractures following arm wrestling, often involving the distal third or the middle-to-distal junction. Medial humeral epicondyle fracture-separation, radial nerve complications, and selected elbow soft-tissue injuries broaden the recognized spectrum. Radiological morphology is essential for describing structural injury, but it cannot by itself establish the complete mechanism of failure.

Radiography is central to fracture assessment; CT may provide additional osseous detail or anatomical input for modelling, while ultrasound and MRI may be relevant to selected soft-tissue questions. Biomechanical models and video-based studies contribute complementary evidence, but their findings must be interpreted according to what was actually measured or observed. Future research should combine standardized imaging documentation, clinical outcomes, and validated biomechanical assessment.

This evidence map indicates recurring injury patterns but should not be treated as a completed scoping review until the planned database searches, deduplication, screening, and data charting have been completed and transparently reported.

REFERENCES

[1] Moloney DP, Feeley I, Hughes AJ, Merghani K, Sheehan E, Kennedy M. Injuries associated with arm wrestling: a narrative review. J Clin Orthop Trauma. 2021;18:30-37. doi:10.1016/j.jcot.2021.04.010.

[2] Ogawa K, Yoshida A, Matsumura N, Inokuchi W. Fractures of the humeral shaft caused by arm wrestling: a systematic review. JSES Rev Rep Tech. 2022;2(4):505-512. doi:10.1016/j.xrrt.2022.05.005.

[3] Ogawa K, Yoshida A, Matsumura N, Inokuchi W. Fracture-separation of the medial humeral epicondyle caused by arm wrestling: a systematic review. Orthop J Sports Med. 2022;10(5):23259671221087606. doi:10.1177/23259671221087606.

[4] Lee YS, Chou YH, Chiou HJ, Lai YC. Use of sonography in assessing elbow medial collateral ligament injury after arm wrestling. J Chin Med Assoc. 2014;77(3):163-165. doi:10.1016/j.jcma.2013.11.003.

[5] Tricco AC, Lillie E, Zarin W, O'Brien KK, Colquhoun H, Levac D, et al. PRISMA extension for scoping reviews (PRISMA-ScR): checklist and explanation. Ann Intern Med. 2018;169(7):467-473. doi:10.7326/M18-0850.

[6] Shen J, Yu P, Yang R, Li G, Sun Q, Cai M, et al. Clinical characteristics, mechanism, and outcome of humeral shaft fractures sustained during arm wrestling in young men: a retrospective study. Orthop Surg. 2023;15(6):1627-1635. doi:10.1111/os.13751.

[7] Kruczyński J, Jaszczur Nowicki J, Topoliński T, Srokowski G, Mańko G, Chantsoulis M, et al. Radiological and biomechanical analysis of humeral fractures occurring during arm wrestling. Med Sci Monit. 2012;18(5):CR303-CR307. doi:10.12659/MSM.882736.

[8] Öğümsöğütlü E, Özcan S. Trunk rotation and hand-elbow-shoulder axis disruption increase the risk of humeral shaft fractures during arm wrestling: a video analysis study. BMC Sports Sci Med Rehabil. 2026;18:338. doi:10.1186/s13102-026-01763-0.

[9] Melkonyan A, Petrosyan T. Injury patterns and technique-specific determinants in competitive arm wrestling: implications for performance-oriented rehabilitation. J Sports Med Phys Fitness. 2026;66(9):1068-1077. doi:10.23736/S0022-4707.26.18112-2.

[10] Pedrazzini A, Pedrazzoni M, De Filippo M, Nicoletto G, Govoni R, Ceccarelli F. Humeral fractures by arm wrestling in adult: a biomechanical study. Acta Biomed. 2012;83(2):122-126.

[11] Shivashankara, Nambiraj G, Chandraprakash R, Naidu DKE, Vaasan LS. Arm wrestling and humeral fractures: a case series. J Clin Diagn Res. 2025;19(2):RR01-RR05. doi:10.7860/JCDR/2025/74089.20668.

[12] Won YS, Min TH, Kwak WK, Kim JS, Ahn BH, Ha C. Humerus shaft fracture caused by arm wrestling injury in South Korean military: surgical outcome and radiologic analysis. Korean J Sports Med. 2025;43(1):23-29. doi:10.5763/kjsm.2025.43.1.23.