Natural Resources for Human Health
eISSN: 2583-1194

Original Research

Received 22 July 2026
Revised 26 Aug 2026
Accepted 12 Sep 2026

Natural Resources for Human Health 2026, Vol. 6 (22s): 760–769

KEYWORDS:
Necrotizing enterocolitis; Adult-onset ischemic enterocolitis; Diabetes mellitus; Mesenteric ischemia; Anastomotic leak; Case report.

Necrotizing Enterocolitis in an Adult Patient with Type 2 Diabetes Mellitus (A rare case in Iraq): A Case Report and Review of the Literature.

Dr. Saad Mohammed Hadbool *

M.B.Ch.B., C.A.B.S. \ (General Surgery Consultant)
Iraqi Ministry of Health, Al-Russafa Health Directorate, Al-Zafaraniyha General Hospital, Baghdad, Iraq.
* Corresponding Author: Dr.saadhadbool@yahoo.com

ABSTRACT: **Background**: NEC is well described in the neonatal population, but in adults, there is no clear clinical syndrome, uniform diagnostic criteria, and there are no reliable data for incidence. The most important contribution of this report is the documentation of a complete adult NEC trajectory from an initially unactioned computed tomography (CT) scan to a seemingly adequate primary resection and anastomosis, to the two-mutu" early second-look laparotomy for anastomotic failure, and finally to death, a failure pattern that is recounted in the sparse literature but rarely documented in such chronological and diagnostic detail.

Case Presentation: A 62 year old woman with type 2 diabetes mellitus and hypertension presented with a 2 day history of constipation, recurrent vomiting and a palpable, tender abdominal mass. Laboratory evaluation revealed mild anemia (hemoglobin 10.1 g/dL) and hyponatremia (132 mEq/L) and hypochloremia (89 mEq/L) consistent with her vomiting, and contrast enhanced CT of the abdomen showed bowel wall changes and distention, which was not acted upon at initial evaluation. She was then taken to the operating room for laparotomy and resection of the diseased bowel segment with primary anastomosis, which was reported as being consistent with NEC. She was discharged on postoperative day 7 in good condition, but readmitted 8 days later with anastomotic disruption and a colonic perforation at the hepatic flexure requiring enterostomy and colostomy. She passed away five days after re-operation, due to respiratory failure.

Results: This case illustrates three points of interest. First, bowel wall change and distension were noted on first presentation on first time using contrast enhanced CT, but this did not have any immediate clinical impact, and a definitive diagnosis was only made later, on histopathology of the resected specimen; this is broadly in line with the literature, which suggests that adult NEC is rarely diagnosed preoperatively. Secondly, although the index resection and anastomosis were macroscopically and clinically satisfactory and the recovery was adequate for discharge by postoperative day 7, anastomotic failure and perforation of the colon occurred within 8 days, showing that early apparent recovery does not rule out that the anastomosis is still poorly formed in this condition. Third, electrolyte disturbances at admission were hyponatremia and hypochloremia, which were more likely to be due to vomiting and not a diagnostic feature of NEC, thus demonstrating the non-specific laboratory profile of NEC at presentation.

Discussion: As with the limited number of case level reports that exist, adult NEC in this patient was not suspected prior to surgery and was not associated with a high risk of

Natural Resources for Human Health
eISSN: 2583-1194

anastomosis failure despite a seemingly adequate initial resection. The case is presented in the context of other published reports of adult intestinal necrosis related to vasculopathy, starvation, and neutropenia caused by chemotherapy, which collectively support the concept that adult NEC is a final common pathway of bowel ischemia and necrosis that is reached by multiple, different upstream mechanisms, rather than a single entity.

Discussion: The case highlights the non-specific presentation, common delay in diagnosis and high mortality associated with NEC in adults and the potential for anastomotic failure after a seemingly successful primary resection in a vasculopathic patient. It adds case-based information to a scarce body of literature, and provides a lower threshold for early surgical evaluation when CT shows bowel wall change and distention in a diabetic patient that has not responded to conservative treatment.

INTRODUCTION

Necrotizing enterocolitis is traditionally considered a disease of the neonatal gut, caused by an interplay between intestinal immaturity, ischemia, and bacterial translocation. NEC, which is the most frequent and deadliest of the gastrointestinal emergencies of the neonatal period, most often affects the premature and low-birth-weight infant (1). The neonatal nature, natural history, and management of NEC is well delineated in the pediatric literature (2).

The adult form of this NEC- like process is much less common and much less well documented. Because the clinical presentation of these adults does not have the defining criteria of prematurity, most publications are either isolated case reports or very small case series, and the pathogenesis and natural history of the adult disease are not well delineated. Proposed mechanisms include nonocclusive mesenteric ischemia, critical illness with bowel hypoperfusion, and bacterial superinfection of a previously injured bowel mucosa; a vasculopathic concomitant state has been proposed as a risk factor, as the associated microvascular disease and decreased perfusion and oxygenation of tissue can lead to mucosal hypoperfusion (3,4,5).

The absence of a distinctive clinical syndrome in adult NEC contributes to its common erroneous initial diagnosis, which is most often mistaken for another cause of acute or subacute abdominal pain, including ischemic colitis, diverticulitis, or even malignancy, in which case the diagnosis is not usually made until the specimen is examined histologically (6,7).

The literature also includes several related but Pathophysiologically distinct entities that are occasionally confused with adult NEC and should be separated at the outset. Neutropenic enterocolitis (synonymous with typhlitis) is a necrotizing process involving primarily the cecum and right colon that develops in the setting of chemotherapy-induced neutropenia, most commonly in patients with leukemia or following cytotoxic therapy for solid tumors; it has its own set of case series and reviews and may be successfully managed with early surgical resection and intensive critical care support if diagnosed early (8,9,10).

Another historically significant but now much less common entity is acute hemorrhagic necrotizing enteritis ("pigbel" or "Darmbrand" in the past), associated with C. perfringens type C toxin and outbreaks related to consumption of protein-heavy, undercooked meat in chronically malnourished populations. This is an established but now much less frequent cause of segmental hemorrhagic bowel necrosis unrelated to ischemic vasculopath that characterizes the above disorder (11,12,13).

The subject of this case report was not neutropenic, did not have a malignancy, was not exposed to chemotherapy, and did not have a history suggestive of a food-borne clostridial infection. Her individual risk factors of a decade-long history of type 2 diabetes mellitus and hypertension were more consistent with the ischemic, vasculopathic process thought to be the pathogenesis of adult NEC, relative to either of these related conditions (14,15). We report her clinical presentation and findings, including imaging, laboratory, operative, and reported histologic features, with the aim of further enriching the very limited literature about ischemic-type adult NEC and to shed light on features that may herald early diagnosis. This case report complies with the CARE (case report) guidelines for case report.

Study design:

Single-case retrospective case report of the presentation, investigations, radiological and operative findings, and reported histopathological appearance of a single adult patient with necrotizing enterocolitis, prepared in accordance with the CARE guidelines.

Data sources:

Patient hospital records (admission history and clinical examination findings, clinical laboratory investigations, radiological investigations, intraoperative operative notes and findings for the index laparotomy and the subsequent re-exploration, pathology report for the resected specimen, and clinical photographs from the index laparotomy), the complete blood count, serum biochemistry screen, plain abdominal radiograph, abdominal CT slices, and intraoperative clinical images included in this report are all reproductions from the patient's record; personally identifying information on these images (name, hospital record number, and hospital identifier) has been redacted or renamed, according to De-Identified Clinical Material policy.

Literature review: A narrative, non-systematic review of Pub Med/MEDLINE and Google Scholar of the relevant literature using the key search words ("necrotizing enterocolitis", "adult", "adult-onset", "neutropenic enterocolitis", and "case report") has been performed, in order to contextualize this particular patient's presentation, test results, and clinical course within the wider medical literature, and to define the general pattern in which this disorder, and related entities, are reported, diagnosed, and managed in adults; references of papers identified in Pub Med searches were reviewed for additional relevant citations.

This review was only performed for the purposes of contextualizing the present case; it does not constitute a systematic review or meta-analysis, and no figures of overall incidence or prevalence are quoted.

Ethical considerations: Information with the potential to identify the patient has been excluded, anonymized, or anonymized in each of the presented clinical photographs; next-of-kin consent was obtained for this report, as the patient was deceased.

Limitations:

As this study is based on one case, all and only published, retrospective, hypothesis-generating conclusions should be made; no definitive conclusions or evidence-based causality may be derived from a single case. Formal, digital photographs of histological slides have not been provided to us for study, and so the published histological appearance of the necrtoizing enterocolitis process was determined from the original pathology report.

Case Presentation

Patient Information

The subject of this case was a 62-year-old female patient with the history of type 2 diabetes mellitus and hypertension who presented to the hospital with two days of constipation accompanied by persisting episodes of vomiting.

Medical, Surgical, Social and Family History

In addition to the type 2 diabetes mellitus and hypertension mentioned above, History of previous havy smoking, non-alcoholic, no family history of chronic bowel diseases or malignancies.

Clinical Findings

On examination, the patient was fully conscious, alert, and oriented; her chest examination was negative. The abdomen was tensed and distended, and during the examination of the abdomen, a palpable and tender mass was noted. Vital signs of the patient were stable, including blood pressure of 130/80 mm Hg, oxygen saturation of 99 %, and heart rate of 90 beats/min. Digital rectal examination was normal, with no fecal impaction.

Diagnostic Assessment

Imaging

CT scan of the abdomen with contrast was conducted to assess the bulge and swelling in the belly (Figures 1 and 2). An X-ray taken at the time to confirm the admission (Figure 3) showed distended loops of the intestines, consistent with the observation of the bloated belly. An image showing the lifting of the patient on the CT machine is provided as part of the study (Figure 4).

Natural Resources for Human Health
eISSN: 2583-1194



Figure 1. Axial contrast-enhanced CT of the abdomen at presentation, obtained to evaluate the palpable abdominal mass and distension. Patient-identifying header information has been redacted (black bars) prior to reproduction.

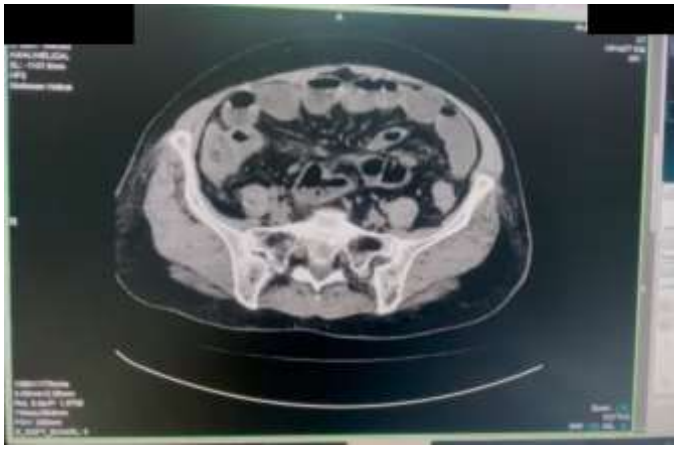

Figure 2. Axial contrast-enhanced CT of the abdomen, a further level from the same study, showing bowel loops and distension prompting surgical evaluation. Patient-identifying header information has been redacted (black bars) prior to reproduction.



Figure 3. Supine plain abdominal radiograph obtained during the same admission, showing dilated small bowel loops consistent with the observed abdominal distension.

Natural Resources for Human Health
eISSN: 2583-1194



Figure 4. CT scout (topogram) image from the same imaging study, shown for completeness. Patient-identifying header information has been redacted prior to reproduction.

Laboratory Investigations

The biochemical and serological examination of blood (as represented in tables below) indicates the level of blood sugar to be 88 mg/dL, urea in the blood to be 41.5 mg/dL, and serum creatinine to be 0.50 mg/dL as well, all still in their ordinary limits. Serum sodium shows a mild decrease to 132 mEq/L (normal level: 134–155), while chloride is found to be 89 mEq/L (normal level: 98–107); hence, the occurrence of hyponatremia and hypochloremia in the case is attributed to the repeated vomiting. The potassium levels stay normal at 3.9 mEq/L (normal levels: 3.6–5.4), without any information regarding serum troponin and total bilirubin in serum mentioned in the documents.

Test	Result	Unit	Min	Max	% within range
WBC (White Blood Cells)	7.7	$10^3/mm^3$	4.1	10.5	56.25
LYM% (Lymphocytes %)	23.7	%	16	43.3	28.20512821
MON% (Monocytes %)	5.5	%	2.8	10.2	36.48648649
GRA% (Granulocytes %)	70.8	%	48.5	80.3	70.12578616
LYM# (Lymphocytes count)	1.8	$10^3/mm^3$	1	3.1	38.0952381
MON# (Monocyte count)	0.4	$10^3/mm^3$	0.1	0.7	50
GRA# (Granulocyte count)	5.5	$10^3/mm^3$	2.3	7.7	59.25925926

Test	Result	Unit	Min	Max	% within range
RBC (Red Blood Cells)	3.57	$10^6/mm^3$	4.3	5.8	-48.66666667
HGB (Hemoglobin)	10.1	g/dl	13.1	16.7	-83.33333333
HCT (Hematocrit)	29.9	%	39.9	51	-90.09009009
MCV	84	μm^3	83	98	6.666666667
MCH	28.2	pg	27	32.2	23.07692308
MCHC	33.6	g/dl	31.8	33.7	94.73684211
RDW	13.2	%	11.9	14.8	44.82758621

Test	Result	Unit	Min	Max	% within range
PLT (Platelets)	161	$10^3/mm^3$	150	399	4.417670683
MPV	7.4	μm^3	6.8	10.1	18.18181818
PCT	0.12	%	0.15	0.5	-8.571428571

Diagnostic Difficulties

It was difficult to arrive at a proper diagnosis based on the presentation of constipation accompanied by vomiting and the discovery of an abdominal mass, as there were no decisive indications pointing toward necrotizing enterocolitis. In fact, considering the differential diagnosis at the time of presentation, it seemed more likely that a diagnosis of mechanical bowel obstruction or that of an intra-abdominal mass lesion would be justified(16). The initial CT showed changes in the gut and dilatation through the use of contrast, but no particular actions were taken at this stage, and the patient continued to be treated solely based on the symptoms of the disease until the mass was detected and surgical intervention was completed. In line with most other cases reported with adult patients, a conclusive diagnosis was confirmed only after removal of the part of the bowel.

Treatment Procedures

During the operation, the surgeon founded multiple perforations at the jejunum and ileum with dusky bowel. resection done with end-to-end anastomosis.

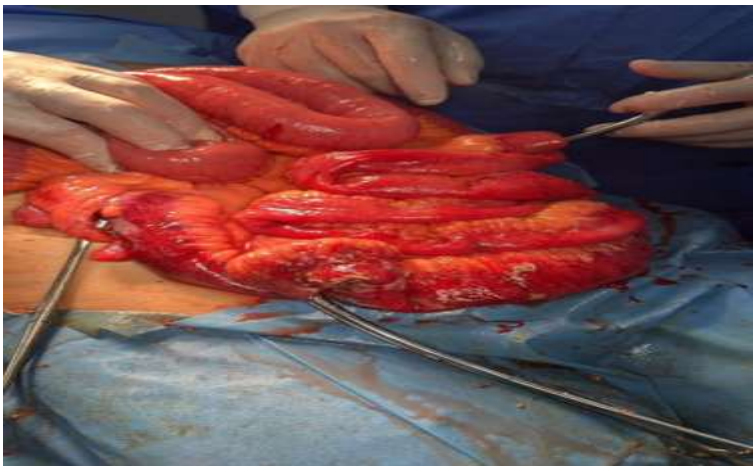

Figure 7. Intraoperative photograph showing the exposed small bowel with the diseased anastomosis....d in atraumatic clamps prior to resection.



Figure 8. Intraoperative photograph taken during resection and preparation of the bowel ends, showing hemorrhagic, edematous bowel consistent with the operative impression of necrotizing enterocolitis.

Natural Resources for Human Health
eISSN: 2583-1194

Follow-up and Outcomes

The patient was discharged well after 7 days with normal bowel motion & vomiting, but later she was readmitted having suddenly developed acute abdominal pain. On reoperation, anastomosis distruption with new perforation in the colon. An enterostomy and colostomy were performed to allow diversion of the fecal stream and to keep contamination at bay. However, her condition worsened postoperatively due to respiratory failure, and five days later she passed away. On histopathological investigation, the bowel that was resected earlier showed signs of necrotizing enterocolitis, and once the patient's specimen was cultured, it was further determined what type of necrosis the bowel had.

Timeline

Table 1. Chronological timeline of presentation, investigation, intervention, and outcome, establishing the temporal relationship between the index operation and the fatal anastomotic failure.

Event	Timing	Details
Presentation to hospital	Day 0	Two-day history of constipation and recurrent vomiting; tense, distended abdomen with a palpable mass; vital signs stable.
Laboratory testing and CT abdomen	Day 0	CBC and biochemistry panel obtained; contrast-enhanced CT showed bowel wall changes and distension (Figures 1–2). Findings not acted upon initially.
Index laparotomy	Later in the same admission	Resection of diseased bowel segment; primary side-to-side anastomosis; peritoneal lavage; drain placed.
Hospital discharge	Postoperative day 7	Discharged home in good condition.
Readmission	8 days after discharge	Sudden onset of acute abdominal pain.
Re-exploration	Same readmission	Anastomotic disruption and colonic perforation at the hepatic flexure; enterostomy and colostomy fashioned.
Death	5 days after re-operation	Death due to respiratory failure.

Discussion

In accordance with the literature exploration mentioned in the Methodology, necrotizing enterocolitis in adults has been reported only as individual case reports. There is no epidemiological registry to determine its true global prevalence in a more reliable manner. The lack of reports published shows the rare occurrence of this condition and its difficulty to be diagnosed in vivo, since adult NEC does not appear as a special syndrome and is recognized post factum by histopathological analysis of the resected sample (17,18).

It is essential to refer to the case at hand in the context of other diseases mentioned in the publications connected to necrotizing and hemorrhagic bowel damage in adults, as they are often treated as one combined pathology. Cunningham et al. and Alt et al. investigated neutropenic enterocolitis (typhlitis) as a necrotizing process of the cecum and right colon that happens after chemotherapy, while Gorschlüter et al. made the same conclusion about the connection of rinsing and enterocolitis with the presence of neutropenia rather than problems in the vascular system (19,20).

According to the review conducted by Zeng et al., acute hemorrhagic necrotizing enteritis is an illness associated with the Clostridium perfringens organism, and this illness is historically related to the consumption of protein-rich, poorly cooked food by malnourished persons. The mechanisms described above were, however, not present in a patient described in the current article, who showed no signs of chemotherapy -related neutropenia and lacked any major risk factors associated with clostridial foodborne disease (21). Overall, her clinical presentation was more in line with the findings published by Gupta et al., who reported on a woman with ischemia-related gangrene of her small intestines and cecum as well as ascending colon. The findings of Schapira et al. were also relevant to the case described in the article; they described necrotizing enterocolitis occurring in adults suffering from anorexia nervosa, with the authors responsible for this study suggesting the possibility of starvation-induced reduction of blood flow to the bowel as a potential cause of this condition (22,23,24,25). Overall, the information presented in these studies provides more evidence that necrotizing enterocolitis among adults should be attributed to ischemic conditions occurring in the gut under various situations rather than being considered a uniform disease where also found The patient's type 2 diabetes mellitus is pertinent in this regard. Diabetes is linked with microvascular conditions and insufficient tissue perfusion, which might promote bowel ischemia and additional necrotic alterations; similarly, Silva and Gounder considered a case of an adult patient with uncontrollable type 2 diabetes and recurrent bowel necrosis caused by non-occlusive mesenteric ischemia with diabetic ketoacidosis, which led to death. While the patient in question did not suffer from ketoacidosis, the implications of the diabetic vasculopathy and the case of non-occlusive mesenteric ischemia provide a good explanation for the bowel problems observed during the surgery.

Regarding the laboratory test results in this case, which are mild anemia with a combination of hyponatremia and hypochloremia, it is worth mentioning that those findings can be correlated with the recurrent vomiting history provided in previous paragraphs.

The patient was initially diagnosed presenting symptoms like constipation, vomiting, and a significant abdominal mass that could not be attributed to NEC. It was only after the resection and histopathological review that the actual diagnosis was made. This was a common theme noted in earlier cases of adult NEC where the true diagnosis is usually reached in post-operative specimens.

The case illustrates the serious complications observed in this patient despite a successful operation. The patient's recovery lasted long enough for him to be discharged after his surgical procedure. After a short interval, the patient came back to the hospital due to intestinal perforation requiring further surgery in the form of enterostomy and colostomy. The mentioned fact points to the need of extra vigilance in postoperative management of patients with adult NEC. Another issue highlighted by this case is the inadequate use of CT findings at presentation. While abdominal CT is not valuable in diagnosing NEC in adults, the presence of bowel wall changes and distension in the patient with the mass in the abdomen should prompt additional surgical evaluation, since a patient who suffers from diabetes or other vascular disease should not be accepted for conservative management. The opposite case of Schapira et al. — in which the problem was recognized and treated promptly — produced a good outcome.

The main strengths

The most favorable sides of this research are the existence of a full-time chronologically documentable clinical history from the date of the diagnosis until death, which includes timely evidence both from the imaging and laboratory data, as well as data from the surgical process, thus helping to establish the temporal relation between the prime operation and the occurrence of the anastomotic malfunction with enough reliability.

The main limitations

The major downsides of the report are those which are common to every separate case report: it cannot demonstrate any relation of causality or provide data for incidence rate and, moreover, many aspects of the surgery, social and family backgrounds are absent in the presented materials – no formal histopathology slides were available for the research purposes as well.

Conclusion

Necrotizing enterocolitis in adults is a rare and often fatal condition that is difficult to diagnose preoperatively and is typically confirmed only on histopathology of a resected bowel segment. This case, in a 62-year-old woman with diabetes and hypertension, illustrates the nonspecific initial presentation, the risk of anastomotic failure even after apparently successful

primary resection, and the high mortality associated with this diagnosis. Continued reporting of individual cases such as this one remains important for building a clearer clinical picture of adult NEC and for informing future management strategies.

References

[1] Good, M. M., & Sodhi, P. C. P. (2013, May). Mechanisms of gut barrier failure in the pathogenesis of necrotizing enterocolitis: Toll-like receptors throw the switch. In Seminars in Pediatric Surgery (Vol. 22, No. 2, pp. 76-82). WB Saunders.

[2] Sharma, R., Tepas III, J. J., Hudak, M. L., Mollitt, D. L., Wludyka, P. S., Teng, R. J., & Premachandra, B. R. (2007). Neonatal gut barrier and multiple organ failure: role of endotoxin and proinflammatory cytokines in sepsis and necrotizing enterocolitis. Journal of Pediatric Surgery, 42 (3), 454-461.

[3] Neu, M. J., Chen, M. M., & Beierle, M. E. (2005, August). Intestinal innate immunity: how does it relate to the pathogenesis of necrotizing enterocolitis. In Seminars in Pediatric Surgery (Vol. 14, No. 3, pp. 137-144). WB Saunders.

[4] Grishin, P. A., Papillon, M. S., Bell, B. B., & Wang, M. J. (2013, May). The role of the intestinal microbiota in the pathogenesis of necrotizing enterocolitis. In Seminars in Pediatric Surgery (Vol. 22, No. 2, pp. 69-75). WB Saunders.

[5] Eaton, S., Rees, C. M., & Hall, N. J. (2017). Current research on the epidemiology, pathogenesis, and management of necrotizing enterocolitis. Neonatology, 111 (4), 423-430.

[6] Yue, M., Wang, W., & Zhang, K. (2026). Clinical features of acute and chronic abdominal pain in children admitted to gastroenterology unit. BMC Gastroenterology.

[7] Uberti, M. G., Goldblum, M. J. R., & Allende, M. D. S. (2014, March). Ischemic enterocolitis and its differential diagnosis. In Seminars in Diagnostic Pathology (Vol. 31, No. 2, pp. 152-164). WB Saunders.

[8] Koca Yozgat, A., Kilçik, R. D., Çetin, S., Altintaş, B., Aydoğdu, D., İlsol, M., ... & Yarali, N. (2025). Critical complication in childhood leukemia: neutropenic enterocolitis, risk factors, and outcomes. Journal of pediatric hematology/oncology, 47 (6), e231-e234.

[9] Mehdi, I., & Bahrain, B. A. (2012). Chemotherapy-induced neutropenic necrotizing enterocolitis: a review. *JPMA-Journal of the Pakistan Medical Association*, *62* (7), 718.

[10] Nematolahi, S., Amanati, A., Vardanjani, H. M., Pourali, M., Bensenjan, M. H., Nozari, F., ... & Safari, F. (2025). Investigating neutropenic enterocolitis: a systematic review of case reports and clinical insights. BMC gastroenterology, 25 (1), 17.

[11] Nematolahi, S., Amanati, A., Vardanjani, H. M., Pourali, M., Bensenjan, M. H., Nozari, F., ... & Safari, F. (2025). Investigating neutropenic enterocolitis: a systematic review of case reports and clinical insights. BMC gastroenterology, 25 (1), 17.

[12] Zachariah, S. K. (2011). Adult necrotizing enterocolitis and non-occlusive mesenteric ischemia. Journal of Emergencies, Trauma and Shock, 4 (3), 430.

[13] Shaikh, N. (2007). Necrotizing fasciitis and diabetes mellitus. International Journal of Diabetes in Developing Countries, 27 (1), 14.

[14] Sharma, R., Tepas III, J. J., Hudak, M. L., Mollitt, D. L., Wludyka, P. S., Teng, R. J., & Premachandra, B. R. (2007). Neonatal gut barrier and multiple organ failure: role of endotoxin and proinflammatory cytokines in sepsis and necrotizing enterocolitis. Journal of Pediatric Surgery, 42 (3), 454-461.

[15] Cheng, N. C., Tai, H. C., Chang, S. C., Chang, C. H., & Lai, H. S. (2015). Necrotizing fasciitis in patients with diabetes mellitus: clinical characteristics and risk factors for mortality. BMC Infectious Diseases, 15 (1), 417.

[16] Kim, J. H., Sampath, V., & Canvasser, J. (2020). Challenges in diagnosing necrotizing enterocolitis. Pediatric Research, 88 (Suppl 1), 16-20.

[17] Matsuda, T., Okada, Y., Inagi, E., Tanabe, Y., Shimizu, Y., Nagashima, K., ... & Tanaka, S. (2007). Enteritis necroticans 'pigbel'in a Japanese diabetic adult. Pathology International, 57 (9), 622-626.

[18] YuZ, D. (2021). Clinical and pathogenetic features of intestinal lesions in patients with type 2 diabetes mellitus. Modern Gastroenterology, 5-6.

[19] Xu, J., Zhang, Q., Wang, Z., Liu, S., Zhu, S., Zhang, S., & Wu, S. (2025). Bidirectional Association of Type 2 diabetes mellitus and inflammatory bowel diseases: a large-scale prospective cohort study. Journal of Clinical Gastroenterology, 10-1097.

[20] Wang, Y. F., Li, J. W., Wang, D. P., Jin, K., Hui, J. J., & Xu, H. Y. (2023). Anti-hyperglycemic agents in the adjuvant treatment of sepsis: improving intestinal barrier function. Drug Design, Development and Therapy, 1697-1711.
[21] Zeng, R., Wang, J., Zhuo, Z., Luo, Y., Sha, W., & Chen, H. (2021). Stem cells and exosomes: promising candidates for necrotizing enterocolitis therapy. Stem Cell Research & Therapy, 12 (1), 323.
[22] McMurtry, V. E., Gupta, R. W., Tran, L., Blanchard, I. V., E. E., Penn, D., Taylor, C. M., & Ferris, M. J. (2015). Bacterial diversity and Clostridia abundance decrease with increasing severity of necrotizing enterocolitis: microbiome, 3 (1), 11.
[23] Altimimi, M. L. M., Ali, A. K., & Al-Salihi, A. A. J. (2024). Autism Assessment in Iraqi children with Nutritional Supplements for Developing Social and Communication Skills: Parents' Views on Health Behavior. American Journal of Health Behavior, 48(2), 483-494.
[24] Ismael, K. I., Al-Salihi, A. A. J., AL-Saadi, R. R., & Saeed, B. T. Isolation of Hemolysin-Producing Bacteria That Cause Infection in Patients with Urinary Tract Infections by Molecular Detection. Journal of Pharmaceutical Negative Results.2022, 13 (3), pp. 263–268.
[25] Alfalluji, W. L., Radhi, A. K., Al-Salihi, A. A. J. Evaluation of the clinical conditions of patients with therapeutic cardiac angiography and In-stent restenosis risk factors for in cancer patients. Onkologia i Radioterapia. 2023, 17 (10), pp. 1–6.