Natural Resources for Human Health
eISSN: 2583-1194

Original Research

Received 21 July 2026
Revised 25 Aug 2026
Accepted 10 Sep 2026

Natural Resources for Human Health 2026, Vol. 6 (22s): 241–249

KEYWORDS:
Multimodal imaging; scrotal mass; spermatocelectomy.

Giant Spermatocele Presenting as Longstanding Scrotal Enlargement: A Case Report

Syakir et al. Giant Spermatocele in an Adult

Muhammad Nur Faizi Syakir[1]*, Muhammad Asykar Palinrungi[2]

[1]Faculty of Medicine, Universitas Hasanuddin, Makassar Regional Hospital, Makassar, South Sulawesi, Indonesia.
[2]Department of Urology, Faculty of Medicine, Universitas Hasanuddin, Universitas Hasanuddin Hospital, Makassar, South Sulawesi, Indonesia.
***Correspondence:** Muhammad Nur Faizi Syakir, Faculty of Medicine, Universitas Hasanuddin, Makassar Regional Hospital, Makassar, South Sulawesi, Indonesia. Jl. Perintis Kemerdekaan No. KM. 14, Daya, Kecamatan Biringkanaya, Kota Makassar, Sulawesi Selatan 90243. E-mail: ajiesyakir02@gmail.com

ABSTRACT: This report describes a rare case of giant spermatocele in an adult man and shows how multimodal imaging and surgical management contributed to establishing the diagnosis and providing definitive treatment. A 55-year-old man was evaluated clinically and with scrotal ultrasonography and non-contrast multi-slice computed tomography (MSCT). He presented with progressive enlargement of the left hemiscrotum, intermittent dull pain, and discomfort during daily activities. Examination showed a large, nontender cystic mass with a positive transillumination test. Ultrasonography showed a large anechoic cystic lesion above the left testis, and computed tomography indicated a benign left extratesticular mass. At surgery, a well-defined cystic mass of approximately 9 × 7 × 5 cm arose from the left epididymal region; complete spermatocelectomy was performed with preservation of the testis and vas deferens. Histopathological examination of the excised specimen confirmed a spermatocele with sclerosing chronic inflammation. Recovery was smooth, with no postoperative complications; the patient was discharged after three days, and at one week the wound was dry and he reported no pain. Giant spermatocele is a rare benign condition of the scrotum and should be considered in the differential diagnosis of chronic scrotal enlargement. Careful clinical and radiological evaluation, followed by surgical excision with histopathological confirmation, led to a satisfactory outcome in this symptomatic patient.

1. INTRODUCTION

A spermatocele is a benign cystic lesion located outside the testis, arising from the head of the epididymis and containing cystic fluid and spermatozoa. Most spermatoceles are small and asymptomatic and are typically discovered incidentally during physical examination or scrotal ultrasonography [1]. According to the World Health Organization, most scrotal masses located outside the testis are benign, whereas intratesticular masses are more likely to be malignant. Accurate assessment of scrotal masses is important to enable appropriate management and to prevent unnecessary interventions [2].

Giant spermatoceles are uncommon, but their gradual enlargement may cause pain, discomfort, reduced mobility, and distortion of the normal scrotal anatomy, which in turn makes clinical assessment more difficult [3]. Advances in scrotal imaging, especially

high-resolution ultrasonography, have improved the ability to diagnose extratesticular cystic lesions and to distinguish them from other scrotal disorders [4]. Epidemiological data show that spermatoceles and other cystic lesions of the scrotum are more often found in men aged 40 years or older, underscoring their clinical importance [5].

The aim of this case report is to describe a giant spermatocele in an adult man with chronic scrotal discomfort and to examine the role of multimodal imaging and surgical management in establishing the definitive diagnosis and providing treatment.

2. CASE PRESENTATION

A 55-year-old man attended the surgical outpatient clinic complaining of gradual enlargement of the left hemiscrotum together with intermittent dull pain. Over the past year, the swelling had become increasingly troublesome, causing discomfort when walking and a sensation of a mass between the thighs. He said that the appearance resembled "three testicles". He had first noticed a slight enlargement of the scrotum at the age of 17 and had then observed it slowly increase over the following decades, especially after reaching adulthood. Believing the condition to be benign, he did not seek medical treatment. There was no history of injury to the scrotum or inguinal region, no infection, no urinary or bowel symptoms, and no sexual dysfunction. The patient is married and has three children; he reported feeling embarrassed by the obvious scrotal enlargement when dressing in trousers.

Blood pressure was 160/90 mmHg; all other vital signs and the general physical examination were within normal limits. On examination of the genital region, there was marked enlargement of the scrotum, with two soft masses in the left portion of the scrotum, one of which was especially large, and an additional, smaller mass in the right portion of the scrotum. There was no tenderness, normal bowel sounds were noted, and the transillumination test was positive.

Scrotal ultrasonography showed normal testes and a large, well-defined anechoic mass that extended beyond the area examined, lay above the left testis, and pushed it towards the base of the scrotum, in keeping with a giant spermatocele. The left epididymis could not be visualised, whereas the right epididymis was of normal size and echogenicity (Figure 1). Non-contrast multi-slice computed tomography (MSCT) of the scrotum showed that both testes were normal and demonstrated a predominantly heterogeneous cystic lesion with fatty density in the left scrotum; the spermatic cord was difficult to assess, and the surrounding soft tissues were unremarkable. The radiological conclusion was a benign left extratesticular mass (Figure 2).

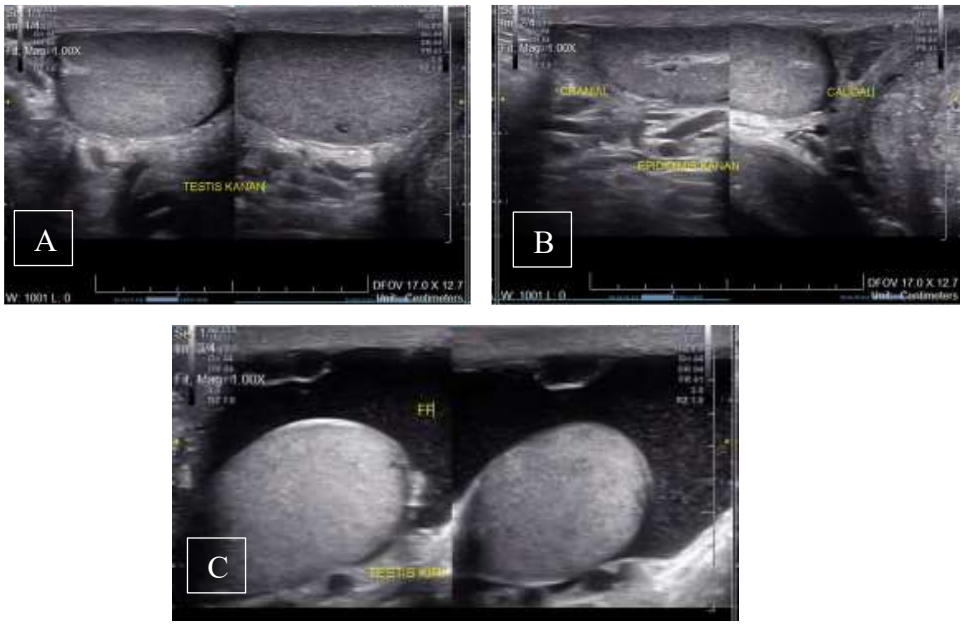

Figure 1. Scrotal ultrasonography demonstrating (A) normal right testis, (B) normal right epididymis, while the left epididymis was not visualised, and (C) left testis associated with a massive cystic fluid collection.

Natural Resources for Human Health
eISSN: 2583-1194

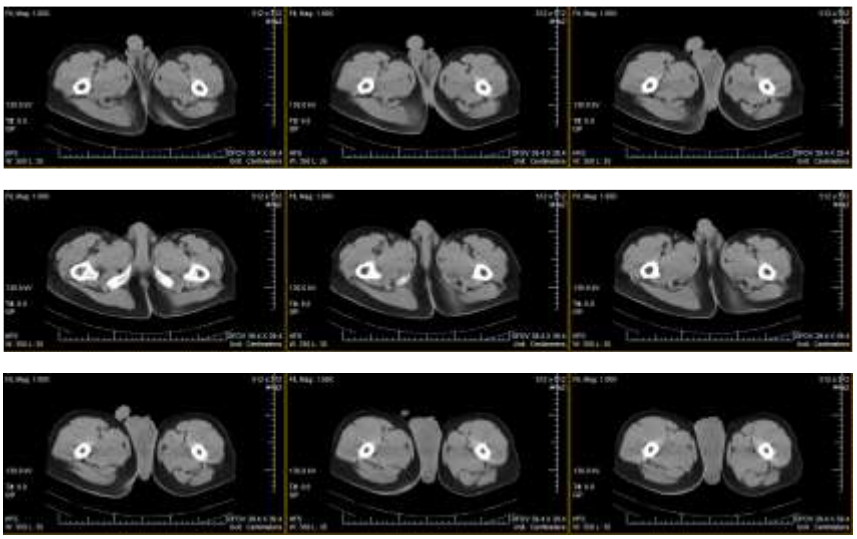

Figure 2. Non-contrast MSCT scan of the scrotum. MSCT, multi-slice computed tomography.

The patient was diagnosed with a benign neoplasm in the left scrotum, suspected to be a spermatocele, and with grade 2 hypertension. Before surgery, he was consulted by an internal medicine specialist. Intraoperative exploration revealed a well-defined cystic mass measuring approximately 9 × 7 × 5 cm arising in the left epididymal region; it was clearly separated from the opposite testis and adjacent spermatic structures. The mass had a distinct border and a smooth cyst wall, consistent with the preoperative diagnosis of a spermatocele. A complete spermatocelectomy was performed; while the cyst wall was being removed, it ruptured and turbid cystic fluid oozed out, and there were no clear signs of local invasion or malignancy. The lesion was removed completely, leaving the testis and vas deferens undamaged (Figure 3).

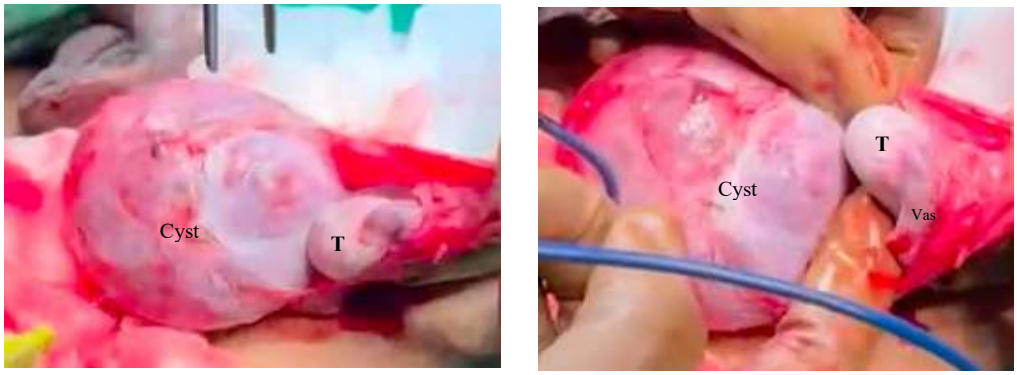

Figure 3. Intraoperative findings demonstrating the left testis (T), left vas deferens, and spermatocele.

Recovery after the operation was smooth, and the patient was discharged after three days in hospital. At the follow-up visit one week later, the surgical wound was dry and the patient reported no pain (Figure 4B; the preoperative appearance is shown in Figure 4A). Histopathological examination confirmed the diagnosis of spermatocele with associated sclerosing chronic inflammation (Figure 5).

Natural Resources for Human Health
eISSN: 2583-1194



Figure 4. Clinical appearance of the scrotum showing (A) preoperative left scrotal enlargement and (B) postoperative findings at day 7 after surgery.

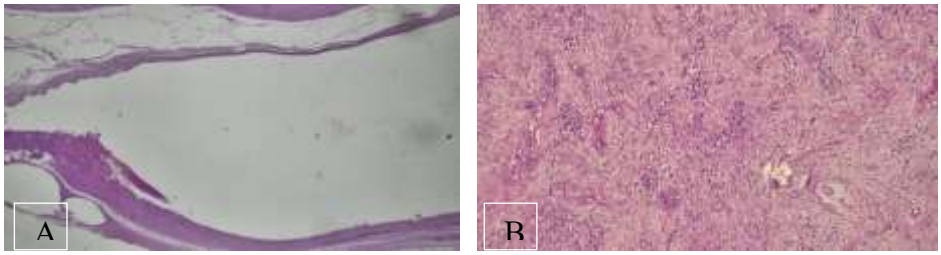

Figure 5. Histopathological examination showing (A) a cystic lesion with a thin cystic wall consisting of connective tissue and (B) a solid fibrosclerotic area with chronic inflammatory cell infiltration composed predominantly of lymphocytes and plasma cells, accompanied by reactive spindle-shaped fibroblastic cells.

3. DISCUSSION

A spermatocele is a benign cystic lesion that mostly forms in the head of the epididymis. Microscopically, it consists of a thin-walled cyst whose inner surface is lined by cuboidal or columnar epithelium and which contains fluid composed of spermatozoa, cellular debris and proteinaceous material. The head of the epididymis is the most common site of a spermatocele because it is where sperm mature and are temporarily stored. Fluid may accumulate if sperm drainage is impaired or the epididymal ducts are blocked, leading to ductal dilation and ultimately cyst formation [2].

Epidemiological studies show that spermatoceles mostly affect middle-aged and older men, with the frequency rising after the age of 50 and among men with other medical conditions such as diabetes. Although most cases are asymptomatic and are found by chance, spermatoceles are often identified when men are evaluated for scrotal swelling or male infertility, which suggests a link with reproductive health. Regional differences in diagnosis and hospitalisation rates have also been noted, with higher numbers of cases in the Southeast, Northeast, and South regions of Brazil, whereas cases in children remain fairly rare [5–7]. However, the exact global incidence remains unknown, as most available data come from retrospective hospital-based studies rather than prospective population-wide studies [6].

The lesion is thought to develop primarily through obstruction of the epididymal ducts, leading to progressive cystic dilatation of the efferent ductules or rete testis, often secondary to congenital abnormalities or acquired obstruction within the epididymal ducts, with subsequent fluid accumulation. Inflammatory mechanisms may also contribute to cyst formation, as elevated levels of inflammatory mediators (including IL-6, IL-8, and tumour necrosis factors) have been identified within cyst fluid [8]. Degenerated spermatozoa and immunological activity within the cyst contents further support the possibility that inflammatory and obstructive mechanisms jointly contribute to cyst formation and progression [5,8]. The relative contribution of congenital predisposition versus acquired inflammatory processes has not yet been fully clarified, leaving several aspects of spermatocele pathogenesis insufficiently understood [6,8].

The persistent accumulation of fluid in the cyst leads to a gradual increase in its size. Small lesions, especially those under 1 cm and not causing pain, are often ignored, delaying diagnosis until the cyst has grown large enough to cause discomfort during

everyday activities such as walking or crossing the legs [1,9,10]. Giant spermatoceles are rare; the number of cases described in the English-language literature is very small, as shown by searches in PubMed. These lesions can appear as either unilocular or multilocular cysts, and in almost all instances the cause is idiopathic [9].

Spermatoceles are generally asymptomatic and are often discovered by chance during a physical examination or when scrotal ultrasonography is performed for another reason. When they cause symptoms, patients may experience scrotal swelling, discomfort, a persistent dull rather than sharp pain that is aggravated by prolonged standing, walking long distances, or intense physical activity, a feeling of heaviness, or concern about appearance. In larger or multilocular lesions, the clinical and radiological features may resemble those of a hydrocele, making the diagnosis more difficult. Symptom severity is usually correlated with cyst size and complexity, and younger patients more commonly report pain [3,11,12]. Rare types such as giant, bilateral, or multilocular spermatoceles can cause considerable scrotal enlargement and functional discomfort [13,14]. Rare complications, such as spermatocele torsion presenting as acute scrotal pain and extrascrotal lesions causing referred lower abdominal pain, should still be included in the differential diagnosis when the presentation is atypical [1,15,16].

The pain caused by a spermatocele is usually not serious and seldom leads to systemic symptoms such as fever, chills, or general discomfort; this distinguishes it from infectious conditions such as epididymitis and orchitis. Although spermatoceles typically do not cause symptoms, they can cause discomfort, a dull ache, or a feeling of heaviness in the scrotum when the cyst grows and compresses surrounding structures. The absence of significant disturbances in bowel movements or urination, together with the absence of signs of urinary tract obstruction, also indicates that the patient's symptoms were not due to an inflammatory process or an acute infection [17].

On examination, spermatoceles usually present as well-defined cystic masses located outside the testis, with a smooth surface and a soft to fluctuant consistency. They are generally situated above or behind the testis, which remains a separate structure that is neither enlarged nor tender. The scrotal skin is usually normal in appearance, without signs of inflammation (e.g., redness or increased local temperature), and the transillumination test is usually positive. Nevertheless, the cystic fluid is relatively more turbid than hydrocele fluid [2,3]. In this case, a large non-inflammatory mass was found in the upper and posterior part of the left hemiscrotum, a finding consistent with the typical clinical appearance of a spermatocele and therefore supporting the diagnosis of a benign lesion [18].

The differential diagnosis of large scrotal masses includes hydrocele, inguinoscrotal hernia, varicocele, epididymal cyst, inflammatory disease, and both benign and malignant paratesticular tumours (Table 1) [18]. In giant lesions such as this one, overlapping clinical and radiological features may complicate diagnosis. Large spermatoceles may mimic a hydrocele or a neoplasm because progressive enlargement obscures the origin of the lesion and distorts normal scrotal anatomy [4]. Careful integration of physical examination and multimodal imaging is therefore important to establish an accurate diagnosis and to avoid unnecessary radical intervention [19].

Table 1. Comparison of differential diagnosis of scrotal masses

Diagnosis	Pathomechanism	Clinical Manifestation	Physical Examination	Laboratory Findings	Ultrasound sign
Spermatocele [18,22]	Formation of a cyst due to obstruction of the epididymal duct or retention of sperm	Often asymptomatic; may present as scrotal swelling or discomfort	Cystic, non-tender mass above the testis	No specific lab findings	Anechoic cystic lesion with posterior acoustic enhancement; "falling snow" sign on Doppler ultrasound
Hydrocele [10,18]	Accumulation of serous fluid in the tunica vaginalis due to imbalance in fluid production and absorption	Painless unilateral scrotal swelling, may be bilateral. May increase in size over time. Often producing diffuse enlargement with less distinct testicular borders	Transillumination test positive; smooth, soft, non-tender mass	No specific lab findings	Anechoic fluid collection surrounding the testis; may show a thin wall on ultrasound

Diagnosis	Pathomechanism	Clinical Manifestation	Physical Examination	Laboratory Findings	Ultrasound sign
Epididymitis [18,19]	Inflammation of the epididymis, often due to bacterial infection, leading to swelling and pain	Acute unilateral scrotal pain; recurrent mild pain. Swelling, tenderness; erythema, urinary symptoms, or systemic manifestations such as fever and malaise	Tenderness in the epididymis, often with a palpable mass (palpable epididymal thickening)	Elevated white blood cell count; may show signs of infection	Enlarged epididymis with increased blood flow on Doppler; may show reactive hydrocele
Varicocele [1,18,31]	Increased venous pressure leading to dilation of the pampiniform plexus, often due to valve incompetence	Scrotal discomfort or infertility-related concerns. May be asymptomatic; dull ache, heaviness in the scrotum, warmth, swelling, or groin pain, especially during prolonged standing or erection	Dilated pampiniform veins with a "Bag of worms" appearance superior to the testis; may be more prominent when standing	May show elevated testosterone levels; no specific lab finding	Dilated veins in the pampiniform plexus; increased venous flow on Doppler
Orchitis [18,24]	Inflammation of the testis, often due to viral or bacterial infection, leading to pain and swelling	Scrotal pain, swelling, fever, erythema and possible urinary symptoms	Tender, swollen testis; may have associated epididymitis	Elevated white blood cell count; may show signs of infection	Enlarged, hypoechoic testis with increased blood flow on Doppler; may show reactive hydrocele
Testicular Neoplasm [4,14,18]	Abnormal proliferation of testicular cells leading to tumor formation, can be germ cell or non-germ cell origin	Painless solid intratesticular mass; may have associated symptoms of metastasis. Aged 15–35 years	Firm, irregular mass; may be fixed to surrounding tissues. Scrotal heaviness, fluid accumulation, or metastatic manifestations such as back pain, abdominal pain, hemoptysis, supraclavicular lymphadenopathy, and gynecomastia	Tumor markers (e.g., AFP, hCG) may be elevated	Solid mass with variable echogenicity; may have increased vascularity on Doppler
Inguinoscrotal Hernia [2,18]	Protrusion of abdominal contents through a weakness in the inguinal canal, often due to congenital defects or increased intra-abdominal pressure	Swelling in the groin or scrotum; may cause discomfort	Reducible mass in the inguinal canal; may be tender	No specific lab findings	Presence of bowel or omentum in the scrotum; may show peristalsis on ultrasound

AFP, alpha-fetoprotein; hCG, human chorionic gonadotropin. Numbers in square brackets refer to the reference list.

Scrotal ultrasonography was performed as the initial imaging modality because it remains the preferred investigation for cystic scrotal lesions and, with Doppler examination, reliably differentiates intratesticular from extratesticular pathology and assesses vascularity [20,21]. Typical ultrasonographic findings of spermatocele include a well-defined cystic lesion arising from the epididymal region with low-level internal echoes or the characteristic "falling snow" appearance caused by mobile particulate material within the cyst fluid, a finding thought to reflect acoustic streaming and the internal composition of spermatocele contents [22,23].

In this case, ultrasonography demonstrated a massive anechoic cystic lesion displacing the left testis inferiorly. However, several limitations became apparent during the examination. The lesion exceeded the sonographic field, the left epididymis could not be clearly identified, and the exact relationship between the mass, the spermatic cord, and the surrounding structures remained unclear. As a result, the site of origin could not be confidently established on ultrasonography alone [18,21]. This uncertainty has important clinical implications. Although the lesion was primarily cystic, its unusually large size and long duration of growth meant that a paratesticular neoplasm could not be ruled out on the basis of ultrasonography alone, so further anatomical clarification was needed before surgery could be carried out.

Computed tomography (CT) is usually not required when evaluating a spermatocele; however, in rare or difficult cases it may be useful to exclude malignancy and to differentiate a spermatocele from other scrotal tumours [24]. MSCT was therefore carried out to define the extent of the lesion more clearly and to assess its relationship with the adjacent scrotal structures. The scan showed a well-demarcated extratesticular cystic mass with benign imaging features and no evidence of invasive soft-tissue growth. It also clearly demonstrated displacement of the testis and confirmed the absence of an intratesticular component, findings that reduced the suspicion of malignancy and aided surgical planning [1]. Ultrasonography remains the first-choice imaging method for spermatocele because it is non-invasive, easily accessible, and highly accurate diagnostically, whereas MSCT is mainly used as a supplementary investigation for giant, complex, or anatomically distorted lesions when an ultrasound examination cannot be performed [22,25].

The diagnosis of giant spermatocele in this case was based on a slowly developing unilateral cystic mass of the scrotum, the absence of signs of systemic inflammation or malignancy, ultrasonography showing a large cystic lesion outside the testis, and MSCT findings consistent with a benign condition. It was confirmed by histopathological examination, which showed a spermatocele with associated sclerosing chronic inflammation. Since the lesion had caused continuous discomfort and interfered with daily activities, spermatocelectomy was considered a reasonable definitive treatment. Surgical excision remains the most suitable method of treating symptomatic spermatoceles and generally gives satisfactory results with a low recurrence rate, provided that the entire lesion is removed and the surrounding testicular tissue is preserved as far as possible [10].

Spermatocelectomy remains the standard method of treating symptomatic spermatoceles. In some cases, performing an epididymectomy at the same time may further decrease the likelihood of recurrence by eliminating the link between the spermatocele and the epididymal ducts [26]. This approach, however, requires careful consideration because of the potential risk of epididymal obstruction and subsequent impairment of fertility. Fertility preservation therefore remains an important component of preoperative counselling, particularly in patients who desire future conception [27]. Less invasive approaches, such as aspiration followed by sclerotherapy with doxycycline or alcohol, have also been used successfully, with reported success rates of over 70% and generally uncommon complications [28,29]. These procedures could be used in selected patients who prefer non-surgical treatment or are not suitable candidates for surgery, although long-term outcome data remain limited [29].

The outcome after surgery is generally satisfactory, but recurrence is frequently observed after spermatocelectomy performed without simultaneous epididymectomy, in which case further aspiration or another operation may be required [26]. Management should therefore be tailored to the individual patient, with due consideration of preventing recurrence, preserving fertility, and the possible adverse effects of more extensive surgery. It is also important to be aware of rare but clinically significant complications such as spermatocele torsion and the difficulty of distinguishing it from a hydrocele, to prevent delayed diagnosis or inappropriate treatment [15,30]. Improved access to ultrasonography and to minimally invasive treatment methods may likewise facilitate early diagnosis and more effective management, especially in areas where the rate of hospitalisation due to spermatoceles is rising [28,30]. In this patient, who also had grade 2 hypertension, careful perioperative blood pressure control is essential to reduce the risk of cardiovascular complications during and after surgery. This report has the limitations inherent

to a single case. In addition, postoperative follow-up was limited to one week, so long-term outcomes, including recurrence, could not be assessed.

4. CONCLUSION

This case illustrates the diagnostic difficulties associated with giant spermatocele, a rare cause of chronic scrotal enlargement external to the testes. Careful integration of clinical findings with multiple imaging modalities, particularly high-resolution ultrasonography and additional imaging when indicated, allows accurate differentiation from other scrotal disorders, with diagnosis confirmed by histopathological examination. Giant spermatocele should be considered in the differential diagnosis of longstanding scrotal masses, and surgical excision is an appropriate treatment for symptomatic cases, as in this patient.

ACKNOWLEDGEMENTS

Not applicable.

AUTHOR CONTRIBUTIONS

MNS: Conceptualization, Investigation, Writing—Original Draft, Writing—Review & Editing.

MAP: Conceptualization, Investigation, Writing—Review & Editing, Supervision.

All authors read and approved the final manuscript and agree to be accountable for all aspects of the work.

CONFLICT OF INTEREST

The authors declare that there is no conflict of interest.

ETHICS STATEMENT

The work described in this report was conducted in accordance with institutional policies and the ethical principles of the Declaration of Helsinki. Ethical review was waived by the Faculty of Medicine, Universitas Hasanuddin, Makassar, Indonesia. Written informed consent for publication of clinical details and images was obtained from the patient, and a copy of the written consent is available for review by the Editor-in-Chief of this journal on request. All patient data were anonymised prior to publication.

DATA AVAILABILITY STATEMENT

The datasets used and/or analysed during the current study are available from the corresponding author on reasonable request.

FUNDING

No specific funding was received for this study.

REFERENCES

[1] Gebreselassie, K.H., Berhanu, E., Akkasa, S.S., et al., 2022. *Torsed spermatocele, a rare cause of acute scrotum: report of a case and review of literature*. Urol Case Rep 45.

[2] WHO Classification of Tumours Editorial Board, 2022. *Urinary and male genital tumours*. WHO Classification of Tumours. International Agency for Research on Cancer, p. 244–98.

[3] Walsh, T.J., Seeger, K.T., Turek, P.J., 2007. *Spermatoceles in adults: when does size matter?* Arch Androl 53, 345–348.

[4] Bertolotto, M., Valentino, M., Iannelli, M., et al., 2017. *The testicles: cystic lesions*. Atlas Ultrason Urol Androl Nephrol, 471–482.

[5] Romero, F.R., Romero, A.W., de Almeida, R.M.S.S.A., et al., 2014. *Prevalence and risk factors for scrotal lesions/anomalies in a cohort of Brazilian men ≥40 years of age*. Sao Paulo Med J 132, 73–79.

[6] Lundström, K.J., Söderström, L., Jernow, H., et al., 2019. *Epidemiology of hydrocele and spermatocele; incidence, treatment and complications*. Scand J Urol 53, 134–138.

[7] RS S, PK M, SS P. *Spermatocele infrequent cause of scrotal swelling in children*. Int J Collab Res Intern Med Public Heal 8.

[8] Koçak, I., Dündar, M., Yenisey, Ç., et al., 2002. *Pro-inflammatory cytokine response of the fluid contents of spermatoceles and epididymal cysts*. Andrologia 34, 112–115.

[9] Salama, N., Hassan, O.S., 2022. *A post-aspiration giant spermatocele in a young man: a case report and literature review*. Clin Med Insights Case Rep 15, 11795476221097218.
[10] Yeh, H.C., Wang, C.J., Liu, C.C., et al., 2007. *Giant spermatocele mimicking hydrocele: a case report*. Kaohsiung J Med Sci 23, 366–369.
[11] Mohammed, M., 2021. *Spermatocele mimicking hydrocele: a case report in a young patient of 42 years old*. Int J Curr Sci Res Rev 04.
[12] Hirano, D., Yoshioka, H., Irie, Y., et al., 2022. *Huge multilocular spermatocele in a patient with left scrotal swelling*. J Case Rep Images Urol 7, 1–4.
[13] Dollard, D.J., Fobia, J.B., 2011. *Extra scrotal spermatocele causing lower abdominal pain: a first case report*. Am J Emerg Med 29, 358.e7–358.e9.
[14] Huri, E., Akgül, T., Ayyıldız, A., et al., 2009. *Bilateral giant spermatocele mimicking an intrascrotal mass*. Turk J Urol 35, 151–152.
[15] Takimoto, K., Okamoto, K., Wakabayashi, Y., et al., 2002. *Torsion of spermatocele: a rare manifestation*. Urol Int 69, 164–165.
[16] Ameli, M., Parsapour, A., Gholami-Mahtaj, L., et al., 2016. *A 40-year-old man with testicular torsion and large bilateral spermatoceles*. Qatar Med J 2016, 10.
[17] Chairul, A.M., Palinrungi, M.A., Faruk, M., 2023. *Encysted hydrocele of spermatic cord: a rare case report with review of literature*. Int J Surg Case Rep 107, 108374.
[18] Sosnowska-Sienkiewicz, P., Januszkiewicz-Lewandowska, D., Mańkowski, P., 2023. *Testicular and scrotal abnormalities in pediatric and adult patients*. Pol Przegl Chir 96, 88–96.
[19] Mukherjee, S., Maheshwari, V., Khan, R., et al., 2013. *Clinico-radiological and pathological evaluation of extra testicular scrotal lesions*. J Cytol 30, 27–32.
[20] Nashan, D., Behre, H.M., Grunert, J.H., et al., 1990. *Diagnostic value of scrotal sonography in infertile men: report on 658 cases*. Andrologia 22, 387–395.
[21] Sista, A.K., Filly, R.A., 2008. *Color Doppler sonography in evaluation of spermatoceles: the "falling snow" sign*. J Ultrasound Med 27, 141–143.
[22] Patil, V., Shetty, S.M.C., Das, S., 2015. *Common and uncommon presentation of fluid within the scrotal spaces*. Ultrasound Int Open 1, E34–40.
[23] Chen, F., Cernigliaro, J., Desai, M., et al., 2019. *The "falling snow" sign*. Abdom Radiol 45, 587–588.
[24] Jain, B., Gaddi, M., Nallathambi, N., et al., 2024. *Advanced sonographic techniques in the comprehensive evaluation and diagnosis of male infertility*. Cureus 16.
[25] Holden, A., List, A., 1994. *Extratesticular lesions: a radiological and pathological correlation*. Australas Radiol 38, 99–105.
[26] Honig, S.C., Cahill, E.M., Choksi, A.U., et al., 2025. *Spermatocelectomy with and without epididymectomy: retrospective experience at a single institution in patients not interested in fertility preservation*. Can J Urol 32, 521–527.
[27] Kliesch, S., 2014. *Hydrozele, Spermatozele und Vasektomie*. Urologe A 53, 671–675.
[28] Brockman, S., Roadman, D., Bajic, P., et al., 2022. *Aspiration and sclerotherapy: a minimally invasive treatment for hydroceles and spermatoceles*. Urology 164, 273–277.
[29] Low, L.S., Nair, S.M., Davies, A.J.W., et al., 2020. *Aspiration and sclerotherapy of hydroceles and spermatoceles/epididymal cysts with 100% alcohol*. ANZ J Surg 90, 57–61.
[30] Keller, A.K., Howard, M.M., Jensen, J.B., 2021. *Complications after scrotal surgery – still a major issue?* Scand J Urol 55, 404–407.